

AND
FOR

TERMINOLOGY GUIDELINES GLAUCOMA



EUROPEAN GLAUCOMA SOCIETY

www.eugs.org

4th Edition

ISBN 978-88-98320-05-9



PubliComm

Piazza Guido Rossa 8r
17100 Savona - Italy
www.publicomm.it

SvetPrint d.o.o.
Printed in EU
June 2014

Copyright © 2014 European Glaucoma Society

No parts of this text, illustrations, tables or flowcharts can be reproduced, copied, translated or stored by any means including magnetic, electronic or multimedia formats without written permission of the European Glaucoma Society.

AND
FOR

TERMINOLOGY GUIDELINES GLAUCOMA

4th Edition



EUROPEAN GLAUCOMA SOCIETY

www.eugs.org

Contents

	Page
FOREWORD	6
INTRODUCTION CHAPTER	11
GLOSSARY	27
CHAPTER 1 - PATIENT EXAMINATION	31
1.1 Intraocular pressure (iop) and tonometry	33
1.2 Gonioscopy	39
1.3 Optic nerve head and retinal nerve fibre layer	48
1.4 Perimetry	58
CHAPTER 2 - CLASSIFICATION AND TERMINOLOGY	73
2.1 Primary congenital forms/childhood glaucomas	75
2.2 Primary open-angle glaucomas	79
2.3 Secondary Glaucomas	90
2.4 Primary Angle-Closure	100
2.5 Secondary Angle-Closure	114
CHAPTER 3 - TREATMENT PRINCIPLES AND OPTIONS	129
3.1 General Principles of Glaucoma Treatment	131
3.2 Target IOP and Quality of Life	134
3.3 Antiglaucoma Drugs	139
3.4 Adherence, Compliance and Persistence in Glaucoma	159
3.5 Laser Surgery	161
3.6 Incisional Surgery	169
3.7 Cataract and Glaucoma Surgery	176
INDEX	192

Foreword

It gives me pleasure to introduce the 4th edition of the EGS Guidelines. The Third edition proved to be extremely successful, being translated into 7 languages with over 70000 copies being distributed across Europe; it has been downloadable, free, as a pdf file for the past 4 years. As one of the main objectives of the European Glaucoma Society has been to both educate and standardize glaucoma practice within the EU, these guidelines were structured so as to play their part.

Glaucoma is a living specialty, with new ideas on causation, mechanisms and treatments constantly appearing. As a number of years have passed since the publication of the last edition, changes in some if not all of these ideas would be expected.

For this new edition of the guidelines a number of editorial teams were created, each with responsibility for an area within the specialty; updating where necessary, introducing new diagrams and Flowcharts and ensuring that references were up to date. Each team had writers previously involved with the last edition as well as newer and younger members being co-opted.

As soon as specific sections were completed they had further editorial comment to ensure cross referencing and style continuity with other sections.

Overall guidance was the responsibility of Anders Heijl and Carlo Traverso. Tribute must be made to the Task Force whose efforts made the timely publication of the new edition possible.

Roger Hitchings
Chairman of the EGS Foundation

**The Guidelines Writers
and Contributors**

Augusto Azuara Blanco
Luca Bagnasco
Alessandro Bagnis
Keith Barton
Christoph Baudouin
Boel Bengtsson
Alain Bron
Francesca Cordeiro
Barbara Cvenkel
Philippe Denis
Christoph Faschinger
Panayiota Founti
Stefano Gandolfi
David Garway Heath
Francisco Goñi
Franz Grehn
Anders Heijl (*Editor*)
Roger Hitchings
Gábor Holló
Tony Hommer
Michele Iester
Jost Jonas
Yves Lachkar
Giorgio Marchini
Frances Meier Gibbons
Stefano Miglior
Marta Misiuk-Hojto
Maria Musolino
Jean Philippe Nordmann
Norbert Pfeiffer
Luis Abegao Pinto
Luca Rossetti
John Salmon
Leo Schmetterer
Riccardo Scotto
Tarek Shaarawy
Ingeborg Stalmans
Gordana Sunaric Mégevand
Ernst Tamm
John Thygesen
Fotis Topouzis
Carlo Enrico Traverso (*Editor*)
Anja Tuulonen
Ananth Viswanathan
Thierry Zeyen

**The Guidelines
Task Force**

Luca Bagnasco
Anders Heijl
Carlo Enrico Traverso

Augusto Azuara Blanco
Alessandro Bagnis
David Garway Heath
Michele Iester
Yves Lachkar
Ingeborg Stalmans
Gordana Sunaric Mégevand
Fotis Topouzis
Anja Tuulonen
Ananth Viswanathan

**The EGS Executive
Committee**

Carlo Enrico Traverso
(*President*)
Anja Tuulonen
(*Vice President*)
Roger Hitchings
(*Past President*)
Anton Hommer
(*Treasurer*)
Barbara Cvenkel
Julian Garcia Feijoo
David Garway Heath
Norbert Pfeiffer
Ingeborg Stalmans

**The Board of the European
Glaucoma Society Foundation**

Roger Hitchings (*Chair*)
Carlo E. Traverso (*Vice Chair*)
Franz Grehn
Anders Heijl
John Thygesen
Fotis Topouzis
Thierry Zeyen

**The EGS
Committees**

CME and Certification
Gordana Sunaric Mégevand
(*Chair*)
Carlo Enrico Traverso
(*Co-chair*)

Delivery of Care
Anton Hommer (*Chair*)

EU Action
Thierry Zeyen (*Chair*)
Carlo E. Traverso (*Co-chair*)

Education
John Thygesen (*Chair*)
Fotis Topouzis (*Co-chair*)

Glaucomene
Ananth Viswanathan (*Chair*)
Fotis Topouzis (*Co-chair*)

Industry Liaison
Roger Hitchings (*Chair*)

Information Technology
Ingeborg Stalmans (*Chair*)
Carlo E. Traverso (*Co-chair*)

National Society Liaison
Anders Heijl (*Chair*)

Program Planning
Fotis Topouzis (*Chair*)
Ingeborg Stalmans (*Co-chair*)

Quality and Outcomes
Anja Tuulonen (*Chair*)
Augusto Azuara Blanco
(*Co-chair*)

Scientific
Franz Grehn (*Chair*)
David Garway Heath
(*Co-chair*)

For Conflict of interest/Financial disclosure please see www.eugs.org/pdf/FinancialDisclosure.pdf

A stylized map of Florida is centered on the page, rendered in a light gray color with a fine dotted pattern. The map is partially overlaid by a large, semi-transparent white circle. To the left of the text, there is a solid yellow square. The background of the page is a light gray with a subtle, larger-scale dotted pattern.

Introduction Chapter

Introduction Chapter

The aim of these Guidelines is to present the view of the European Glaucoma Society (EGS) on the diagnosis and management of glaucoma. Our Guidelines are intended to support ophthalmologists in managing patients affected by, or suspected of having, glaucoma. The Guidelines should be considered as recommendations rather than as strict treatment protocols.

In the last edition, a simplified grading system for rating the strength of recommendation and the quality of evidence was introduced and has been retained in the present edition. The **strength of recommendation** is graded as either **I** (strong) or **II** (weak). A strong recommendation (I) is to be interpreted as “we recommend” and/or “very relevant in clinical practice” and a weak recommendation (II) as “we suggest” and/or “less relevant in clinical practice”.

The **quality of evidence** is classified as high (**A**), moderate (**B**), low (**C**) or very low (**D**). As an example, high quality evidence would be supported by high quality randomised clinical trials (RCTs). Observational studies would be typically graded as low-quality evidence. Consensus from our Panel would be graded as (D).

Clinical care must be individualised to the patient, the treating ophthalmologist and the socioeconomic milieu. The availability of Randomized Controlled Trials (RCTs) makes it possible to apply scientific evidence to clinical recommendations. Irrespective of the relative wealth of each European region, economical factors must be considered by physicians, in order to provide sustainable healthcare.

The EGS and all contributors disclaim responsibility and all liability for any adverse medical or legal effects resulting directly or indirectly from the use of any of the definitions, diagnostic techniques or treatments described in the Guidelines. The EGS does not endorse any product, procedure, company or organisation.

I.1 Terminology, Classification and Definitions

Classification and disease definitions are arbitrary, and a consensus can be reached only if they are acceptable to most ophthalmologists on both theoretical and practical grounds. There are conditions where a precise classification is particularly challenging, such as in congenital forms associated with other anomalies.

The following factors are to be considered in order to identify and separate the different glaucoma categories.

1. Anatomy / Structure (See Ch. 1)
Open-angle, closed-angle, optic nerve head, etc.
e.g. clinical signs, exfoliation, pigment dispersion
2. Function (See Ch. 1)
e.g. visual field
3. Intraocular pressure (IOP) level (See Ch. 1)
 - 3.1. At which diagnosis is made (See Ch. 2)
 - 3.2. At which damage occurred (See Ch. 1)
 - 3.3. Target IOP (See Ch. 3.2)¹²
 - 3.4. General conditions: life expectancy, comorbidities

MISSION STATEMENT

The goal of glaucoma treatment is to maintain the patient's visual function and related quality of life, at a sustainable cost. The cost of treatment in terms of inconvenience and side effects as well as financial implications for the individual and society requires careful evaluation (See Ch. 3). Quality of life is closely linked with visual function and, overall, patients with early to moderate glaucoma damage have good visual function and modest reduction in quality of life, while quality of life is considerably reduced if both eyes have advanced visual function loss.

I.2 Treatment Principles

- A.** Treatment Goals (See Ch. 3.1)
 - A.1. Quality of life
 - A.2. Quality of vision
 - A.3. Cost containment
- B.** Suggested ways of reaching the goal (see Ch. 3 and 4)
 - B.1.** Selection of patients to be treated
 - B.1.1.** Identification of patients with disease
 - B.1.2.** Identification of patients at risk of developing the disease [I,D]
 - B.1.2.1.** Identification of the clinical entity, possibly using a systematic classification (See Ch. 2)
 - B.1.2.2.** Consideration of mixed mechanisms
 - B.1.3.** Treatment of the above when actual or expected rate of decay risks interfering with quality of life [I,C]
 - B.2.** Decreasing the risk of ganglion cell loss since it reduces visual function
 - Determine the target IOP for the individual [I,D]. In general, when there is more advanced damage, lower IOPs are needed to prevent further progression [I,D]
 - IOP lowering [I,A]
 - Drugs
 - Laser
 - Surgery
 - Verify the target IOP (See Ch.3.2)
 - Monitor the Rate of Progression (Field and Disc) [I,D]
 - Adjust management according to ROP
 - Blood flow (see Ch. 1 and Ch. 3) or neuroprotection (See Ch. 3.); both under debate [II,D]
 - Consider always compliance, persistence and assiduity of follow-up
 - B.3.** Incorporation of a quality of life measure in the outcome of treatment
- C.** Audit outcomes e.g. efficacy, safety, cost [I,D] (See Ch. Introduction III)
 - C.1.** Failures include patients suffering from the consequences of insufficient IOP lowering,

Since resources are limited worldwide, the following points are relevant to glaucoma treatment guidelines:

- prevention of visual disability in those at risk of decreased quality of life;
- avoid widespread treatment of elevated IOP per se;
- enforce effective treatment/follow-up in patients with severe functional loss and/or rapid progression;
- implement strategies to detect all patients with manifest disease.

These points are supported by the results of Randomized Clinical Trials for glaucoma (See Chapter Introduction II).

FC I – Suggested Questions for Your Glaucoma Patient



AT BASELINE

HISTORY/RISK FACTORS

SPECIFICALLY ENQUIRE ABOUT

- ALL MEDICATIONS
- FAMILY HISTORY (GENERAL/OPHTHALMOLOGICAL)
- CORTICOSTEROID THERAPY (TOPICAL/SYSTEMIC)
- OCULAR TRAUMA (CONTUSION)
- REFRACTIVE SURGERY
- CARDIOVASCULAR OR RESPIRATORY DISEASES/OTHER CHRONIC OR SEVERE DISEASES
- VASCULAR DISORDERS
- DRUGS ALLERGY

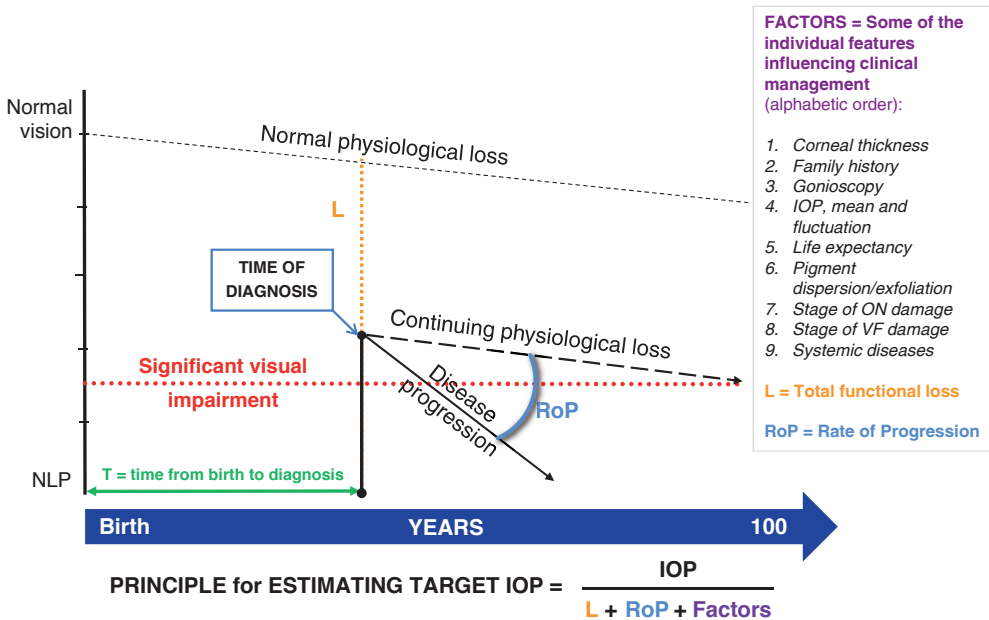


DIRECT QUESTIONS AT FOLLOW-UP

- HOW ARE YOU?
- HOW DO YOU THINK YOUR EYES ARE DOING?
- DO YOU THINK YOUR CONDITION IS BETTER, STABLE OR WORSE?
- DO YOU HAVE DIFFICULTY WITH YOUR DAILY TASKS?
- DO YOU UNDERSTAND YOUR DIAGNOSIS?
- ARE THE GLAUCOMA MEDICATIONS INTERFERING WITH YOUR DAILY ACTIVITIES?
- ARE YOU WORRIED ABOUT YOUR EYES?
- HAVE YOU BEEN USING YOUR EYE DROPS AS PRESCRIBED?
- DO YOU ADMINISTER THE DROPS BY YOURSELF OR BY A RELATIVE?
- IF BY YOURSELF, PLEASE SHOW ME HOW YOU DO IT

PLEASE SHAKE HANDS WITH PATIENTS. BESIDES BEING KIND AND ENCOURAGING, YOU WILL FEEL THE TEMPERATURE OF THEIR PERIPHERAL SKIN.

Evaluation of Functional Loss / Time for Individualized Treatment



© European Glaucoma Society 2014

Figure 1. Evaluation of functional loss/time for individualised treatment

IOP = the IOP level causing damage

L = the difference of visual function between the age-matched normal and the function at the time of diagnosis

RoP = angle between physiological loss and disease progression, representing progression rate

T = time interval between birth and the time of diagnosis

FACTORS = some of the individual features influencing clinical management (in alphabetical order):

1. Corneal thickness;
2. Family history;
3. Gonioscopy;
4. IOP, mean and fluctuation;
5. Life expectancy;
6. Pigment dispersion/exfoliation;
7. Rate of Progression (RoP);
8. Stage of optic nerve head (ONH) damage;
9. Stage of VF damage;
10. Systemic diseases

The EGS guidelines are to be adapted to individual patients, socioeconomic environment, medical facilities, skills of the average ophthalmologist and health professional, and to available resources

II - RANDOMIZED CONTROLLED TRIALS FOR GLAUCOMA

In the following pages we briefly summarize results from the large randomized glaucoma trials (RCTs, and derive comments relevant to clinical decision-making).

II.1 Treatment Vs No Treatment Trials

II.1.1 Collaborative Normal Tension Glaucoma Study (CNTGS)

CNTGS compared treatment versus no treatment in normal tension glaucoma. Eligible patients had verified progression or threat to fixation. The primary outcome measure was disease progression as evident from visual fields or stereo disk photographs.

140 patients were randomized. The treatment goal was a 30% reduction from baseline IOP, obtained with medications. In patients undergoing surgery a 20% reduction was accepted.

Summary of results¹⁻⁵: A 30% reduction from baseline was maintained in nearly 50% of patients. Progression occurred in 12% (7/61) of treated eyes and 35% (28/79) of controls.

- A beneficial effect of IOP lowering was found only after the data were censored for the effect on VF of cataract formation¹
- In the intent-to-treat analysis no benefit of treatment was found²
- Cataracts were more common in patients treated with surgery
- No correlation with IOP levels maintained during follow up was found in either group
- Progression rates varied a lot. The mean progression rate in the untreated arm was 0.41 dB/year⁵. Prior documented progression did not increase the risk of future progression compared to subjects without such history

II.1.2 Early Manifest Glaucoma Trial (EMGT)

EMGT was a randomized, prospective trial comparing treatment versus no treatment to evaluate the effectiveness of IOP reduction in early, previously untreated open-angle glaucoma⁶. Secondary aims were to assess factors related to glaucoma progression, and to determine the natural history of the disease.

During a population-based screening among 44,243 residents in Sweden, 316 eyes of 255 patients were recruited.

Treated patients received a standardized treatment protocol of laser trabeculoplasty and topical betaxolol. Treatment or no-treatment remained unchanged as long as definite progression had not occurred. Primary outcome measure was progression of disease, defined by sustained increases of visual field loss or optic disc changes⁶.

Summary of results⁷⁻¹²: This study proves and quantifies the value of IOP reduction in patients with POAG, NTG and pseudoexfoliation glaucoma.

- A 25% decrease of IOP from baseline (mean untreated IOP 20.6 mmHg) reduced the risk of progression by 50%. Risk of progression decreased 10% with each mmHg IOP reduction from baseline to the first follow-up visit⁷
- Risk of progression was smaller with lower baseline IOP values and with a larger initial IOP drop induced by treatment⁸
- IOP reduction for the fixed treatment protocol, and for ALT depended very much on pre-treatment IOP^{13,14}
- Important risk factors for progression were: higher IOP, exfoliation syndrome, more baseline damage, higher age, disc haemorrhages, thinner CCT (in HTG), and low blood pressure (in NTG)¹⁰
- IOP fluctuation was not a risk factor for progression¹¹
- IOP did not increase but remained constant over time in untreated eyes with POAG, but increased over time in eyes with exfoliation glaucoma¹⁵
- Increase in lens opacity occurred more in the treatment arm than in the control arm⁷
- Disease progression rates varied substantially between individual patients.
- Untreated progression rates (natural history) were slower in NTG than in HTG, while eyes with exfoliation glaucoma progressed much faster¹⁶
- Progression criteria were more sensitive than those of AGIS and CIGTS, and definite progression was associated with a mean worsening of MD of less than 2dB¹⁷
- In the great majority of cases progression was found first by perimetry⁷
- QoL did not differ between treatment arms⁹
- The frequency of disc haemorrhages was higher with lower IOP and was not influenced by treatment¹⁸

II.1.3 The Ocular Hypertension Treatment Study (OHTS)

The OHTS was a multicentre, randomized, prospective clinical trial, designed to study the effect of topical ocular hypotensive medication in delaying or preventing the onset of glaucoma in patients with ocular hypertension (OH)¹⁹. 1,636 patients were recruited. Randomization was between treatment with IOP lowering medications and no treatment. The treatment goal was to lower the IOP to < 24 mmHg and at least 20% from baseline. The primary outcome was the development of primary open-angle glaucoma defined as reproducible visual field defects or reproducible optic disc deterioration. After the initial results were reported, also the control group received treatment.

Summary of results: Mean IOP reduction was 22.5% in the treated group, but also the control group showed decrease of IOP, 4.0%

- After 5 years 4.4% of patients in the treated group had developed signs of glaucoma damage versus 9% in controls ($p < 0.0001$), a 50% reduction of risk²⁰
- Thus > 90% of untreated patients had not converted to glaucoma after 5 years
- After 13 years 22% of patients who had initially been randomized to the control group had converted to glaucoma versus 16% in the group that was treated already at the start of the study²¹
- POAG conversion was detected first in disc photographs in around 50% of patients and by field testing in approximately 40%²²

- Risk factors for progression were: thinner CCT, higher IOP, disc haemorrhages, older age, larger vertical and horizontal cup-to-disc ratios, greater PSD
- Disc haemorrhages detectable in photographs had been missed at 87% of clinical examinations and rate of progression was higher in eyes with haemorrhages²³
- Cataract formation was more common in the medication group²⁴
- Results obtained from initially untreated patients who were later started on prostaglandins indicate that monocular trials (at least of prostaglandin drops) may have very limited value²⁵
- Retinal vein occlusions were uncommon but somewhat more common in the control group (2.1%) than in the treated group (1.4%), not statistically significant²⁶.

II.1.4 European Glaucoma Prevention Study (EGPS)

The EGPS was a multicentre, randomized, double-masked, placebo-controlled clinical trial. The aim of this study was to evaluate the efficacy of IOP reduction by dorzolamide in preventing glaucoma damage in patients with OH. The patients were randomized into 2 groups: active therapy (dorzolamide) and placebo. Main outcome measures were visual field and/or optic disc changes²⁷.

Summary of results²⁸: 1,081 patients were enrolled. The median duration of follow-up was 55 months. The IOP difference between the treatment and the control group was small. The mean IOP reduction was 15% after 6 months and 22% after 5 years in the dorzolamide group, but there was also a 9% reduction after 6 months and 19% after 5 years in the placebo group, to a large part attributable to high attrition.

The study failed to detect a statistically significant difference between the chosen medical therapy and placebo, either in IOP lowering effect, or in the rate of progression to POAG, and attrition was large²⁸.

The same predictors for the development of POAG were identified independently in both the OHTS observation group and the EGPS placebo group—baseline older age, higher intraocular pressure, thinner CCT, larger vertical cup-to-disc ratio, and higher Humphrey VF pattern standard deviation²⁹.

In a later paper diuretics were pointed as a possible risk factor³⁰.

II.2 Studies Comparing Treatments

II.2.1 Collaborative Initial Glaucoma Treatment Study (CIGTS)

The aim was to find out if glaucoma is better treated by initial treatment with medications or by immediate filtration surgery³¹.

607 patients with newly diagnosed open-angle glaucoma randomized to initial treatment with either medication or trabeculectomy (with or without 5-fluorouracil). A target IOP algorithm was used specific for each individual eye. Primary outcome variables were VF progression and Quality of Life (QoL). Secondary outcome variables were Visual Acuity (VA), IOP, and cataract formation. No event analysis has been provided identifying numbers of progressing eyes.

Summary of results³²⁻³⁴: IOP reduction was larger with surgery (48%; mean post treatment IOP 14-15 mmHg;) than with medications (35%; mean post treatment IOP 17-18 mmHg)³⁵.

- For many years mean perimetric progression (analysed as mean MD among all subjects) was small in both groups³², but after 8 years 21% of surgical patients and 25% of medical patient had progressed, defined as a worsening of MD by 3 dBs³⁵.
- After adjustment for baseline risk factors, larger IOP variation measures were associated with significantly worse MD values after 3 to 9 years in the medicine but not in the surgical group³⁶.
- QoL was initially better in the medically treated group³⁷.
- 1.1% of surgical patients had developed endophthalmitis after 5 years³⁸.
- Patients randomized to the surgery arm underwent cataract surgery more than twice as often as patients in the medical treatment group³³.
- Reversal of optic disc cupping was seen in 13% in the surgical group, but was not associated with improved visual function³⁹.
- Risk factors for progression have not been reported in a ways similar to that of the other large RCTs, but risk factors for higher IOP have been, and included higher baseline IOP, worse field status and lower level of education³⁴.

Inclusion criteria may have allowed recruitment of patients with ocular hypertension resulting in a case mix with a smaller risk of showing progression.

II.2.2 Advanced Glaucoma Intervention Study (AGIS)

AGIS was a multicentre, prospective randomized study in patients with advanced open-angle glaucoma patients who could not be controlled by maximum tolerated medical therapy alone. 591 patients (789 eyes) were randomised between two rather complicated treatments regimes:

1. ATT: argon laser trabeculoplasty then if needed followed by trabeculectomy and then by a 2nd trabeculectomy, or
2. TAT: trabeculectomy then argon laser trabeculoplasty if needed, and then trabeculectomy.

Enrolled eyes had consistent elevation of intraocular pressure (IOP) of ≥ 18 mmHg. Patients with MD worse than 16 dB were excluded thus excluding eyes with really advanced glaucoma as in several of the other RCTs⁴⁰.

Summary of results:

- In a post-hoc analysis of patients with 6-years of follow-up or more a eyes with average IOP > 17.5 mmHg over the first three 6-months visits showed a significantly more/more frequent visual field deterioration compared to eyes with IOP less than 14 mmHg during the same time. There was no average visual field progression, as measured by MD, in eyes with IOP < 18 mmHg at 100% of the visits, whereas eyes with less perfect IOP control showed a mean significant visual field worsening⁴¹
- After 7 years mean reduction of IOP was greater for eyes assigned to the TAT protocol, and the cumulative probability of failure of the first intervention was greater for eyes assigned to ATT
- The percentage of eyes with decreased visual acuity or visual field progression was lower for the ATT sequence than for TAT In Afro-American patients, but in Caucasians results were more favourable in the ATT during the first 4 years, but then switched in favour of TAT^{42,43}
- The probability of cataract formation after 5 years was high after trabeculectomy, 78 %³⁵. Initial trabeculectomy retarded the progression of glaucoma more effectively in Caucasians than in Afro-Americans⁴⁴
- Risk factors associated with progression were older age, longer follow-up, and, not surprisingly, increasing number of glaucoma interventions⁴⁵
- A flawed analysis erroneously indicated that IOP fluctuations were a risk factor for progression⁴⁵, while a later corrected indicated that such fluctuations were a risk in NTG only⁴⁶
- Both ALT and trabeculectomy failed more often in younger patients and in eyes with higher pre-treatment IOP AGIS investigators⁴⁷

II.3 Summary

These large RCTs have had enormous importance for glaucoma management. EMGT and OHTS are the first studies that without doubt showed that IOP reduction reduces rate of progression in manifest glaucoma and the incidence of glaucoma in ocular hypertension. In addition the RCTs show that IOP reduction reduces progression also in glaucoma eyes with normal IOP levels, and that risk reduction with IOP lowering is large; several of the studies show risk reductions of approximately 10% for every mmHg lower pressure.

Together they also identify the important factors for progression, in glaucoma, e.g., older age, higher IOP, more damage, pseudoexfoliation and disc haemorrhages, in ocular hypertension higher IOP, older age, thinner CCT and disc haemorrhages.

The RCTs have demonstrated the value of glaucoma treatment, resulted in more ambitious treatment and provided a much more solid foundation for evidence-based glaucoma care.

III - COST-EFFECTIVENESS OF GLAUCOMA CARE

III.1 Case Detection And Screening for Glaucoma

There are no systematic reviews or studies that provide evidence for direct or indirect links between glaucoma screening and visual field loss, visual impairment, optic nerve damage, intraocular pressure, or patient-reported outcomes. Also economic simulation models of cost effectiveness of screening report inconclusive results with large uncertainties⁴⁸⁻⁵². There is no evidence that interventions (e.g., training) improve opportunistic case finding⁵²⁻⁵⁴.

III.2 Clinical and Cost Effectiveness of Diagnostic Tests Used for Screening, Detection and Monitoring for Glaucoma

No randomized screening, diagnostic and follow-up trials reporting the clinical effectiveness or cost-effectiveness have been published^{48, 50, 51, 55}. Although there are numerous comparative diagnostic studies there is no evidence which test or combination of tests improve patient outcomes at a sustainable cost. There is a high degree of variability in the design and conduct of largely cross-sectional studies of diagnostic accuracy of technologies for glaucoma. Diagnostic studies typically compare the performance of a small number of technologies, and indirect comparisons with other tests have to be interpreted with caution (e.g., because of differences in population, study definitions, reference standard, etc.). The risk of bias of diagnostic study designs is an additional concern^{48, 50, 51, 55}. One of the major challenges to evaluate a diagnostic test in glaucoma is the lack of a perfect reference standard. There are multiple diagnostic technologies that can be potentially used to detect glaucoma. Diagnostic studies have been conducted in a variety of settings (e.g., screening, case detection in the community, and diagnosis at hospital eye services).

III.3 Treatment of Glaucoma and Ocular Hypertension in Preventing Visual Disability

There is high-level evidence that treatment (including medical, laser, and surgical treatments) decrease intraocular pressure and reduce the risk of development (e.g., in patients with OHT) and deterioration (i.e., in patients with established glaucoma) of optic nerve damage and visual field loss compared to no treatment. However, the direct effects of treatments on visual impairment and the comparative efficacy of different treatments are not clear. Which treatments improve patient-reported outcomes is also unclear⁵⁶. Based on the economic simulation models in the US, UK, Holland, and China, treating glaucoma appears to be cost effective compared to 'no treatment'. There is uncertainty whether to treat none, some or all patients with ocular hypertension^{48, 57-59}. When treated, the cost-effectiveness models of different therapeutic interventions give variable results⁴⁸.

Comment:

All published simulation models are based on characteristics of participants enrolled in relatively small and tight randomized controlled trials (RCTs) which may not include all important predictors in the general population and every-day practice. In addition, RCTs may give an optimistic impression of outcomes compared to 'real life' with poorer compliance and adherence to care both in patients and clinicians in implementing the guide lines and care protocols. As the data of glaucoma induced visual disability are limited, the blindness rates in the modeling studies have different estimates⁴⁸. Similarly, the data on utility values and influence of glaucoma severity in health status are limited. Retrospective observational data is incomplete and selective. Reliable and 'realistic' data (preferably from large randomized trials or prospective cohorts of 'usual patients') is not available so far⁴⁸.

III.4 Follow-Up Protocols And Models Of Care

There is no solid evidence of the optimum monitoring schemes, (e.g. frequency and timing of visits, technologies to be used for detecting progression) for patients with manifest glaucoma and ocular hypertension. Some modeling and retrospective studies suggest that more treatment may allow less frequent monitoring visits in ocular hypertension and stable glaucoma^{57, 59-61}. One RCT suggests that shared care may save costs⁶².

References

1. Group CN-TGS. Comparison of glaucomatous progression between untreated patients with normal-tension glaucoma and patients with therapeutically reduced intraocular pressures. *Am J Ophthalmol* 1998;126(4):487-97.
2. Group CN-TGS. The effectiveness of intraocular pressure reduction in the treatment of normal-tension glaucoma. . *Am J Ophthalmol* 1998;126(4):498-505.
3. Drance S, Anderson DR, Schulzer M. Risk factors for progression of visual field abnormalities in normal-tension glaucoma. *Am J Ophthalmol* 2001;131(6):699-708.
4. Anderson DR, Drance SM, Schulzer M. Factors that predict the benefit of lowering intraocular pressure in normal tension glaucoma. *Am J Ophthalmol* 2003;136(5):820-9.
5. Anderson DR, Drance SM, Schulzer M. Natural history of normal-tension glaucoma. *Ophthalmology* 2001;108(2):247-53.
6. Leske MC, Heijl A, Hyman L, Bengtsson B. Early Manifest Glaucoma Trial: design and baseline data. *Ophthalmology* 1999;106(11):2144-53.
7. Heijl A, Leske MC, Bengtsson B, et al. Reduction of intraocular pressure and glaucoma progression: results from the Early Manifest Glaucoma Trial. *Arch Ophthalmol* 2002;120(10):1268-79.
8. Leske MC, Heijl A, Hussein M, et al. Factors for glaucoma progression and the effect of treatment: the early manifest glaucoma trial. *Arch Ophthalmol* 2003;121(1):48-56.
9. Hyman LG, Komaroff E, Heijl A, et al. Treatment and vision-related quality of life in the early manifest glaucoma trial. *Ophthalmology* 2005;112(9):1505-13.
10. Leske MC, Heijl A, Hyman L, et al. Predictors of long-term progression in the early manifest glaucoma trial. *Ophthalmology* 2007;114(11):1965-72.
11. Bengtsson B, Leske MC, Hyman L, Heijl A. Fluctuation of intraocular pressure and glaucoma progression in the early manifest glaucoma trial. *Ophthalmology* 2007;114(2):205-9.
12. Heijl A, Leske MC, Bengtsson B, Hussein M. Measuring visual field progression in the Early Manifest Glaucoma Trial. *Acta Ophthalmol Scand* 2003;81(3):286-93.
13. Heijl A, Leske MC, Hyman L, et al. Intraocular pressure reduction with a fixed treatment protocol in the Early Manifest Glaucoma Trial. *Acta Ophthalmol* 2011;89(8):749-54.
14. Heijl A, Peters D, Leske MC, Bengtsson B. Effects of argon laser trabeculoplasty in the Early Manifest Glaucoma Trial. *Am J Ophthalmol* 2011;152(5):842-8.
15. Hyman L, Heijl A, Leske MC, et al. Natural history of intraocular pressure in the early manifest glaucoma trial: A 6-year follow-up. *Arch Ophthalmol* 2010;128(5):601-7.
16. Heijl A, Bengtsson B, Hyman L, Leske MC. Natural history of open-angle glaucoma. *Ophthalmology* 2009;116(12):2271-6.
17. Heijl A, Bengtsson B, Chauhan BC, et al. A comparison of visual field progression criteria of 3 major glaucoma trials in early manifest glaucoma trial patients. *Ophthalmology* 2008;115(9):1557-65.
18. Bengtsson B, Leske MC, Yang Z, Heijl A. Disc hemorrhages and treatment in the early manifest glaucoma trial. *Ophthalmology* 2008;115(11):2044-8.
19. Gordon MO, Kass MA. The Ocular Hypertension Treatment Study: design and baseline description of the participants. *Arch Ophthalmol* 1999;117(5):573-83.
20. Kass MA, Heuer DK, Higginbotham EJ, et al. The Ocular Hypertension Treatment Study: a randomized trial determines that topical ocular hypotensive medication delays or prevents the onset of primary open-angle glaucoma. *Arch Ophthalmol* 2002;120(6):701-13; discussion 829-30.
21. Kass MA, Gordon MO, Gao F, et al. Delaying treatment of ocular hypertension: the ocular hypertension treatment study. *Arch Ophthalmol* 2010;128(3):276-87.

22. Keltner JL, Johnson CA, Anderson DR, et al. The association between glaucomatous visual fields and optic nerve head features in the Ocular Hypertension Treatment Study. *Ophthalmology* 2006;113(9):1603-12.
23. Budenz DL, Anderson DR, Feuer WJ, et al. Detection and prognostic significance of optic disc hemorrhages during the Ocular Hypertension Treatment Study. *Ophthalmology* 2006;113(12):2137-43.
24. Herman DC, Gordon MO, Beiser JA, et al. Topical ocular hypotensive medication and lens opacification: evidence from the ocular hypertension treatment study. *Am J Ophthalmol* 2006;142(5):800-10.
25. Bhorade AM, Wilson BS, Gordon MO, et al. The utility of the monocular trial: data from the ocular hypertension treatment study. *Ophthalmology* 2010;117(11):2047-54.
26. Barnett EM, Fantin A, Wilson BS, et al. The incidence of retinal vein occlusion in the ocular hypertension treatment study. *Ophthalmology* 2010;117(3):484-8.
27. Miglior S, Zeyen T, Pfeiffer N, et al. The European glaucoma prevention study design and baseline description of the participants. *Ophthalmology* 2002;109(9):1612-21.
28. Miglior S, Zeyen T, Pfeiffer N, et al. Results of the European Glaucoma Prevention Study. *Ophthalmology* 2005;112(3):366-75.
29. Miglior S, Pfeiffer N, Torri V, et al. Predictive factors for open-angle glaucoma among patients with ocular hypertension in the European Glaucoma Prevention Study. *Ophthalmology* 2007;114(1):3-9.
30. Miglior S, Torri V, Zeyen T, et al. Intercurrent factors associated with the development of open-angle glaucoma in the European glaucoma prevention study. *Am J Ophthalmol* 2007;144(2):266-75.
31. Musch DC, Lichter PR, Guire KE, Standardi CL. The Collaborative Initial Glaucoma Treatment Study: study design, methods, and baseline characteristics of enrolled patients. *Ophthalmology* 1999;106(4):653-62.
32. Lichter PR, Musch DC, Gillespie BW, et al. Interim clinical outcomes in the Collaborative Initial Glaucoma Treatment Study comparing initial treatment randomized to medications or surgery. *Ophthalmology* 2001;108(11):1943-53.
33. Musch DC, Gillespie BW, Niziol LM, et al. Cataract extraction in the collaborative initial glaucoma treatment study: incidence, risk factors, and the effect of cataract progression and extraction on clinical and quality-of-life outcomes. *Arch Ophthalmol* 2006;124(12):1694-700.
34. Musch DC, Gillespie BW, Niziol LM, et al. Factors associated with intraocular pressure before and during 9 years of treatment in the Collaborative Initial Glaucoma Treatment Study. *Ophthalmology* 2008;115(6):927-33.
35. Musch DC, Gillespie BW, Lichter PR, et al. Visual field progression in the Collaborative Initial Glaucoma Treatment Study the impact of treatment and other baseline factors. *Ophthalmology* 2009;116(2):200-7.
36. Musch DC, Gillespie BW, Niziol LM, et al. Intraocular pressure control and long-term visual field loss in the Collaborative Initial Glaucoma Treatment Study. *Ophthalmology* 2011;118(9):1766-73.
37. Janz NK, Wren PA, Lichter PR, et al. The Collaborative Initial Glaucoma Treatment Study: interim quality of life findings after initial medical or surgical treatment of glaucoma. *Ophthalmology* 2001;108(11):1954-65.
38. Zahid S, Musch DC, Niziol LM, Lichter PR. Risk of endophthalmitis and other long-term complications of trabeculectomy in the Collaborative Initial Glaucoma Treatment Study (CIGTS). *Am J Ophthalmol* 2013;155(4):674-80, 80 e1.

39. Parrish RK, 2nd, Feuer WJ, Schiffman JC, et al. Five-year follow-up optic disc findings of the Collaborative Initial Glaucoma Treatment Study. *Am J Ophthalmol* 2009;147(4):717-24 e1.
40. Brown RH, Lynch M, Leef D, et al. The Advanced Glaucoma Intervention Study (Agis) .1. Study Design and Methods and Base-Line Characteristics of Study Patients. *Controlled Clinical Trials* 1994;15(4):299-325.
41. Investigators TA. The Advanced Glaucoma Intervention Study (AGIS): 7. The relationship between control of intraocular pressure and visual field deterioration. *Am J Ophthalmol* 2000;130(4):429-40.
42. Ederer F, Gaasterland DA, Dally LG, et al. The Advanced Glaucoma Intervention Study (AGIS): 13. Comparison of treatment outcomes within race: 10-year results. *Ophthalmology* 2004;111(4):651-64.
43. Investigators TA. The advanced glaucoma intervention study, 6: effect of cataract on visual field and visual acuity. . *Arch Ophthalmol* 2000;118(12):1639-52.
44. (AGIS) TAGIS. The Advanced Glaucoma Intervention Study (AGIS): 9. Comparison of glaucoma outcomes in black and white patients within treatment groups. *Am J Ophthalmol* 2001;132(3):311-20.
45. Nouri-Mahdavi K, Hoffman D, Coleman AL, et al. Predictive factors for glaucomatous visual field progression in the Advanced Glaucoma Intervention Study. *Ophthalmology* 2004;111(9):1627-35.
46. Caprioli J, Coleman AL. Intraocular pressure fluctuation a risk factor for visual field progression at low intraocular pressures in the advanced glaucoma intervention study. *Ophthalmology* 2008;115(7):1123-9 e3.
47. (AGIS) TAGIS. The Advanced Glaucoma Intervention Study (AGIS): 11. Risk factors for failure of trabeculectomy and argon laser trabeculoplasty. *Am J Ophthalmol* 2002;134(4):481-98.
48. Tuulonen A. Economic considerations of the diagnosis and management for glaucoma in the developed world. *Curr Opin Ophthalmol* 2011;22(2):102-9.
49. Vaahtoranta-Lehtonen H, Tuulonen A, Aronen P, et al. Cost effectiveness and cost utility of an organized screening programme for glaucoma. *Acta Ophthalmol Scand* 2007;85(5):508-18.
50. Burr JM, Mowatt G, Hernandez R, et al. The clinical effectiveness and cost-effectiveness of screening for open angle glaucoma: a systematic review and economic evaluation. *Health Technol Assess* 2007;11(41):iii-iv, ix-x, 1-190.
51. Ervin AM, Boland MV, Myrowitz EH, et al. *Screening for Glaucoma: Comparative Effectiveness*. Rockville (MD)2012.
52. Taylor HR, Crowston, J., Keeffe, J. et al. Tunnel vision: the economic impact of primary open angle glaucoma – a dynamic economic model. Melbourne: Centre for Eye Research Australia, 2008. www.cera.org.au.
53. Ratnarajan G, Newsom W, French K, et al. The impact of glaucoma referral refinement criteria on referral to, and first-visit discharge rates from, the hospital eye service: the Health Innovation & Education Cluster (HIEC) Glaucoma Pathways project. *Ophthalmic Physiol Opt* 2013;33(2):183-9.
54. Shah S, Murdoch IE. NICE - impact on glaucoma case detection. *Ophthalmic Physiol Opt* 2011;31(4):339-42.
55. Tarride JE, Burke N, Hopkins RB, et al. New glaucoma diagnostic technologies: a systematic review of economic studies. *Can J Ophthalmol* 2011;46(1):89-90.
56. Boland MV, Ervin AM, Friedman DS, et al. Comparative effectiveness of treatments for open-angle glaucoma: a systematic review for the U.S. Preventive Services Task Force.

- Ann Intern Med 2013;158(4):271-9.
57. Burr JM, Botello-Pinzon P, Takwoingi Y, et al. Surveillance for ocular hypertension: an evidence synthesis and economic evaluation. *Health Technol Assess* 2012;16(29):1-271, iii-iv.
 58. Li EY, Tham CC, Chi SC, Lam DS. Cost-effectiveness of treating normal tension glaucoma. *Invest Ophthalmol Vis Sci* 2013;54(5):3394-9.
 59. van Gestel A. Glaucoma management. Economic evaluations based on a patient level simulation model. Enschede, Holland: Ipskamp Drukkers, 2012.
 60. Hagman J. Comparison of resource utilization in the treatment of open-angle glaucoma between two cities in Finland: is more better? *Acta Ophthalmol* 2013;91 Thesis 3:1-47.
 61. Crane GJ, Kymes SM, Hiller JE, et al. Accounting for costs, QALYs, and capacity constraints: using discrete-event simulation to evaluate alternative service delivery and organizational scenarios for hospital-based glaucoma services. *Med Decis Making* 2013;33(8):986-97.
 62. Holtzer-Goor KM, van Sprundel E, Lemij HG, et al. Cost-effectiveness of monitoring glaucoma patients in shared care: an economic evaluation alongside a randomized controlled trial. *BMC Health Serv Res* 2010;10:312.

GLOSSARY

5-FU	5-Fluorouracil
AAC	Acute Angle-Closure
AC	Anterior Chamber
AGIS	Advanced Glaucoma Intervention Study
ALPI	Argon Laser Peripheral Iridoplasty
ALT	Argon Laser Trabeculoplasty
APAC	Anterior Chamber Paracentesis
BAC	Benzalkonium Chloride
CACG	Chronic Angle-Closure Glaucoma
CAM	Complementary And Alternative Medicine
CCT	Central Corneal Thickness
CDR	Cup/Disc Ratio
CH	Corneal Hysteresis
CIGTS	Initial Glaucoma Treatment Study
CNS	Central Nervous System
CNTGS	Collaborative Normal Tension Glaucoma Study
COPD	Chronic obstructive Pulmonary Disease
CRF	Corneal Resistance Factor
DCT	Dynamic contour tonometry
DD	Diffuse Defect
ECC	Enhanced Corneal Compensation
EGPS	European Glaucoma Prevention Study
EGS	European Glaucoma Society
EMA	The European Medicines Agency
EMGT	Early Manifest Glaucoma Trial
FC	Flow Chart
FD	Fourier-domain
FDA	Food and Drug Administration
FDT	Frequency Doubling Technology
FL	Fixation Losses
FN	False Negatives
FP	False Positive
GAPS	Glaucoma Adherence and Persistency Study
GAT	Goldmann Applanation Tonometry
GHT	The Glaucoma Hemifield Test
GON	Glaucomatous Optic Neuropathy
GPA	Glaucoma Progression Analyses
GPS	Glaucoma Probability Score
GSL	Goniosynechialysis
GSS	Glaucoma Staging System
HEP	Heidelberg Edge Perimetry
HIV	Human Immunodeficiency Virus
HPG	High Pressure Glaucoma
HRP	High-pass Resolution Perimetry
HRT	Heidelberg Retina Tomography

HSV	Herpes Simplex Virus
IAC	Intermittent Angle-Closure
ICE	Irido-Corneal Endothelial syndrome
IDDM	Insulin Dependent Diabetes Mellitus
IOL	Intraocular Lens
IOP	Intraocular Pressure
ISNT	Inferior-Superior-Nasal-Temporal rule
ITC	Iridotrabecular Contact
LPI	Laser Peripheral Iridotomy
LR	Likelihood Ratio
LD	Localized Defect
LTP	Laser Trabeculoplasty
LV	Loss Variance
MAO	Monoamine Oxidase
MD	Mean Defect
MMC	Mitomycin C
MRA	Moorfields Regression Analysis
NCT	Non-Contact Tonometry
NF-1	Neurofibromatosis type 1
NF-2	Neurofibromatosis type 2
NFI	Nerve Fibre Indicator
NMDA	N-Methyl-D-Aspartate
NPG	Normal Pressure Glaucoma
OAG	Open Angle Glaucoma
OCT	Optical Coherence Tomography
OH	Ocular Hypertension
OHTS	The Ocular Hypertension Treatment Study
ON	Optic Nerve
ONH	Optic Nerve Head
OPA	Ocular Pulse Amplitude
ORA	Ocular Response Analyser
OSD	Ocular Surface Disease
PAC	Primary Angle-Closure
PACG	Primary Angle-Closure Glaucoma
PACS	Primary Angle-Closure Suspect
PAS	Peripheral Anterior Synechiae
PCG	Primary Congenital Glaucoma
PC-IOL	Anteriorly Dislocated Posterior Chamber Intraocular Lens
PCL	Posterior Chamber Intraocular Lens
PDS	Pigment Dispersion Syndrome
PDT	Photo Dynamic Therapy
PEX	Pseudoexfoliation
PFV	Persistent Fetal Vasculature
PG	Pigmentary Glaucoma
PG	Prostaglandin
PI	Peripheral Iridotomy
PIOL	Phakic Intraocular Lens

POAG	Primary Open-Angle Glaucoma
POH	Pigmentary Ocular Hypertension
PPT	Pressure-Phosphene Tonometer
PSD	Pattern Standard Deviation
RCT	Randomized Controlled Trial
RNFL	Retinal Nerve Fiber Layer
RT	Rebound Tonometer
SAP	Standard Automated Perimetry
SD	Standard Deviation
SITA	Swedish Interactive Threshold Algorithm
SLT	Selective Laser Trabeculoplasty
SPK	Superficial Punctate Keratitis
SWAP	Short Wavelength Automated Perimetry
TCA	Topographic Change Analysis
TDO	Time Domain
TM	Trabecular Meshwork
UBM	Ultrasound Biomicroscopy
UGH	Uveitis-Glaucoma-Hyphema Syndrome
VEGF	Vascular Endothelial Growth Factor
VF	Visual Field
VFI	Visual Field Index
VZV	Varicella Zoster Virus
XFG	Exfoliative Glaucoma
XFS	Exfoliation Syndrome
YAG	Yttrium-Aluminium-Garnet



CHAPTER 1

Patient
Examination

1.1 - INTRAOCULAR PRESSURE (IOP) AND TONOMETRY

The intraocular pressure (IOP) in the population is approximately normally distributed with a right skew. The mean IOP in normal adult populations is estimated at 15-16 mmHg, with a standard deviation of nearly 3.0 mmHg¹⁻¹⁰. Traditionally, normal IOP has been defined as two standard deviations above normality, i.e. 21 mmHg, and any IOP above this level is considered to be elevated. The level of IOP is a major risk factor for the development of glaucoma and its progression. For example, the risk of having glaucoma for those with IOP measurements of 26 mmHg or greater is estimated to be 12 times higher than that for those with IOP within the normal range¹.

IOP diurnal variations can be substantial and are larger in glaucoma patients than in healthy individuals. Evaluating the IOP at different times of the day can be useful in selected patients [11,D].

1.1.1 Methods of measurement (tonometry)

Tonometry is based on the relationship between the intraocular pressure and the force necessary to deform the natural shape of the cornea by a given amount (except Dynamic Contour Tonometry, see below). Corneal biomechanical properties, such as thickness and elasticity, can affect the IOP measurements (Table 1.1). Tonometers can be described as contact or non-contact. Some instruments are portable and hand-held (e.g., Icare, Tonopen).

1.1.1.1 Goldmann applanation tonometry (GAT)

The most frequently used instrument, and the current reference standard [11,D], is the Goldmann applanation tonometer (GAT), mounted at the slit lamp¹¹. The method involves illumination of the biprism tonometer head with a blue light (obtained using a cobalt filter) that is used to flatten the anaesthetised cornea which has fluorescein in the tear film. The scaled knob on the side of the instrument is then turned until the inner border of the two hemi-circles of fluorescent tear meniscus, visualized through each prism, just touch (Fig. 1.1). There are potential problems of using GAT in that contact with the tear film and the cornea may raise concerns regarding transmissible disease. Chemical disinfection and disposable tonometer heads are used with the hope to reduce the risk of cross infection [11,D].

Errors with GAT can be due to incorrect technique (Fig. 1.2) and to the biological variability of the eye and orbit. Of particular note is the influence of the central corneal thickness (CCT). A tight collar or tie, Valsalva's manoeuvre, breath-holding, squeezing the lids or the examiner touching the lids can all falsely increase the IOP reading.

1.1.1.2 Alternative tonometers (in alphabetical order):

Table 1.2 below summarises the comparisons of IOP between other tonometers and GAT. A substantial proportion of IOP results differ by more than 2 mmHg¹². A complete list of all available technologies is beyond the scope of the guidelines.

- Dynamic contour tonometry (DCT, or Pascal)
This slit-lamp mounted instrument contains a sensor tip with concave surface contour and a miniaturized pressure sensor. The result and a quality score measure are provided digitally. This technique is reportedly less influenced by corneal thickness than GAT. The DCT additionally measures the ocular pulse amplitude (OPA) which is the difference between the mean systolic and the mean diastolic IOP¹³⁻¹⁸.
- Non-contact tonometry (NCT)
The NCT or air puff tonometry uses a rapid air pulse to flatten the cornea, thus working on the same basic principle as the Goldmann tonometer. The advantages include speed, no need for topical anaesthesia and no direct contact with the eye. There are several models available in the market. Some patients have found the air puff uncomfortable. There is currently insufficient evidence to replace GAT with non-contact tonometry^{19, 20}.
- Ocular Response Analyser (ORA)
The ORA utilises air-puff technology to record two applanation measurements, one while the cornea is moving inward, and the other as the cornea returns. The average of these two IOP values provides a Goldmann-correlated IOP measurement (IOP_G). The difference between these two IOP readings is called Corneal Hysteresis (CH), a result of viscous damping in the corneal tissue. The CH measurement provides a basis for two additional new parameters: Corneal-Compensated Intraocular Pressure (IOP_{CC}) and Corneal Resistance Factor (CRF). The IOP_{CC} is a measurement that is less affected by the corneal properties. Four good quality readings per eye are recommended²¹⁻²⁵ [I,I,D].
- Ocuton S
The Ocuton S is a self-measurement applanation tonometer that calculates and displays the IOP value automatically through direct contact of the measuring prism with the cornea. Topical anaesthetic is required^{26, 27}.
- Pneumatometry
The pneumatometer relies on the Mackay-Marg principle and measures intraocular pressure noninvasively through applanation tonometry²⁸. The sensing unit of the pneumatometer, covered with a Silastic diaphragm, pressurized air flows constantly through an opening centrally into the space between the nozzle and the diaphragm. When in contact with the cornea, the pressure of the airstream is increased and this increment is converted into IOP. This raises the pressure of the air stream in the central chamber, and this increment is converted into IOP²⁹. Measured values are usually higher than with GAT³⁰, this technique can be useful for non cooperating, bedridden patients or infants.

- Rebound tonometry (Icare)
The rebound tonometer is a simple portable device. Although it is a contact tonometer topical anaesthetic drops are not required and the tonometer has a disposable tip to minimise the risk of cross-infection. The device processes the rebound movement of a rod probe resulting from its interaction with the eye; rebound increases (shorter duration of impact) as the IOP increases. Six measurements are taken to provide accurate measurement results. The rebound tonometer can be particularly useful in children [II,C]. The Icare ONE Home device is a variation that has been designed for self tonometry³¹⁻³⁵.
- Tono-Pen
The Tono-Pen is a hand-held portable tonometer that determines IOP by making contact with the cornea (central contact is recommended) through a probe tip, causing applanation/indentation of a small area. Topical anaesthetic eye drops are used. After four valid readings are obtained the averaged measurement is given together with the standard error³⁶⁻³⁸.

Both the Icare and Tono-Pen are useful for patients with corneal disease and surface irregularity as the area of contact is small [II,C].

- Transpalpebral tonometry
This type of tonometry includes devices that measure IOP through the eyelid avoiding direct corneal contact. The Diaton[®] tonometer is a hand held, pen like, portable device applying this principle. The pressure-phosphene tonometer (PPT) (Proview[®]) has been developed as a self measurement tonometer. The threshold pressure for creating a phosphene (perception of light) associated with the localised indentation is the estimated IOP. There is insufficient evidence to replace GAT by transpalpebral tonometry³⁹⁻⁴³ [I,D].
- Triggerfish[®] (Sensimed) has a sensor embedded in a contact lens, based on strain gauges claimed to record changes in the area of the corneo-scleral junction. There is no evidence to support the use of this device in clinical practice⁴⁴.

1.1.2 Intraocular pressure and central corneal thickness

Central corneal thickness (CCT) influences GAT readings (Table 1.1). However, there is no agreement as to whether there is a validated and useful correction algorithm for GAT and CCT. The normal distribution of CCT is $540 \pm 30 \mu\text{m}$ (mean \pm SD)⁴⁵.

CCT variations after corneal refractive surgery make difficult to interpret GAT⁴⁶. A record of pre-operative CCT is helpful to manage patients undergoing refractive surgery [II,D].

Except for unusual circumstances, there is no evidence to support the use of methods alternative to Goldmann applanation tonometry for the routine management of patients suspected of having, or that do have, glaucoma.

Technique of Goldmann Applanation Tonometry.

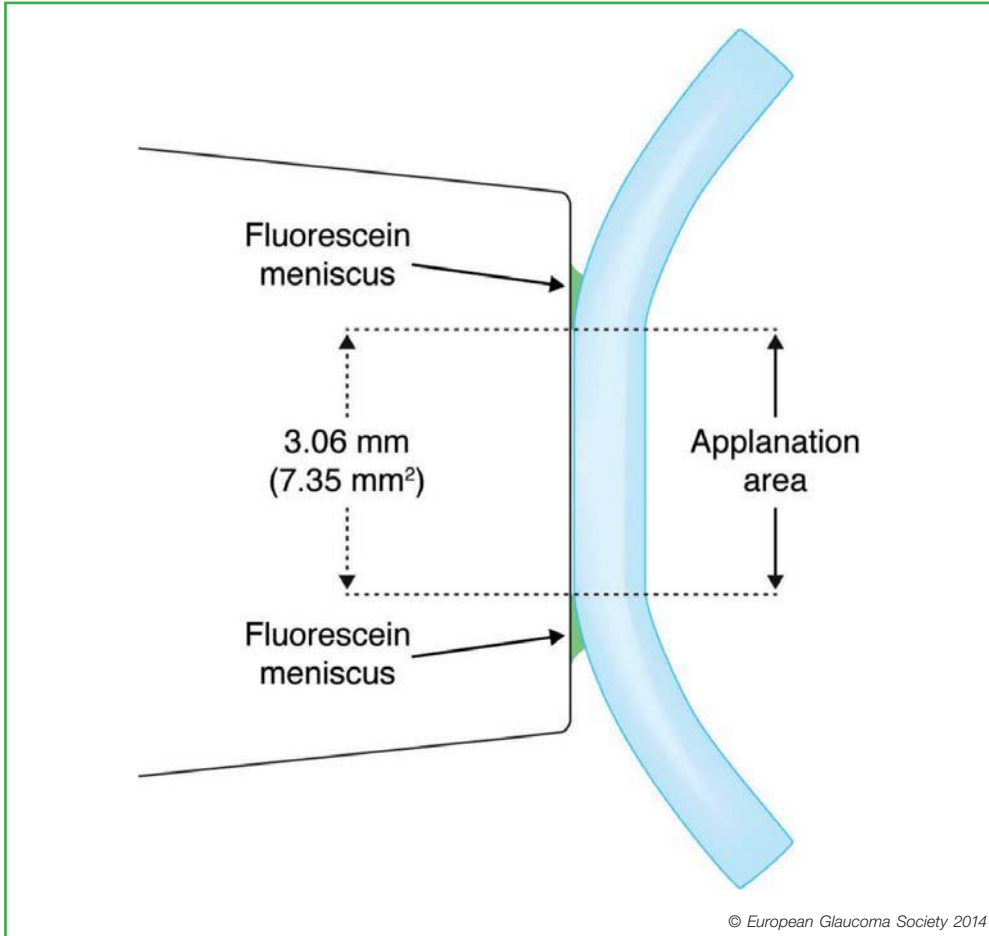


Figure 1.1. When there is contact between the tonometer prism (left) and the cornea, the stained tear meniscus can be observed through the prism.

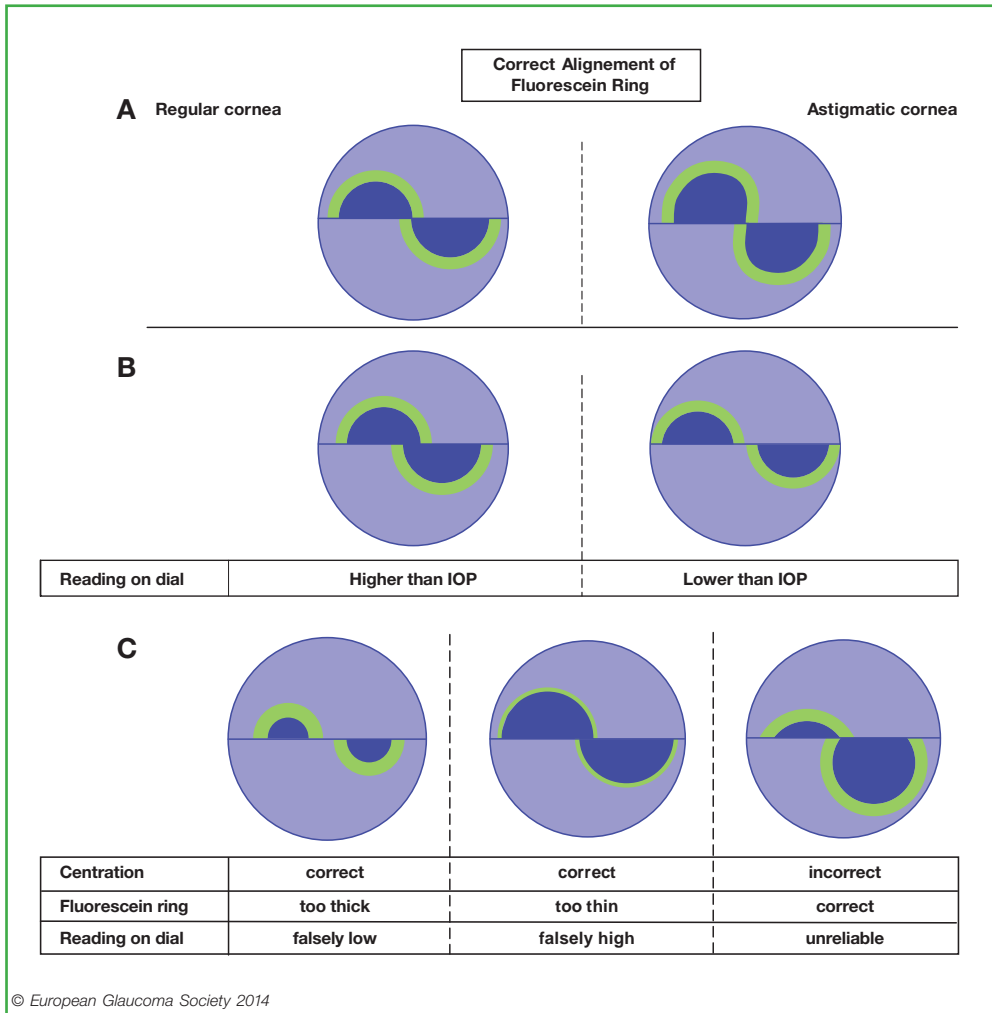


Figure 1.2. Correct technique (A): the prism is correctly aligned to the centre of the cornea and the applied pressure is then adjusted until the inner part of the semicircles touch each other. When the reading is taken before the semicircles are aligned as in (A), the applanation pressure will not correspond correctly to the IOP shown on the dial (B). Incorrect alignment can combine with incorrect amount of fluorescein, adding error on error (C).

Note: In case of high or irregular astigmatism, corrections should be made. One option is to do two measurements, the first with the biprism in horizontal position and the second in vertical position and the readings should be averaged. Another way of correcting large regular astigmatism (> 3 D) is to align the red mark of the prism with the axis of the minus cylinder.

Table 1.1 Influence of corneal status, thickness and tear film on the intraocular pressure (IOP) value measured with the Goldmann Applanation Tonometry.

Cornea Status	IOP reading erroneously high	IOP reading erroneously low
Thin central cornea		x
Thick central cornea	x	
Epithelial oedema		x
Excessive tear film		x
Insufficient tear film	x	
Corneal refractive surgery*		x

* Corneal refractive surgeries alter tonometry reading since they modify thickness, curvature and structure of the cornea.

Table 1.2 Differences in IOP between different tonometers and Goldmann Applanation Tonometry (GAT). Pooled estimates and summary 95% limits of agreement¹¹⁻⁴⁵.

Tonometer	Mean Difference between Tonometer and GAT	95% Confidence Interval		95% Limits of Agreement		% within 2 mmHg
DCT	1.8	+1.3	+2.3	-3.0	+6.6	47
NCT	0.3	-0.1	+0.7	-3.5	+4.0	69
ORA	1.5	+0.9	+2.2	-4.3	+7.3	45
Ocuton S	2.7	-1.2	+6.7	-4.0	+9.6	33
RT-(Icare)	0.9	+0.5	+1.5	-4.3	+6.3	51
TonoPen	0.2	-0.4	+0.9	-5.2	+5.7	52
Transpalpebral	-0.5	-1.3	+0.3	-7.0	+5.9	45

DCT = Dynamic Contour Tonometer; NCT = Non-Contact Tonometer; ORA = Ocular Response Analyzer; RT = Rebound Tonometer.

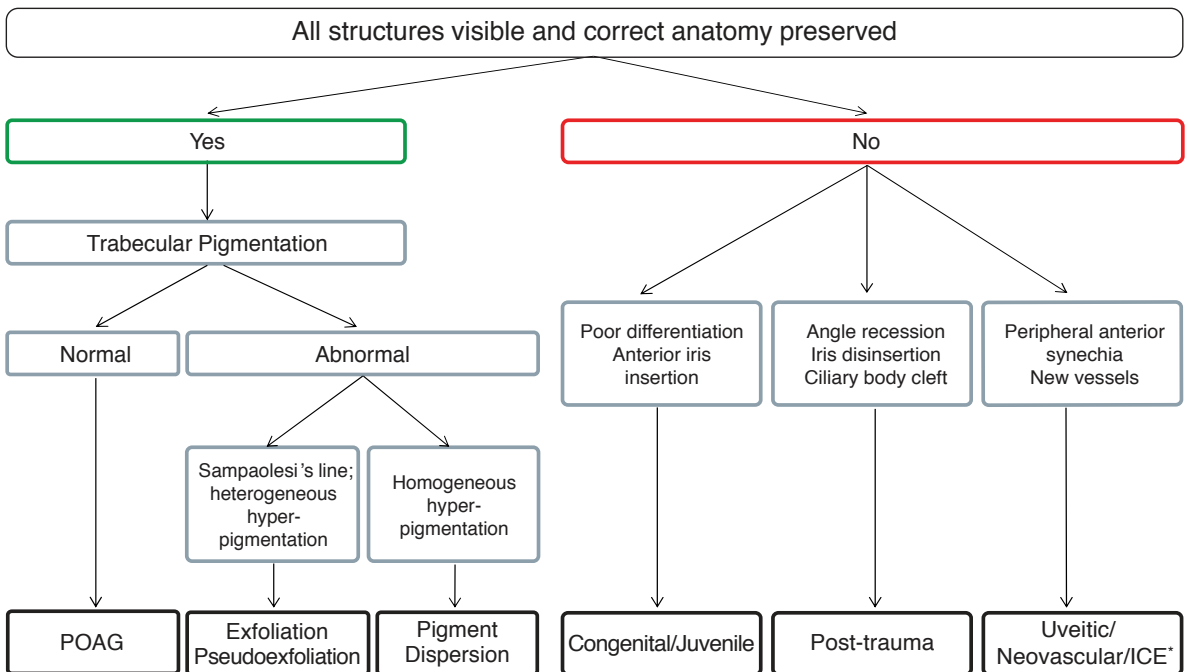
1.2 - GONIOSCOPY

Gonioscopy is an important part of the comprehensive adult eye examination and essential for evaluating patients suspected of having, or who do have glaucoma⁴⁷⁻⁵⁰ [I,D] (See FC II).

The purpose of gonioscopy is to inspect the anterior chamber angle. It is based on the recognition of angle landmarks and must always include an assessment of at least the following:

- a) level of iris insertion, both true and apparent
- b) shape of the peripheral iris profile
- c) width of the angle approach, i.e.: angular separation between the corneal endothelium and the anterior surface of the peripheral iris
- d) degree of trabecular pigmentation
- e) areas of iridotrabecular apposition or synechia

FC II - Diagnostic Gonioscopy in Open Angle in Glaucoma



*Irido Corneal Endothelial syndrome

1.2.1 Anatomy

Reference landmarks

Schwalbe's line: this collagen condensation of the Descemet's membrane between the trabecular meshwork and the corneal endothelium appears as a thin translucent line. Schwalbe's line may be prominent and anteriorly displaced (posterior embryotoxon), or there may be heavy pigmentation over it. A pigmented Schwalbe's line may be misinterpreted as the trabecular meshwork, particularly when the iris is convex. Indentation ('dynamic') gonioscopy and the corneal wedge method are helpful to distinguish between the structures by reliably identifying Schwalbe's line.

Trabecular Meshwork (TM): this extends posteriorly from Schwalbe's line to the scleral spur. Close to Schwalbe's line is the non-functional trabecular meshwork, blending into to the posterior, functional and usually pigmented TM. If the TM is not seen in 180° or more, angle closure is present. Most difficulties concerning examination of the TM relate to the determination of whether observed features are normal or pathological (particularly pigmentation), blood vessels and iris processes.

Pigmentation: pigment is found predominantly in the posterior meshwork. It is seen in adults, rarely before puberty and the extent can be highly variable. The most common conditions associated with dense pigmentation are: pseudoexfoliation syndrome, pigment dispersion syndrome, previous trauma, previous laser treatment of the iris, uveitis and after an acute angle-closure attack.

Blood vessels: these are often found in normal iridocorneal angles. They characteristically have a radial or circumferential orientation, have few anastomoses and do not run across the scleral spur. They can be seen most easily in subjects with blue irides. Pathological vessels are usually thinner, have a disordered orientation and may run across the scleral spur to form a neovascular membrane. Abnormal vessels are also seen in Fuchs' heterochromic iridocyclitis and chronic anterior uveitis.

Schlemm's canal: is not normally visible, though it may be seen if it contains blood. Blood reflux from episcleral veins may occur in cases of carotid-cavernous fistulae, Sturge Weber syndrome, venous compression, ocular hypotony, sickle cell disease or due to suction from the goniolens.

Scleral spur: is of white appearance and located between the pigmented TM and the ciliary body.

Iris processes: are present in one third of normal eyes, more evident in younger subjects. When numerous and prominent they may represent a form of Axenfeld-Rieger syndrome/anomaly. They are distinguished from goniosynechia which are thicker and wider and may go beyond the scleral spur.

Ciliary band and iris root: the iris insertion is usually at the anterior face of the ciliary body, though the site is variable. The ciliary band may be wide, as in myopia, aphakia or following trauma, or narrow or not seen as in hyperopia and anterior insertion of the iris.

1.2.2 Techniques

Gonioscopy is an essential part of all glaucoma patients evaluation [1,D]. Gonioscopy should always be performed in a dark room, using the thinnest slit beam, taking care to avoid shining the light through the pupil because of pupil constriction in light exposure^{51, 52} [1,D].

There are two main techniques for viewing the anterior chamber angle:

- **Direct Gonioscopy**

The use of some contact goniolenses like the Koeppe or Barkan lens permits the light from the anterior chamber to pass through the cornea so that the angle may be viewed (Fig. 1.3 top).

- **Indirect Gonioscopy**

The light from the anterior chamber is made to exit via a mirror built into a contact glass (Fig. 1.3.bottom).

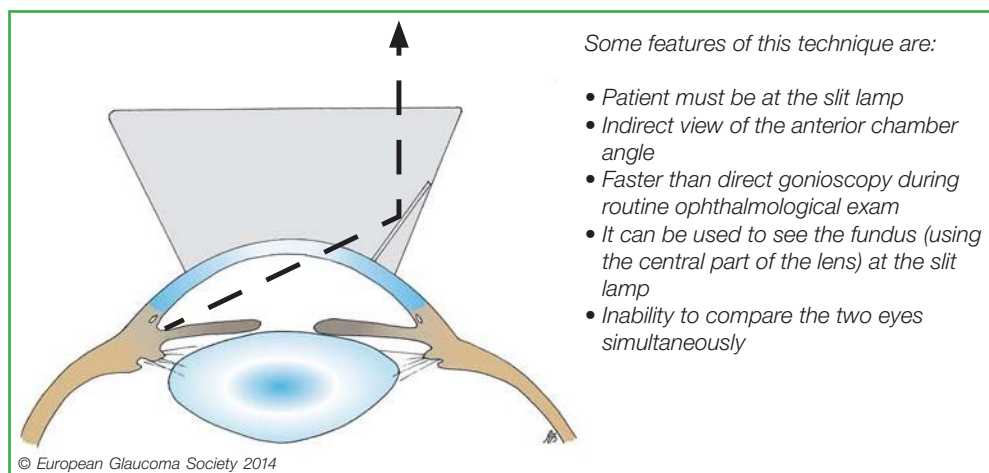
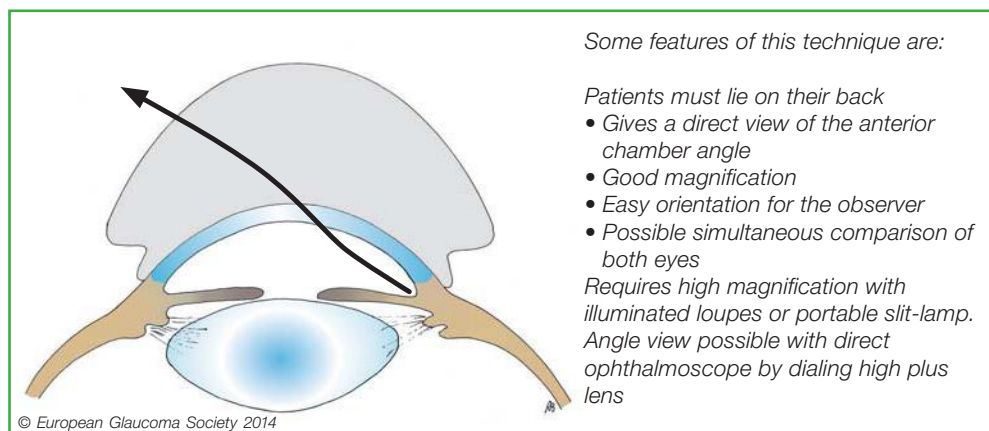


Figure 1.3

The most common Gonioscopy lenses:

Direct	Koeppel (contact fluid required)
	Layden (sized for infants; contact fluid required)
	Worst
Indirect	Posner or Zeiss or Sussman 4 mirror (contact fluid not required)
	Goldmann lens, 1 to 4 mirrors (contact fluid required)
	CGA 1.4® Lasag (contact fluid required)
	Magnaview (contact fluid required)

1.2.2.1 'Dynamic indentation' gonioscopy

It is recommended to use a small diameter lens for indentation (e.g.: 4-mirror) [I,D]. When gentle pressure is applied by the lens on the center of the cornea, the aqueous humour is pushed back. In appositional angle-closure, the angle can be re-opened. If there is adhesion between the iris and the meshwork, as in goniosynechia, that portion of angle remains closed (Fig. 1.4(3)).

When pupillary block is the prevalent mechanism the iris becomes peripherally concave during indentation. In iris plateau configuration this iris concavity will not be extended by indentation to the extreme periphery, which is a sign of anteriorly placed ciliary processes (double hump sign). When the crystalline lens has a particularly prominent role, indentation causes the iris to move only slightly backwards, retaining a convex profile (Fig. 1.4(4)).

To differentiate appositional from synechial closure "indentation" or "dynamic" gonioscopy is essential.

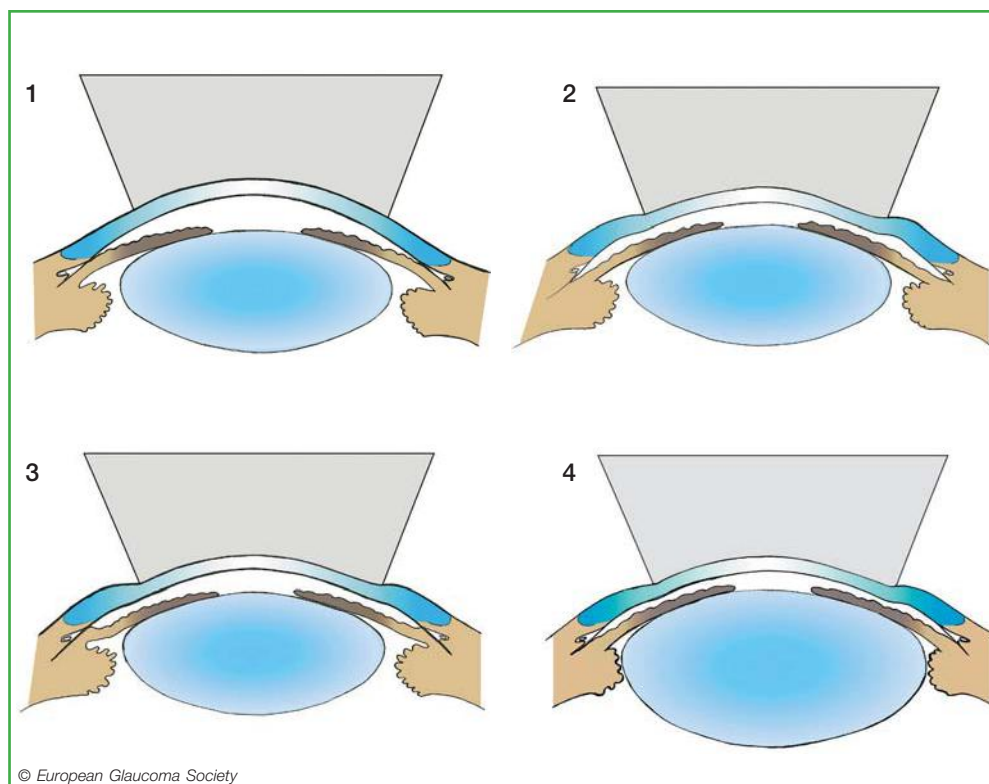


Figure 1.4. Dynamic indentation gonioscopy. When no angle structure is directly visible before indentation, angle-closure may be present, and it can be synechial or appositional (1). If during indentation the iris moves peripherally backwards and the angle recess widens (2), the picture in (1) is to be interpreted as appositional closure and a suspicion of relative pupillary block is raised (2). When during indentation the angle widens but iris strands remain attached to the angle outer wall (3), the picture in (1) is to be interpreted as synechial closure. A large and/or anteriorly displaced lens causes the iris to move only slightly and evenly backwards during indentation (4) making the lens a likely component of angle-closure.

1.2.2.2 Gonioscopy technique without indentation

With indirect Goldmann-type lenses it is preferable to start by viewing the inferior angle, which often appears wider than the superior angle, because it is easier to identify the different structures. Then to continue rotating the mirror [II,D]. The anterior surface of the lens should be kept perpendicular to the observation axis so that the appearance of the angle structure is not changed as the examination proceeds. The four quadrants are examined by a combination of slit-lamp movements and prism rotation.

In case of a narrow approach, it is possible to improve the visualization of the angle recess by asking the patient to look in the direction of the mirror being used.

Practical points

- **Related to the technique**

Gonioscopy should be performed in a dark room and with a small slit beam [I,D]. The most widely used technique is indirect gonioscopy where the angle is viewed in a mirror of the lens. The position of the globe is of importance. Angle width grading must be performed with the eye in primary position to avoid misclassification. If the patient looks in the direction of the mirror the angle appears wider and vice versa. A second pitfall is inadvertent pressure over the cornea, which will push back the iris, and gives an erroneously wide appearance to the angle. This occurs when the diameter of the lens is smaller than the corneal diameter e.g.: 4-mirror lenses. With a large diameter goniolens, indentation is transmitted to the periphery of the cornea distorting the angle.

- **Related to the anatomy**

Recognition of angle structures may be impaired by variations in the anterior segment structures like poor pigmentation, iris convexity or existence of pathological structures.

Pharmacological mydriasis

Dilation of the pupil with topical or systemic drugs can trigger angle-closure. Angle-closure attacks can occur, even bilaterally, in patients treated with systemic parasympatholytics before, during or after abdominal surgery and has been reported with many systemic drugs such as serotonergic 'appetite' suppressants⁵³.

Although pharmacological mydriasis with topical tropicamide and neosynephrine is safe in the general population even in eyes with a narrow approach, IOP elevation can occur in occasional patients (approx. 10%)⁵⁴. Screening with van Herick's test can detect angles at risk prior to dilating (Fig. 1.6).

Systemic drugs with effects on the angle

Theoretically, although any psychoactive drugs have the potential to cause angle-closure, it is unlikely that pre-treatment gonioscopy findings alone are of help to rule out such risk. In eyes with narrow angles, it makes sense to repeat gonioscopy and tonometry after initiation of treatment [II,D]. Prophylactic laser iridotomy needs to be evaluated against the risks of angle-closure or of withdrawal of the systemic treatment [II,D]. (See Ch. 2.4). None of these drugs is contraindicated per se in open-angle glaucoma. Ciliochoroidal detachment with bilateral angle-closure has been reported after oral sulpha drugs and topiramate⁵⁵.

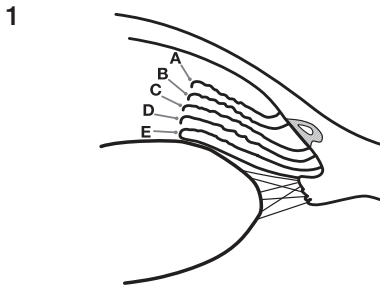
1.2.3 Grading

The use of a grading system for gonioscopy is highly desirable^{48, 56, 57} [I,D]. It stimulates the observer to use a systematic approach in evaluating angle anatomy, it allows comparison of findings at different times in the same patients, or to classify different patients.

The Spaeth gonioscopy grading system is the most detailed (Fig. 1.5)⁴⁸.

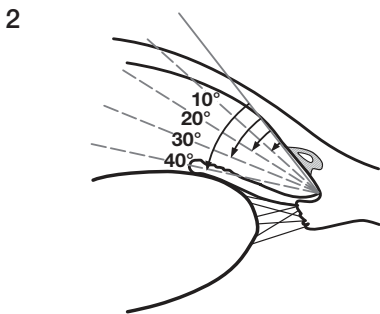
Other practical grading systems are those of Shaffer⁵⁸ and Kanski⁵⁹; both are based on angle width and visibility of the structures.

Document the insertion level of the iris root before and during compression dynamic gonioscopy



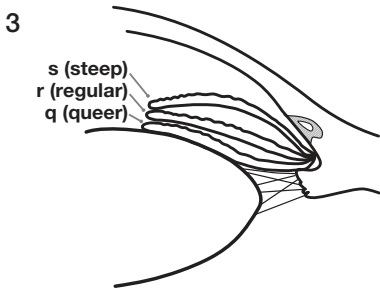
Insertion of iris root

- A Anterior to Schwalbe's line
- B Behind Schwalbe's line
- C On the Scleral Spur
- D Behind the Scleral Spur
- E On the Ciliary Band



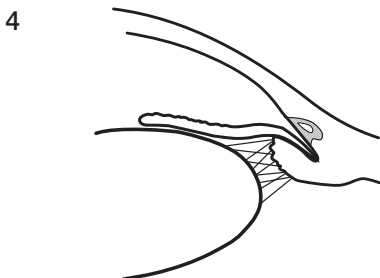Angular width of angle recess

- Slit
- 10° } narrow
 - 20° }
 - 30° } wide
 - 40° }



Configuration of the peripheral iris

- s Steep, anteriorly convex
- r Regular
- q Queer, anteriorly concave



Plateau Configuration

Figure 1.5. The Spaeth Grading System of gonioscopy finding.

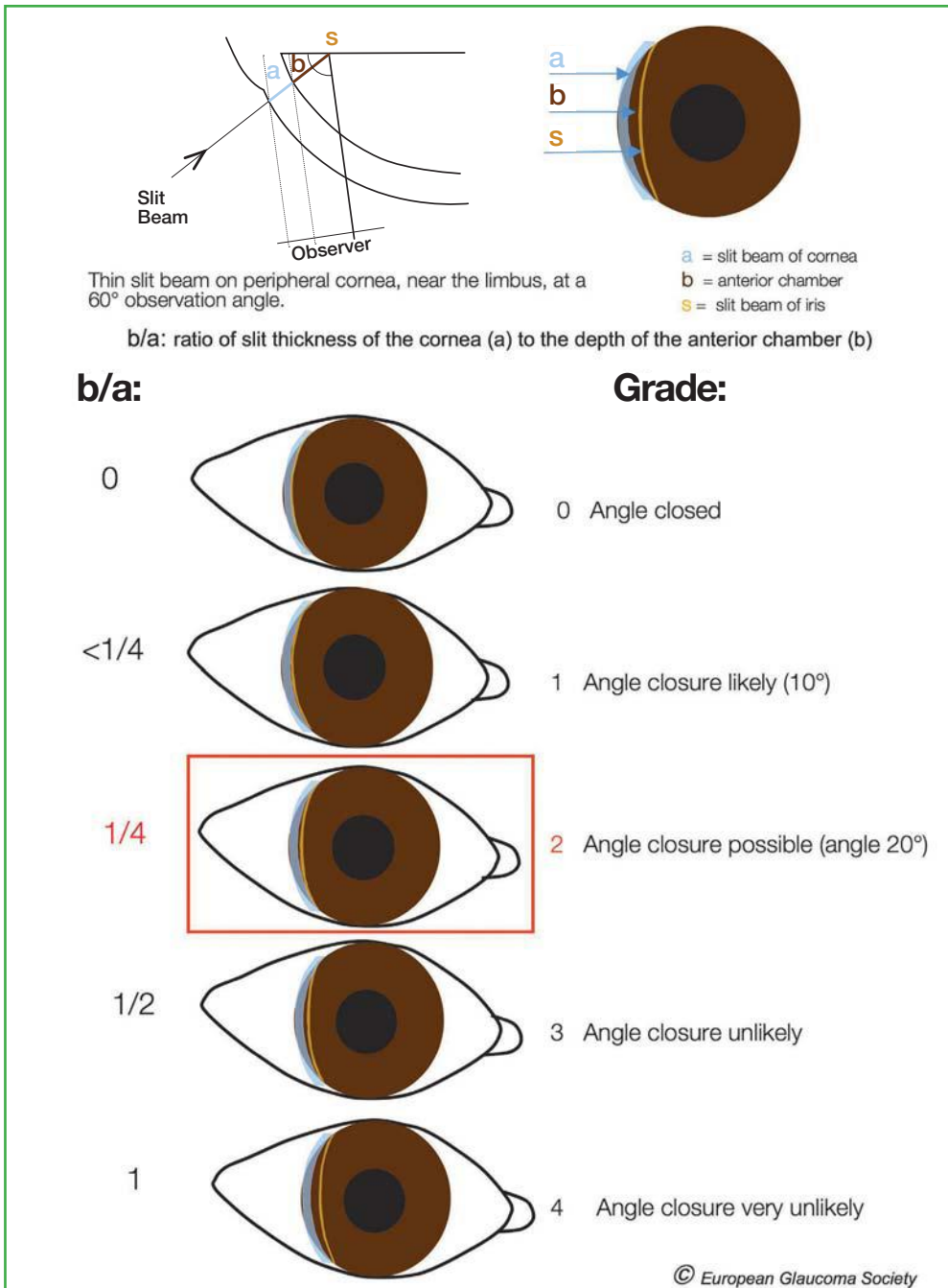


Figure 1.6. The Van Herick test.

1.2.3.1 Slit lamp-grading of peripheral AC depth - The Van Herick Method

The Van Herick grading is an important part of any comprehensive eye examination (Fig. 1.6) [II,D]. This method is very useful if a gonioscope is not available^{57, 60} [I,D] and can identify the need for gonioscopy in patients not otherwise suspected of glaucoma but it is not a substitute for gonioscopy. This technique is based on the use of corneal thickness as a unit measure of the depth of the anterior chamber at the furthest periphery, preferably on the temporal side.

Grade 0 represents iridocorneal contact.

A space between iris and corneal endothelium of $< 1/4$ corneal thickness, is a Shaffer grade I. When the space is $\geq 1/4 < 1/2$ corneal thickness the grade is II. A grade III is considered not occludable, with an irido/endothelium I distance $\geq 1/2$ corneal thickness.

1.2.4 Anterior Segment Imaging Techniques

UBM, anterior segment OCT and Scheimpflug cameras can be useful in some circumstances. Added to gonioscopy, these techniques help elucidate the mechanism of angle-closure in many cases [II,D]. Due to their limited availability and costs however, they are applied to cases which are most difficult to interpret⁶¹⁻⁶⁹. UBM is very helpful in diagnosis behind the iris and the pigmented epithelium (tumours, cysts). Anterior segment OCT and Scheimpflug cameras are suitable for volumetric measurements and documentation of the dynamics of the chamber angle at different light conditions. These instruments currently give information only on the examined sector and not about the total circumference. None of these imaging methods provides sufficient information about the anterior chamber angle anatomy to be considered a substitute for gonioscopy⁷⁰⁻⁸⁹

1.3 - OPTIC NERVE HEAD AND RETINAL NERVE FIBRE LAYER

Glaucoma changes the appearance of the optic nerve head (ONH) and the retinal nerve fibre layer (RNFL) in a characteristic fashion.

Contour changes can best be appreciated with a magnified stereoscopic view. Therefore the initial examination, and follow-up examinations for contour change, should be made preferably through a dilated pupil [I,D]. Interim examinations, aimed at detecting striking features such as disc haemorrhages, may be performed through an undilated pupil stereoscopic examination of the posterior pole is best performed with a:

- Indirect non-contact fundus lens with sufficient magnification at the slit-lamp or
- Direct contact fundus lens at the slit-lamp

The direct ophthalmoscope is also useful for ONH and RNFL examination. Although three-dimensional information using parallax movements is possible, binocular examination through a dilated pupil is superior. The clinical evaluation of the ONH and RNFL should assess the following features [I,D].

1.3.1 Clinical Examination - Qualitative

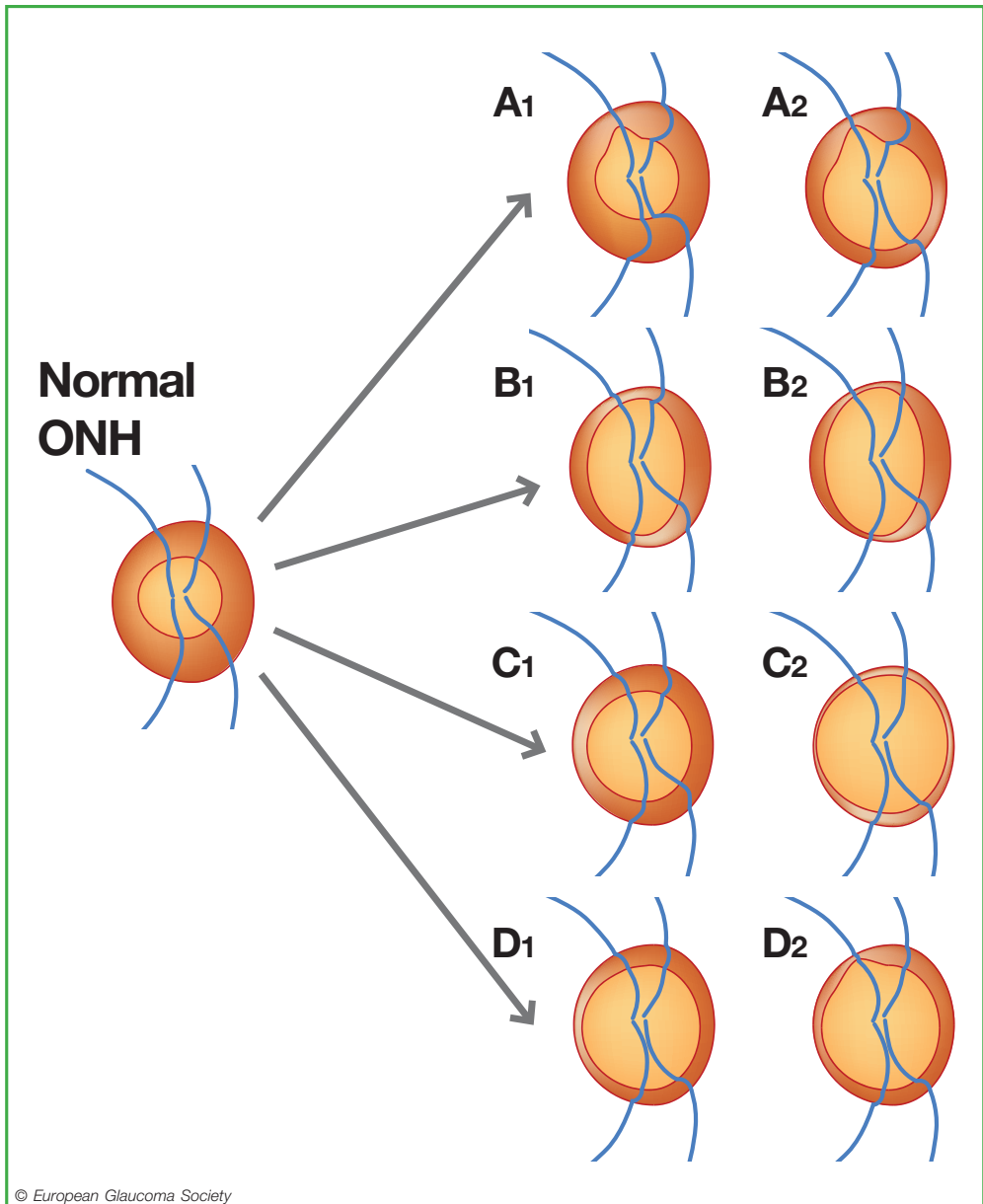
1.3.1.1 Neuroretinal Rim

In a healthy eye, the shape of the rim is influenced by size, shape and tilting of the optic nerve head. The disc is usually slightly vertically oval, often more so in black subjects who may also have larger discs. In normal sized discs, the neuroretinal rim is typically at least as wide at the 12 and 6 o'clock positions as elsewhere and usually widest (83% of eyes) in the infero-temporal sector, followed by the supero-temporal, nasal and then temporal sectors (the 'ISNT' rule, see fig. 1.10)⁹⁰.

This pattern is less obvious in larger discs, in which the rim is distributed more evenly and in a smaller discs where cupping may not be evident. Larger and a smaller discs are harder to interpret: e.g., in small discs the changes associated with glaucoma may not result in cupping, but 'saucerization' of the disc surface instead, and in large optic discs the normal rim is relatively narrow and can potentially be misinterpreted as glaucomatous.

The exit of the optic nerve from the eye may be oblique, giving rise to a tilted disc. Tilted discs are more common in myopic eyes, and show a wider, gently sloping rim in one disc sector and a narrower, more sharply-defined rim in the opposite sector. Discs in highly myopic eyes are even harder to interpret.

Glaucoma is characterized by progressive narrowing of the neuroretinal rim. The pattern of rim loss varies and may take the form of diffuse narrowing, localized notching, or both in combination (Fig. 1.7). Narrowing of the rim, while occurring in all disc sectors, is generally more common and greatest at the inferior and superior poles⁹¹⁻⁹⁵



© European Glaucoma Society

Figure 1.7. Progression of glaucomatous damage at the optic disc:
Early localized loss (A1), advancing to localized plus diffuse rim loss (A2).
Early localized rim loss, polar notches (B1); more advanced polar notches (B2).
Diffuse or concentric rim loss, early (C1); advanced (C2).
Diffuse rim loss (D1), followed by localized rim loss (notch) (D2).

1.3.1.2 Retinal nerve fibre layer

The RNFL appearance is best assessed with a red-free (green) photograph. Clinically, the RNFL can be assessed with the red-free light or a short, narrow beam of bright white light at high magnification to explore the parapapillary region. In healthy eyes, smaller retinal vessels are embedded in the RNFL. The RNFL surface is best seen if the focus is adjusted just anterior to the retinal vessels.

The fibre bundles are seen as silver striations. About two disc diameters from the disc the RNFL thins and feathers out. Slit-like, groove-like, or spindle-shaped apparent defects, narrower than the retinal vessels, may be seen in the normal fundus. The RNFL becomes less visible with age, and is more difficult to see in less pigmented fundi.

Defects are best seen within two disc diameters of the disc. Focal (wedge and slit) defects are seen as dark bands, wider than retinal vessels and extending from the disc margin, unless obscured by vessels. These focal defects are more easily seen than generalized thinning of the RNFL, which manifests as a loss of brightness and density of striations. When the RNFL is thinned, the blood vessel walls are sharp and the vessels appear to stand out in relief against a matt background. The initial abnormality in glaucoma may be either diffuse thinning or localized defects. Since the prevalence of RNFL defects is < 3% in the normal population, their presence is likely to be pathological⁹⁶⁻⁹⁸.

1.3.1.3 Optic disc haemorrhages

The prevalence of small ('splinter') haemorrhages on or bordering the optic disc has been estimated to be $\leq 0.2\%$ in the normal population⁹⁹. On the other hand, a large proportion of glaucoma patients have optic disc haemorrhages (ODHs) at one time or another (Fig. 1.8). They are very often overlooked at clinical examinations, and are easier to find in photographs¹⁰⁰⁻¹⁰³. Many studies have shown that ODHs are associated with disease progression.

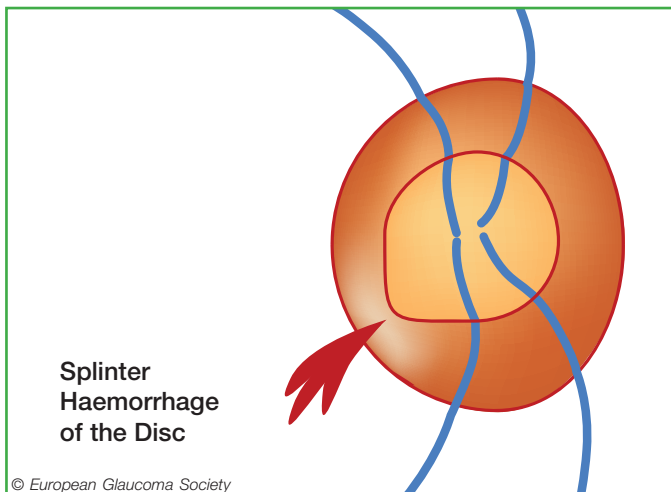


Figure 1.8. Optic disc haemorrhage.

1.3.1.4 Vessels at the optic disc

Narrowing of the neuroretinal tissue will change the position of the vessels at the optic disc with bending, bayoneting or barring of circumferential vessels. Those positional changes are particularly important to observe when looking for progression, in comparison to a baseline photo.

1.3.1.5 Parapapillary atrophy

Parapapillary atrophy can be differentiated into an Alpha zone, which is present in almost any eye, and into a Beta zone, which is present in approximately 25% of normal eyes and in a significantly higher percentage of eyes with glaucoma¹⁰⁴⁻¹⁰⁶.

The Alpha zone has been defined as irregular hyperpigmentation and hypopigmentation and it is located in the periphery of parapapillary atrophy. The Beta zone is characterized by visible sclera and visible large choroidal vessels and a location between the peripapillary ring and Alpha zone. Both zones are usually located at the temporal margin of the optic disc, more often in the inferotemporal region than in the superotemporal region. Histologically, the Alpha zone corresponds to irregularities in the retinal pigment epithelium, and the Beta zone shows a complete loss of retinal pigment epithelium, an almost complete loss of photoreceptors and a closure of the choriocapillaris. The Beta zone may be associated with a greater amount of glaucomatous optic neuropathy and a higher risk of further progression of glaucoma¹⁰⁷. The location of the Beta zone outside the optic disc spatially correlates with the location of the most marked loss of neuroretinal rim inside of the optic disc, together with the longest distance to the central retinal vessel trunk in the optic nerve head¹⁰⁴. In clinical routine, a large ophthalmoscopic Beta zone (in particular in non-myopic eyes) should be regarded as an extra clue, and not as a definite sign of glaucoma (Fig. 1.9) [I,C].

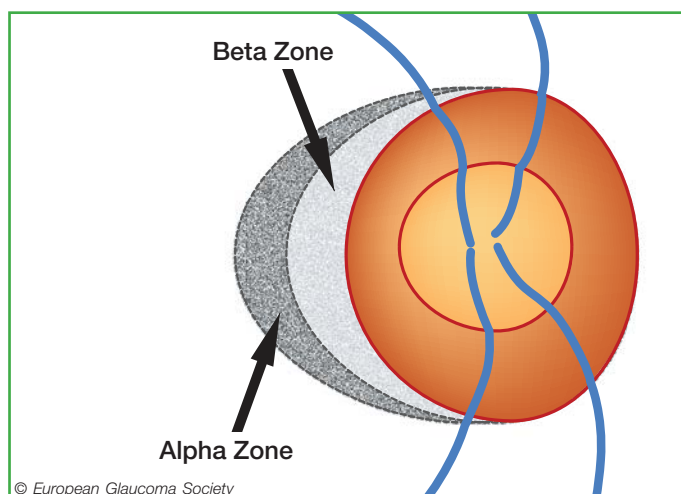


Figure 1.9. ONH with parapapillary atrophy. The Alpha zone is located peripheral to beta zone, and is characterized by irregular hypo- and hyperpigmentation. The Beta zone of atrophy is adjacent to the optic disc edge, external to Elschnig's ring (a white circular band that separates the intra- from the peri-papillary area of the optic disc), with visible sclera and large choroidal vessels.

1.3.1.6 The ISNT rule

In normal eyes with a normal optic disc shape, with a greater vertical diameter, the neuroretinal rim shows a characteristic shape: it is usually widest at the inferior disc pole, followed by the superior disc pole, the nasal disc region, and finally the temporal disc region¹⁰⁸. For mnemonic reasons, this sequence of disc sectors was abbreviated as “ISNT” (Inferior-Superior-Nasal-Temporal) rule. In many eyes, the rim can be wider superiorly than inferiorly, however in almost all normal eyes the rim is smallest in the temporal 60° of the optic nerve head (Fig. 1.10). The most important letter in the “ISNT”-rule is therefore the “T”. The application of the ISNT rule is helpful for detecting early glaucomatous optic nerve damage, since in the early stage of glaucoma, the rim gets smaller preferentially in temporal inferior disc region or the temporal superior disc region, leading to a rim shape in which the rim can be equal in width in the inferior or superior region as compared with the temporal region. For the assessment of the ISNT rule, it is important to consider that the area of the peripapillary ring does not belong to the neuroretinal rim. It holds true in particular for the temporal disc region.

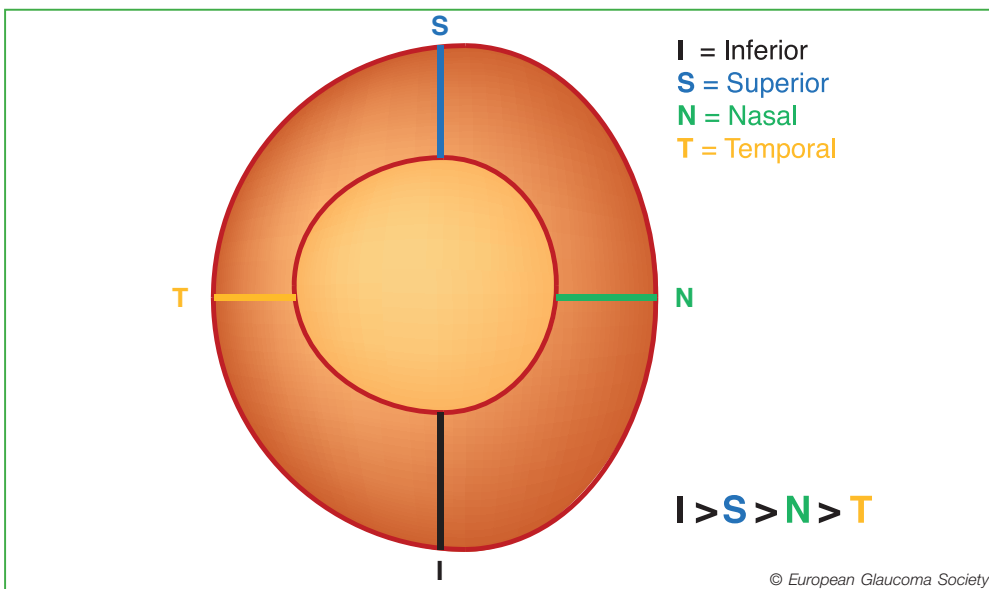


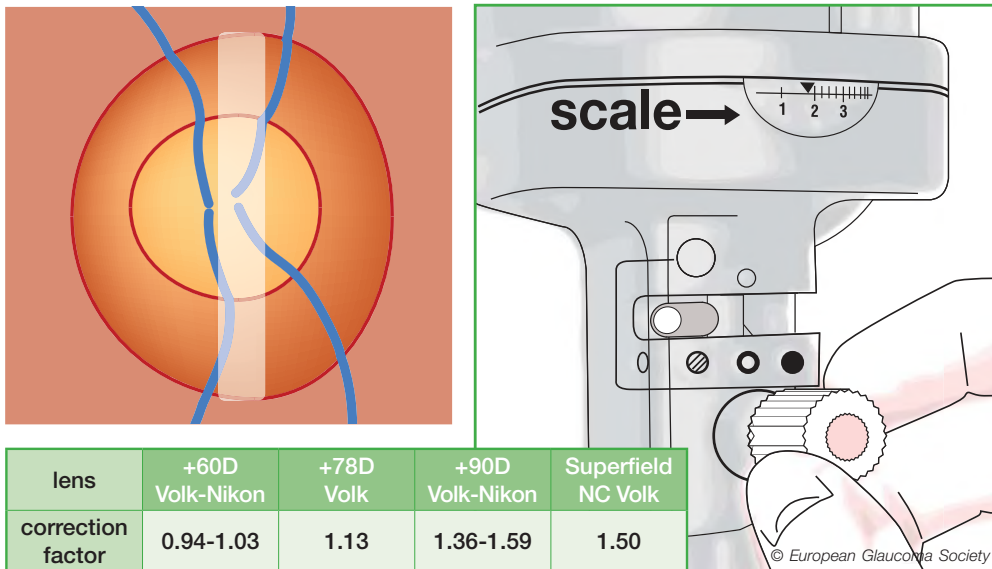
Figure 1.10. The ISNT rule.

1.3.2 Clinical Examination - Quantitative

1.3.2.1 Optic disc size (vertical disc diameter)

The optic disc size greatly varies in the population. The width of the rim and, conversely, the size of the cup, vary with the overall size of the disc. The mean vertical disc diameter is approximately 1.5 mm¹⁰⁹.

The vertical diameter of the optic disc can be measured at the slit lamp using a handheld high power convex lens. The slit beam should be coaxial with the observation axis; a narrow beam is used to measure the vertical disc diameter using the inner margin of the white Elschnig's ring as the reference. A correction factor needs to be used depending on the magnification of the handheld lens (Fig. 1.11).



Measured vertical diameter of optic disc			
	Small	Medium	Large
Disc area	<1.6 mm ²	1.6 to 2.8 mm ²	>2.8 mm ²
Volk 60 D	<1.65 mm	1.65 to 2.2 mm	>2.2 mm
78 D	<1.3 mm	1.3 to 1.75 mm	>1.75 mm
90 D	<1.1 mm	1.1 to 1.45 mm	>1.45 mm
Superfield	<1.15 mm	1.15 to 1.50 mm	>1.5 mm
Digital 1.0x	<1.5 mm	1.5 to 1.95 mm	>1.95 mm
Super 66	<1.45 mm	1.45 to 1.9 mm	>1.9 mm
Nikon 60 D	<1.45 mm	1.45 to 1.9 mm	>1.9 mm
90 D	<0.95 mm	0.95 to 1.25 mm	>1.25 mm
Haag-Streit Goldmann	<1.3 mm	1.3 to 1.7 mm	>1.7 mm

Figure 1.11. Optic disc size assessed at the slit lamp with handheld high power convex lens.

1.3.2.2 Rim Width and Cup/Disc ratio

A large Cup/Disc Ratio (CDR) has been used as a sign of glaucoma damage. However, the CDR depends on the disc size, and a large CDR in normal large discs may be erroneously considered glaucomatous and a small CDR in glaucomatous small discs may be erroneously considered as normal¹¹⁰ (Fig. 1.12). The use of CDR to classify patients is not recommended and the attention should be focused on the disc rim [I,D].

In healthy eyes, cupping tends to be symmetrical between the two eyes, the vertical CDR difference being less than 0.2 in over 96% of normal subjects. A difference in CDR between eyes with equal optic disc size is suggestive of acquired damage and glaucoma

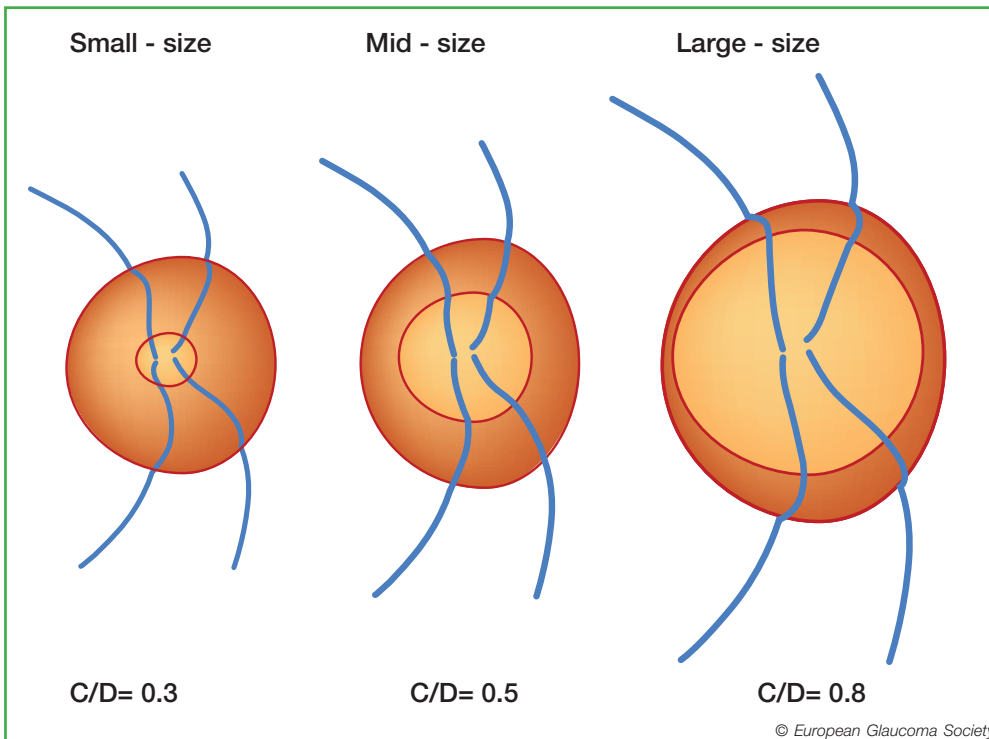


Figure 1.12. Optic nerve heads with different disc areas but with the same rim area and the same number of retinal nerve fibres: small size disc (disc area less than 2 mm² and C/D=0.3), mid-size disc (disc area between 2 and 3 mm², C/D=0.5) and large disc (disc area greater than 3 mm² and C/D=0.8).

1.3.3 Recording of the Optic Nerve Head (ONH) Features

At baseline, some form of imaging is recommended to provide a record of the ONH appearance [I,D]. If colour photos are not available, a detailed manual drawing is recommended. Even if it is difficult to draw a good picture of the ONH, the act of making a drawing encourages a thorough clinical evaluation of ONH [II,D].

Stereoscopic is preferred to non-stereoscopic photography [I,D]. Colour photography with a 15° field gives optimal magnification. Sequential photographs can be used to detect progression of optic disc damage.

1.3.3.1 Quantitative Imaging

Quantitative imaging of the optic nerve head, retinal nerve fibre layer and inner macular layers have been widely used to assist glaucoma diagnosis and to detect glaucomatous progression during follow-up.

1.3.3.2 Classification

For cross sectional classification, imaging instruments typically provide three potential outcomes: “within normal limits”, “borderline” and “outside normal limits”. No imaging device provides a clinical diagnosis but just a statistical result, based on comparison of the measured parameters with the corresponding normative database of healthy eyes. Therefore an interpretation of the result in the context of all clinical data is mandatory [I,D]. The clinician should also assess the quality of the image and analysis and judge whether the normative database is relevant for the particular patient before including the classification in the assessment of the patient [I,D]. For instance, imaging artefacts and software errors are quite common and more frequent in eyes that are highly myopic or have very tilted nerves, and few devices have normative data appropriate to these eyes. The various imaging technologies have their own advantages and limitations, and their classification shows only partial agreement in early glaucoma¹¹¹. In addition, agreement between classification with quantitative imaging and visual field testing is only moderate in early glaucoma.

1.3.3.3 Detection of progression

Most commercial imaging devices have software for quantifying glaucomatous progression, including the rate of progression. The classification algorithms described above should not be used to assess progression [I,D]. In general, normative databases are not needed for progression analysis because the patient’s baseline images provide the reference for change. High quality baseline images are, therefore, of considerable importance. The user should assess the test series for the quality of images and software analysis before including the software output in the assessment of the patient [I,D]. Agreement between structural progression and functional deterioration, over the relatively short duration of reported studies, is only partial or poor^{112, 113}.

Provided the images in a series are of good quality and progression analysis is

consistent over several tests, imaging devices provide useful data, additional to those gained from visual field testing, concerning a patient's glaucoma damage.

1.3.3.4 Imaging instruments

A complete list of all available technologies is beyond the scope of the guidelines.

- **Heidelberg Retina Tomography (HRT)**
The Heidelberg Retina Tomograph (Heidelberg Engineering, Heidelberg, Germany) is used to profile and measure the three-dimensional anatomy of the optic nerve head and surrounding tissues. It can also detect progressive changes in optic nerve head surface topography. To classify an optic nerve head, three methods can be used: the Moorfields Regression Analysis (MRA), the linear discriminant analysis formulas and the Glaucoma Probability Score (GPS)¹¹⁴⁻¹¹⁶. The classification algorithms tend to over-report 'outside normal limits' in large optic discs. For progression analysis, the software provides a map of surface height changes compared to baseline (Topographic Change Analysis [TCA]); the area and volume of changing regions is presented as a plot over time. Graphs of rim area over time are also available.
- **Scanning laser polarimetry (GDx-ECC)**
The GDx-ECC instrument (Carl Zeiss Meditech Inc., Dublin, CA, USA) measures retinal nerve fibre layer thickness around the optic nerve head on the basis of retardation of the illuminating laser light. All polarizing structures in the eye cause retardation, especially the cornea. With Enhanced Corneal Compensation (ECC), polarization artefacts arising both from the anterior segment and behind the retina are attenuated¹¹⁷. The main parameter to help distinguish healthy subjects from glaucomatous patients is the NFI (nerve fibre indicator), although clinicians should also evaluate the distribution of the retinal nerve fibre layer around the optic disc (the 'TNSIT' curve). Trend and change from baseline analyses for progression are available.
- **Optical coherence tomography (OCT)**
Optical coherence tomography is based on interferometry. Current instruments, Fourier-domain (FD) or Spectral domain (SD) and swept-source OCT systems, provide faster image acquisition, higher resolution and better image segmentation than time-domain OCT. Several companies produce FD/SD OCT instruments. Their technical, software and normative database characteristics vary; thus the values measured with different OCT systems are not interchangeable. Three main parameter groups are measured and analysed for classification and detection of progression: Optic Nerve Head, Retinal Nerve Fibre Layer and Ganglion Cell Complex. In general, the optic nerve head parameters with OCT may be less informative than the retinal nerve fibre layer and the ganglion cell complex parameters¹¹⁸. To identify and measure glaucomatous progression with OCT systems trend analysis of the retinal nerve fibre layer thickness and inner macular retinal thickness parameters are particularly useful¹¹⁹.

How to use imaging at baseline [II,D]

Glaucoma suspects with normal or unreliable visual field

Glaucoma with early and moderate damage

How to use imaging for monitoring progression [II,D]

Frequency should be similar to that for VF testing

- Patients should be followed with the same test/method to facilitate estimation of progression [I,D].
- Baseline, repeated within 3 months after baseline, and then up to 4 more times in the first two years in case of high risk of progression [II,D].
- Baseline, repeated annually, for ocular hypertensives [II,D].

Although knowing the test-retest variability would be indispensable in determining the optimal frequency of performing imaging tests, in every-day clinical work it seems currently impossible to take into account the large number of parameters and their largely variable reproducibility nor to verify the cost effectiveness of imaging for glaucoma¹²⁰.

1.4 - PERIMETRY

1.4.1 Perimetry Techniques

Visual field testing is important for the diagnosis of glaucoma, and even more important for follow-up and management of glaucoma [I,D].

A complete list of all available technologies and strategies is beyond the scope of the guidelines.

1.4.1.1 Computerised and manual perimetry

Static computerised perimetry should be preferred in glaucoma management. Kinetic e.g. Goldmann perimetry is not suitable for detection of early glaucomatous field loss and small defects will often be lost between isopters¹²¹.

Computerised perimetry is also less subjective; the results are numerical and tools for computer-assisted interpretation are available. Manual kinetic perimetry may be helpful in patients who are unable to perform automated perimetry.

1.4.1.2 Standard Automated Perimetry - SAP

Glaucoma perimetry has become more standardised over time and today the term Standard Automated perimetry (SAP) is often used. SAP refers to static computerised threshold perimetry of the central visual field performed with white stimuli on a dimmer white background.

- Test algorithms and programs

In glaucoma care threshold perimetry is the recommended standard [I,D]. Commonly used threshold algorithms are: 'SITA Standard' and 'SITA Fast' in the Humphrey perimeter. SITA Fast has the advantage of reduced test time but this may come at the cost of increased variability. In the Octopus perimeter the commonly used threshold algorithms called the 'Dynamic Strategy'. TOP algorithm is more rapid, but may have lower resolution than other threshold tests because threshold values are determined by averaging test results from several adjacent test point locations¹²².

Glaucoma perimetry is performed using a Goldmann size III stimulus in the central 25–30° field where the great majority of retinal ganglion cells are located [I,D].

Common test point patterns are the identical 30-2 and 32 test point patterns of the Humphrey and Octopus perimeters respectively and G1 and G2 patterns of the Octopus, which cover the central 30°. A commonly used pattern is the 24-2 pattern of the Humphrey perimeter, which covers a somewhat smaller area and thereby reduces test time. Only a small amount of information is lost if the smaller patterns are used as compared to the larger ones, and common test artefacts from, e.g., trial lens rims or droopy lids are less common with the more central patterns.

- Selecting a test

It is recommended that clinicians select and familiarise themselves with suitable SAP tests. Patients should be followed with the same test to facilitate estimation of

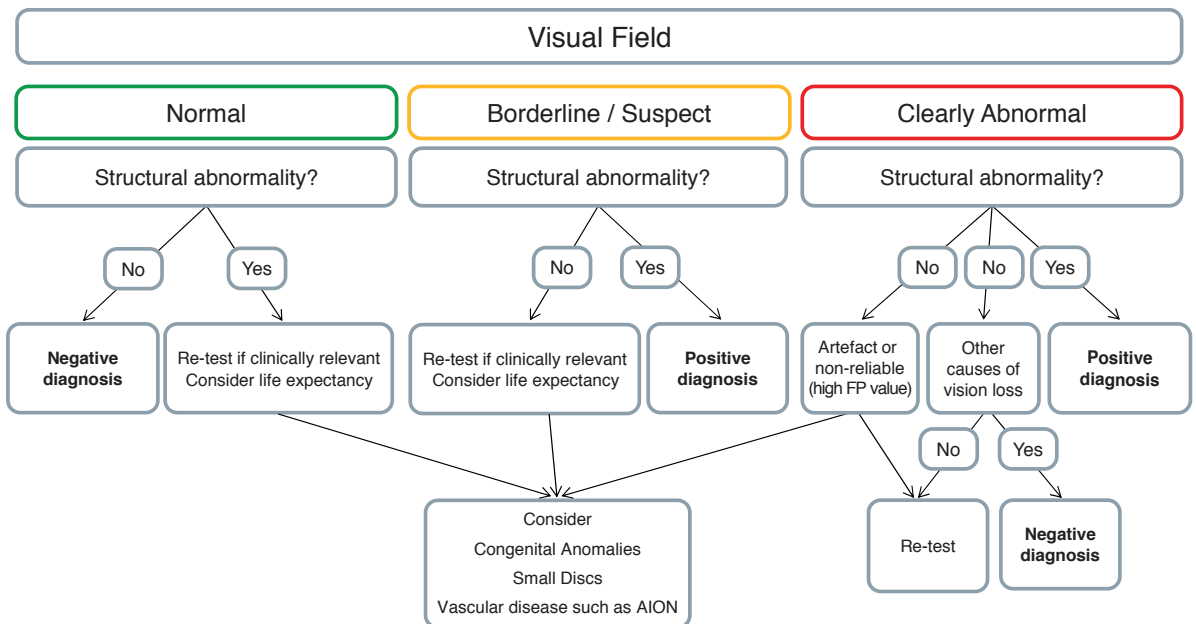
progression [I,D]. For those with very advanced disease it may be necessary to consider using a Goldmann size V stimulus rather than size III, or a perimetric strategy which focuses more closely on the remaining area of visual field. In both perimeters one may use test point patterns covering only the central 10° of the field in eyes which have only ‘tunnel’ fields left, e.g. the Octopus M1 or M2 or the Humphrey 10-2 [I,D].

The Humphrey Field Analyzer and the Octopus perimeter are the two most commonly used SAP perimeters in Europe. Other less frequently used SAP perimeters also having threshold programmes are available.

1.4.1.3 Non-conventional perimetry

Other modalities of computerised perimetry use different stimuli to SAP. Examples are SWAP (Short Wavelength Automated Perimetry), FDT (Frequency Doubling Technology), HEP (Heidelberg Edge Perimetry) and HRP (High-pass resolution perimetry or ring perimetry) and flicker perimetry. There is insufficient evidence that these tests offer any advantage over SAP¹²³⁻¹²⁶.

FC III - Initial Visual Field Evaluation



Consider the reliability of the test before making decisions based on it

1.4.1.4 Patient instructions

The role of the operator is of great importance. To patients who are naive to the test, the operator must explain what to expect and how to react to stimuli. The operator needs to be in the vicinity of the perimeter to react to any patient queries [I,D]. A quiet, dimly lit environment should be ensured. A short demonstration, before the actual test starts, will also help patients understand the test. The operator should have taken the tests to better understand the experience of taking the test. It should be explained that most stimuli will be very dim and even patients with normal visual fields will be expected to 'miss' many stimuli [II,D].

1.4.2 Interpreting test results

1.4.2.1 Printouts

Humphrey and Octopus both provide similar statistical analyses of single field test results presented on printouts containing maps of the visual field plus visual field indices and other means of interpreting a test result.

- The numerical threshold map provides the 'raw' estimated threshold values at each test point location.
- The grey scale or colour coded map provides a graphical representation of the numerical threshold map.
- The numerical total deviation map shows point-wise differences between the age-corrected normal threshold value at each test point location and the measured value.
- The numerical pattern deviation map shows the same values but after correction for diffuse loss of sensitivity. Thus, it highlights focal loss of sensitivity.
- Probability maps provide the statistical significance of the numerical deviations.

1.4.2.2 Reliability indices

These indices are meant to estimate patient reliability. With proper instructions almost all patients are able to perform reliable tests.

High frequencies of false positive answers (FP), are clearly a sign of poor reliability, but high frequencies of false negatives (FN) are of relatively little value. High rates of fixation losses (FL) may indicate poor attention to the fixation target. In most modern perimeters patients' fixation is continuously monitored during the test by an automatic eye/gaze tracker.

The operator has an important role in monitoring and assessing the reliability of the test as it is performed and informing the clinician e.g. by annotating the test result if necessary.

1.4.2.3 Visual field indices

Visual field indices are numbers summarising perimetric test results. An useful index is MD (mean defect in the Octopus system or mean deviation in the Humphrey system). MD represents the average difference between normal age-corrected sensitivity values and the measured threshold values at all test point locations. A new index developed for the Humphrey perimeter is VFI, which is similar to the MD value but more centrally weighted, expressed in percent rather than in decibels and more resistant to diffuse loss^{127, 128}.

The global indices include PSD (Humphrey) and LV (Octopus) measure the local spatial variability of the visual field. PSD and LV can be used for diagnosis, but they are less informative than the probability maps. Software to produce graphs mapping visual field loss to expected anatomical regions is available.

1.4.2.4 Recording the visual field indices

A simple method to record serial data from VF is the GSS; this will give a visual overview, without any statistical support^{129, 130}

1.4.2.5 Summarising diagnostic features

- The Glaucoma Hemifield Test (GHT)
The Glaucoma Hemifield Test is incorporated in the Humphrey perimeter. This analysis classifies results as 'within normal limits', 'outside normal limits' or 'borderline'. The classification of outside normal limits is designed to identify glaucoma. Two more GHT classifications are 'general depression of sensitivity' and 'abnormally high sensitivity which goes hand in hand with high frequencies of FP responses'.
- The Bebié curve
The Bebié curve or the cumulative defect curve in the Octopus system is a summary graph of localised and diffuse sensitivity loss. In entirely diffuse loss the curve of the measured sensitivities is lower than but parallel to the displayed normal curve. In focal loss the right part of the measured curve is depressed as compared to the normal reference curve.
- Diagnosis based on clustered points
Clustered test point locations with significantly reduced sensitivity are more reliable indicators of early glaucomatous field loss than scattered points. A rule, which is often used to classify a test result as glaucomatous, stipulates a minimum of three clustered points with significantly depressed sensitivity, of which one should have a significance of $p < 1\%$ [I,D]. Usually, the test point locations immediately surrounding the blind spot are ignored in this analysis.

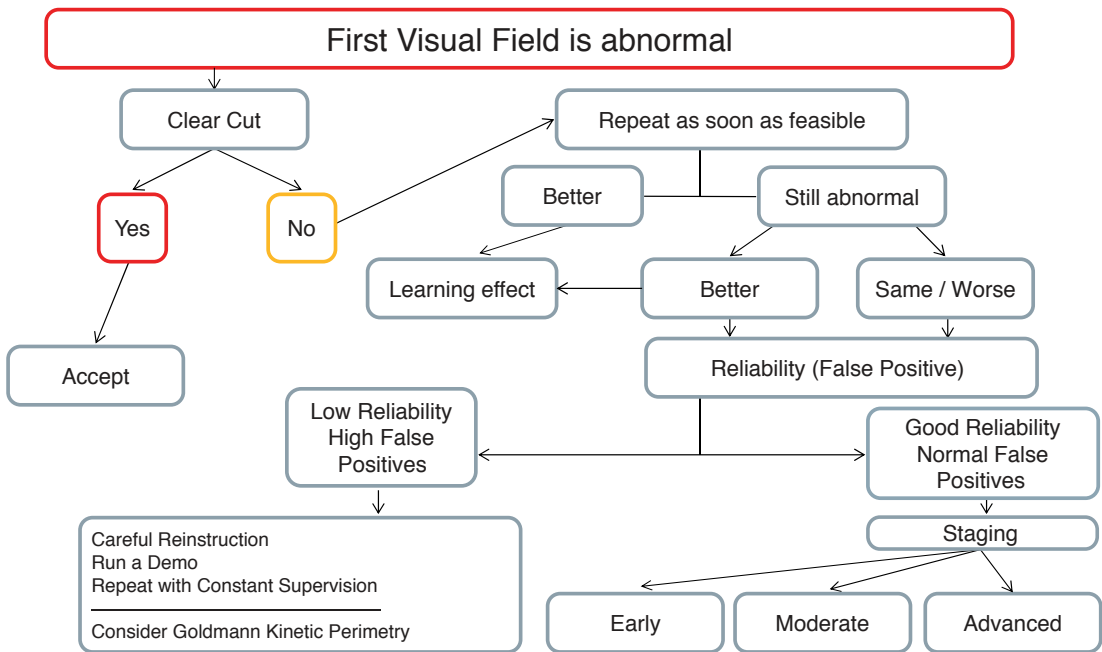
1.4.2.6 Confirmation of classification

Field defects which appear clearly glaucomatous and fit with the clinical picture may not need confirmation to support a diagnosis [I,D]. Visual fields with subtle defects may require confirmatory tests. (See FC IV).

The learning effect.

Many subjects show an improvement in performance reflected as improved reliability and sensitivity over the first few tests.

FC IV - Diagnostic strategy when initial visual field is abnormal



ALWAYS CONSIDER THE STATUS OF THE OPTIC NERVE

1.4.2.7 Assessing progression

In follow-up it is important to know whether the visual field of an eye is deteriorating and the rate of progression [I,D]. When assessing change from baseline, apparent progression needs to be confirmed in two or more tests [I,D].

There are two main approaches to computer-assisted progression analyses:

1. Event analyses (designed to answer the question of whether the field has progressed)
With Glaucoma Change Probability Maps (GCPMs) all visual field tests are compared to baseline consisting of an average of two baseline tests. Test point locations that have deteriorated more than the expected test-retest variation are flagged. Eyes that show deterioration of at least three test point locations are flagged as possibly progressing if the finding is repeated in two consecutive tests and likely progressing if existing in three consecutive tests. The rules used in EMGT¹³¹ are part of the HVF Analyser's guided progression analyses (GPA) program.
2. Trend analyses (quantify the rate of progression)
The perimetric rate of progression is the velocity of worsening of the visual field, and is usually measured by performing linear regression analysis of the MD index or the newer VFI index over time. With MD rate of progression is expressed in dB/year, and with VFI in %/year.
Trend analysis of global indices includes linear regression of MD and VFI for the Humphrey and linear regression of MD, LV, DD and LD for the Octopus. The Octopus provides trend analysis of functionally related clusters of test points. Several stand-alone software programs are available to perform trend analysis of individual test locations, clusters or global indices, depending on the product. These include Peridata, PROGRESSOR and Eye Suite. Some of the systems described above use trend data to try to predict the future status of the visual field.

1.4.2.8 Number of tests

Commonly used event and trend analyses require at least five and preferably more tests to detect progression. However in some cases progression may be detected before this. This demonstrates the need for relatively frequent perimetry in those eyes where it is considered necessary to find early progression.

Determining the rate of progression of an individual eye requires a long enough time span (at least two years) and enough field tests. It is important to identify eyes showing a fast rate of progression at an early stage. Ideally, all newly diagnosed glaucoma patients should be tested with SAP three times per year during the first two years after diagnosis [II,D].

1.4.3 Staging of Visual Field Defects

When discussing disease stages in glaucoma, the status of the visual field is often used as the most important reference. A discrete-levels staging system¹³², modified from the Hodapp-Parrish classification¹³³ has been in use for several years.

The GSS use a combination of MD and PSD to chart the stage of damage^{129, 130}.

Staging systems may be of great interest in scientific studies, cost studies *et cetera*, but they are of limited value in clinical management.

Ideally for glaucoma management one should be able to detect and quantify disease progression in small steps rather than identifying only the transition from one stage to the next [I,D].

The Hodapp Classification

EARLY GLAUCOMATOUS LOSS

- a) MD < -6 dB
- b) Fewer than 18 points depressed below the 5% probability level and fewer than 10 points below the p < 1% level
- c) No point in the central 5 degrees with a sensitivity of less than 15 dB

MODERATE GLAUCOMATOUS LOSS

- a) MD < -12 dB
- b) Fewer than 37 points depressed below the 5% probability level and fewer than 20 points below the p < 1% level
- c) No absolute deficit (0 dB) in the 5 central degrees
- d) Only one hemifield with sensitivity of < 15 dB in the 5 central degrees

ADVANCED GLAUCOMATOUS LOSS

- a) MD > -12 dB
- b) More than 37 points depressed below the 5% probability level or more than 20 points below the p < 1% level
- c) Absolute deficit (0 dB) in the 5 central degrees
- d) Sensitivity < 15 dB in the 5 central degrees in both hemifields

References:

1. Burr JM, Mowatt G, Hernandez R, et al. The clinical effectiveness and cost-effectiveness of screening for open angle glaucoma: a systematic review and economic evaluation. *Health Technol Assess* 2007;11(41):iii-iv, ix-x, 1-190.
2. Leydecker WA, K.; Neumann, H.G. The intraocular pressure of healthy eyes. *Klin Mbl Augenheilk* 1958(133):662-70.
3. Armaly MF. On the Distribution of Applanation Pressure. I. Statistical Features and the Effect of Age, Sex, and Family History of Glaucoma. *Arch Ophthalmol* 1965;73:11-8.
4. Davanger M, Ringvold A, Blika S, Elsas T. Frequency distribution of IOP. Analysis of a material using the gamma distribution. *Acta Ophthalmol (Copenh)* 1991;69(5):561-4.
5. Hollows FC, Graham PA. Intra-ocular pressure, glaucoma, and glaucoma suspects in a defined population. *Br J Ophthalmol* 1966;50(10):570-86.
6. Leibowitz HM, Krueger DE, Maunder LR, et al. The Framingham Eye Study monograph: An ophthalmological and epidemiological study of cataract, glaucoma, diabetic retinopathy, macular degeneration, and visual acuity in a general population of 2631 adults, 1973-1975. *Surv Ophthalmol* 1980;24(Suppl):335-610.
7. Klein BE, Klein R, Linton KL. Intraocular pressure in an American community. The Beaver Dam Eye Study. *Invest Ophthalmol Vis Sci* 1992;33(7):2224-8.
8. Bonomi L, Marchini G, Marraffa M, et al. Prevalence of glaucoma and intraocular pressure distribution in a defined population. The Egna-Neumarkt Study. *Ophthalmology* 1998;105(2):209-15.
9. Mitchell P, Smith W, Attebo K, Healey PR. Prevalence of open-angle glaucoma in Australia. The Blue Mountains Eye Study. *Ophthalmology* 1996;103(10):1661-9.
10. Sommer A, Tielsch JM, Katz J, et al. Relationship between intraocular pressure and primary open angle glaucoma among white and black Americans. The Baltimore Eye Survey. *Arch Ophthalmol* 1991;109(8):1090-5.
11. Goldmann H. Un nouveau tonometre d'applanation. *Bull Soc Ophthalmol Fr* 1955(67):474-8.
12. Cook JA, Botello AP, Elders A, et al. Systematic review of the agreement of tonometers with Goldmann applanation tonometry. *Ophthalmology* 2012;119(8):1552-7.
13. Kaufmann C, Bachmann LM, Thiel MA. Comparison of dynamic contour tonometry with goldmann applanation tonometry. *Invest Ophthalmol Vis Sci* 2004;45(9):3118-21.
14. Doyle A, Lachkar Y. Comparison of dynamic contour tonometry with Goldmann applanation tonometry over a wide range of central corneal thickness. *J Glaucoma* 2005;14(4):288-92.
15. Barleon L, Hoffmann EM, Berres M, et al. Comparison of dynamic contour tonometry and Goldmann applanation tonometry in glaucoma patients and healthy subjects. *Am J Ophthalmol* 2006;142(4):583-90.
16. Martinez-de-la-Casa JM, Garcia-Feijoo J, Vico E, et al. Effect of corneal thickness on dynamic contour, rebound, and Goldmann tonometry. *Ophthalmology* 2006;113(12):2156-62.
17. Halkiadakis I, Patsea E, Chatzimichali K, et al. Comparison of dynamic contour tonometry with Goldmann applanation tonometry in glaucoma practice. *Acta Ophthalmol* 2009;87(3):323-8.
18. Fogagnolo P, Figus M, Frezzotti P, et al. Test-retest variability of intraocular pressure and ocular pulse amplitude for dynamic contour tonometry: a multicentre study. *Br J Ophthalmol* 2010;94(4):419-23.

19. Tonnu PA, Ho T, Sharma K, et al. A comparison of four methods of tonometry: method agreement and interobserver variability. *Br J Ophthalmol* 2005;89(7):847-50.
20. Yaeoda K, Shirakashi M, Fukushima A, et al. Measurement of intraocular pressure using the NT-4000: a new non-contact tonometer equipped with pulse synchronous measurement function. *J Glaucoma* 2005;14(3):201-5.
21. Kotecha A, Elsheikh A, Roberts CR, et al. Corneal thickness- and age-related biomechanical properties of the cornea measured with the ocular response analyzer. *Invest Ophthalmol Vis Sci* 2006;47(12):5337-47.
22. Medeiros FA, Weinreb RN. Evaluation of the influence of corneal biomechanical properties on intraocular pressure measurements using the ocular response analyzer. *J Glaucoma* 2006;15(5):364-70.
23. Kotecha A, White E, Schlottmann PG, Garway-Heath DF. Intraocular pressure measurement precision with the Goldmann applanation, dynamic contour, and ocular response analyzer tonometers. *Ophthalmology* 2010;117(4):730-7.
24. Sullivan-Mee M, Gerhardt G, Halverson KD, Qualls C. Repeatability and reproducibility for intraocular pressure measurement by dynamic contour, ocular response analyzer, and Goldmann applanation tonometry. *J Glaucoma* 2009;18(9):666-73.
25. Vandewalle E, Vandenbroeck S, Stalmans I, Zeyen T. Comparison of ICare, dynamic contour tonometer, and ocular response analyzer with Goldmann applanation tonometer in patients with glaucoma. *Eur J Ophthalmol* 2009;19(5):783-9.
26. Sacu S, Vass C, Schemper M, Rainer G. Self-tonometry with the Ocuton S: evaluation of accuracy in glaucoma patients. *Acta Ophthalmol Scand* 2004;82(4):405-9.
27. Marchini G, Babighian S, Specchia L, Perfetti S. Evaluation of the new Ocuton S tonometer. *Acta Ophthalmol Scand* 2002;80(2):167-71.
28. Langham ME, McCarthy E. A rapid pneumatic applanation tonometer. Comparative findings and evaluation. *Arch Ophthalmol* 1968;79(4):389-99.
29. Morrison JC, Pollack IP. *Glaucoma: science and practice*. New York: Thieme Medical Publishing, 2003; 544.
30. Quigley HA, Langham ME. Comparative intraocular pressure measurements with the pneumatonograph and Goldmann tonometer. *Am J Ophthalmol* 1975;80(2):266-73.
31. Nakamura M, Darhad U, Tatsumi Y, et al. Agreement of rebound tonometer in measuring intraocular pressure with three types of applanation tonometers. *Am J Ophthalmol* 2006;142(2):332-4.
32. Brusini P, Salvetat ML, Zeppieri M, et al. Comparison of ICare tonometer with Goldmann applanation tonometer in glaucoma patients. *J Glaucoma* 2006;15(3):213-7.
33. Ruokonen PC, Schwentek T, Draeger J. Evaluation of the impedance tonometers TGDc-01 and iCare according to the international ocular tonometer standards ISO 8612. *Graefes Arch Clin Exp Ophthalmol* 2007;245(9):1259-65.
34. Martinez-de-la-Casa JM, Garcia-Feijoo J, Castillo A, Garcia-Sanchez J. Reproducibility and clinical evaluation of rebound tonometry. *Invest Ophthalmol Vis Sci* 2005;46(12):4578-80.
35. Johannesson G, Hallberg P, Eklund A, Linden C. Pascal, ICare and Goldmann applanation tonometry a comparative study. *Acta Ophthalmol* 2008;86(6):614-21.
36. Bandyopadhyay M, Raychaudhuri A, Lahiri SK, et al. Comparison of Goldmann applanation tonometry with the Tonopen for measuring intraocular pressure in a population-based glaucoma survey in rural West Bengal. *Ophthalmic Epidemiol* 2002;9(3):215-24.

37. Horowitz GS, Byles J, Lee J, D'Este C. Comparison of the Tono-Pen and Goldmann tonometer for measuring intraocular pressure in patients with glaucoma. *Clin Experiment Ophthalmol* 2004;32(6):584-9.
38. Salvetat ML, Zeppieri M, Tosoni C, Brusini P. Comparisons between Pascal dynamic contour tonometry, the TonoPen, and Goldmann applanation tonometry in patients with glaucoma. *Acta Ophthalmol Scand* 2007;85(3):272-9.
39. Rai S, Moster MR, Kesen M, et al. Level of disagreement between Proview phosphene tonometer and Goldmann applanation tonometer intraocular pressure readings. *J Glaucoma* 2005;14(2):120-3.
40. Brigatti L, Maguluri S. Reproducibility of self-measured intraocular pressure with the phosphene tonometer in patients with ocular hypertension and early to advanced glaucoma. *J Glaucoma* 2005;14(1):36-9.
41. Troost A, Specht K, Krummenauer F, et al. Deviations between transpalpebral tonometry using TGDC-01 and Goldmann applanation tonometry depending on the IOP level. *Graefes Arch Clin Exp Ophthalmol* 2005;243(9):853-8.
42. Lam DS, Leung DY, Chiu TY, et al. Pressure phosphene self-tonometry: a comparison with Goldmann tonometry in glaucoma patients. *Invest Ophthalmol Vis Sci* 2004;45(9):3131-6.
43. Rietveld E, van den Bremer DA, Volker-Dieben HJ. Clinical evaluation of the pressure phosphene tonometer in patients with glaucoma. *Br J Ophthalmol* 2005;89(5):537-9.
44. Holló G, Kóthy P, Vargha, P. Evaluation of continuous 24-hour intraocular pressure monitoring for assessment of prostaglandin induced pressure reduction in glaucoma. *J Glaucoma* 2014 Jan;23(1):e6-12.
45. Rahman ML, Bunce C, Healey PR, et al. Commingling analyses of central corneal thickness and adjusted intraocular pressure in an older Australian population. *Invest Ophthalmol Vis Sci* 2010;51(5):2512-8.
46. Duch S, Serra A, Castanera J, et al. Tonometry after laser in situ keratomileusis treatment. *J Glaucoma* 2001;10(4):261-5.
47. Palmerg P. Gonioscopy in: Ritch R, Shields MB, Krupin T, eds. *The glaucomas*. St Louis: CV Mosby1996; 455-69.
48. Spaeth GL. The normal development of the human anterior chamber angle: a new system of descriptive grading. *Trans Ophthalmol Soc U K* 1971;91:709-39.
49. Alward W. *Color atlas of gonioscopy*. London, Mosby1994.
50. Forbes M. Gonioscopy with corneal indentation. A method for distinguishing between appositional closure and synechial closure. *Arch Ophthalmol* 1966;76(4):488-92.
51. See JL, Chew PT, Smith SD, et al. Changes in anterior segment morphology in response to illumination and after laser iridotomy in Asian eyes: an anterior segment OCT study. *Br J Ophthalmol* 2007;91(11):1485-9.
52. Leung CK, Cheung CY, Li H, et al. Dynamic analysis of dark-light changes of the anterior chamber angle with anterior segment OCT. *Invest Ophthalmol Vis Sci* 2007;48(9):4116-22.
53. Denis P, Charpentier D, Berros P, Touameur S. Bilateral acute angle-closure glaucoma after dexfenfluramine treatment. *Ophthalmologica* 1995;209(4):223-4.
54. Quigley HA. The Iris Is a Sponge: A Cause of Angle Closure. *Ophthalmology* 2010;117(1):1-2.
55. Lachkar Y, Bouassida W. Drug-induced acute angle closure glaucoma. *Curr Opin Ophthalmol* 2007;18(2):129-33.
56. Kolker AE, Hetherington JTB-Ssd, therapy of the glaucomas. St Louis: CV Mosby. 1995.

57. Scheie HG. Width and pigmentation of the angle of the anterior chamber; a system of grading by gonioscopy. *AMA Arch Ophthalmol* 1957;58(4):510-2.
58. Shaffer RN. Gonioscopy anatomy of the angle of the anterior chamber of the eye. In) SRe, ed. In: *Stereoscopic manual of gonioscopy*. St. Louis, Mosby 1962.
59. Kanski JS, M. Glaukom. In: Kanski J. SMe, ed. In: *Lehrbuch der klinischen Ophthalmologie*. Stuttgart, New York Thieme, 1987.
60. Congdon NG, Spaeth GL, Augsburger J, et al. A proposed simple method for measurement in the anterior chamber angle: biometric gonioscopy. *Ophthalmology* 1999;106(11):2161-7.
61. Kalev-Landoy M, Day AC, Cordeiro MF, Migdal C. Optical coherence tomography in anterior segment imaging. *Acta Ophthalmol Scand* 2007;85(4):427-30.
62. Nolan W. Anterior segment imaging: identifying the landmarks. *Br J Ophthalmol* 2008;92(12):1575-6.
63. Wolffsohn JS, Davies LN. Advances in anterior segment imaging. *Curr Opin Ophthalmol* 2007;18(1):32-8.
64. Sakata LM, Lavanya R, Friedman DS, et al. Comparison of gonioscopy and anterior segment ocular coherence tomography in detecting angle closure in different quadrants of the anterior chamber angle. *Ophthalmology* 2008;115(5):769-74.
65. Dada T, Sihota R, Gadia R, et al. Comparison of anterior segment optical coherence tomography and ultrasound biomicroscopy for assessment of the anterior segment. *J Cataract Refract Surg* 2007;33(5):837-40.
66. Rabsilber TM, Khoramnia R, Auffarth GU. Anterior chamber measurements using Pentacam rotating Scheimpflug camera. *J Cataract Refract Surg* 2006;32(3):456-9.
67. Shukla S, Damji KF, Harasymowycz P, et al. Clinical features distinguishing angle closure from pseudoplateau versus plateau iris. *Br J Ophthalmol* 2008;92(3):340-4.
68. Friedman DS, Gazzard G, Min CB, et al. Age and sex variation in angle findings among normal Chinese subjects: a comparison of UBM, Scheimpflug, and gonioscopic assessment of the anterior chamber angle. *J Glaucoma* 2008;17(1):5-10.
69. Aptel F, Chiquet C, Beccat S, Denis P. Biometric evaluation of anterior chamber changes after physiologic pupil dilation using Pentacam and anterior segment optical coherence tomography. *Invest Ophthalmol Vis Sci* 2012;53(7):4005-10.
70. Tzamalīs A, Pham DT, Wirbelauer C. Comparison of slit lamp-adapted optical coherence tomography features of fellow eyes of acute primary angle closure and eyes with open angle glaucoma. *Jpn J Ophthalmol* 2014.
71. Sng CC, Aquino MC, Liao J, et al. Pretreatment anterior segment imaging during acute primary angle closure: insights into angle closure mechanisms in the acute phase. *Ophthalmology* 2014;121(1):119-25.
72. Theelen T, Hoyng CB. A prospective, comparative, observational study on optical coherence tomography of the anterior eye segment. *Ophthalmologica* 2013;230(4):222-6.
73. Smith SD, Singh K, Lin SC, et al. Evaluation of the anterior chamber angle in glaucoma: a report by the american academy of ophthalmology. *Ophthalmology* 2013;120(10):1985-97.
74. Mak H, Xu G, Leung CK. Imaging the iris with swept-source optical coherence tomography: relationship between iris volume and primary angle closure. *Ophthalmology* 2013;120(12):2517-24.
75. Mishima K, Tomidokoro A, Suramethakul P, et al. Iridotrabeular contact observed

- using anterior segment three-dimensional OCT in eyes with a shallow peripheral anterior chamber. *Invest Ophthalmol Vis Sci* 2013;54(7):4628-35.
76. McKee H, Ye C, Yu M, et al. Anterior chamber angle imaging with swept-source optical coherence tomography: detecting the scleral spur, Schwalbe's Line, and Schlemm's Canal. *J Glaucoma* 2013;22(6):468-72.
 77. Matonti F, Chazalon E, Trichet E, et al. Dynamic gonioscopy using optical coherence tomography. *Ophthalmic Surg Lasers Imaging* 2012;43(6 Suppl):S90-6.
 78. Day AC, Garway-Heath DF, Broadway DC, et al. Spectral domain optical coherence tomography imaging of the aqueous outflow structures in normal participants of the EPIC-Norfolk Eye Study. *Br J Ophthalmol* 2013;97(2):189-95.
 79. Shabana N, Aquino MC, See J, et al. Quantitative evaluation of anterior chamber parameters using anterior segment optical coherence tomography in primary angle closure mechanisms. *Clin Experiment Ophthalmol* 2012;40(8):792-801.
 80. Sng CC, Foo LL, Cheng CY, et al. Determinants of anterior chamber depth: the Singapore Chinese Eye Study. *Ophthalmology* 2012;119(6):1143-50.
 81. Liu S, Yu M, Ye C, et al. Anterior chamber angle imaging with swept-source optical coherence tomography: an investigation on variability of angle measurement. *Invest Ophthalmol Vis Sci* 2011;52(12):8598-603.
 82. Lee KS, Sung KR, Kang SY, et al. Residual anterior chamber angle closure in narrow-angle eyes following laser peripheral iridotomy: anterior segment optical coherence tomography quantitative study. *Jpn J Ophthalmol* 2011;55(3):213-9.
 83. Fukuda S, Kawana K, Yasuno Y, Oshika T. Repeatability and reproducibility of anterior chamber volume measurements using 3-dimensional corneal and anterior segment optical coherence tomography. *J Cataract Refract Surg* 2011;37(3):461-8.
 84. Ursea R, Silverman RH. Anterior-segment imaging for assessment of glaucoma. *Expert Rev Ophthalmol* 2010;5(1):59-74.
 85. Dinc UA, Gorgun E, Oncel B, et al. Assessment of anterior chamber depth using Visante optical coherence tomography, slitlamp optical coherence tomography, IOL Master, Pentacam and Orbscan IIz. *Ophthalmologica* 2010;224(6):341-6.
 86. Pekmezci M, Porco TC, Lin SC. Anterior segment optical coherence tomography as a screening tool for the assessment of the anterior segment angle. *Ophthalmic Surg Lasers Imaging* 2009;40(4):389-98.
 87. See JL. Imaging of the anterior segment in glaucoma. *Clin Experiment Ophthalmol* 2009;37(5):506-13.
 88. Liu S, Li H, Dorairaj S, et al. Assessment of scleral spur visibility with anterior segment optical coherence tomography. *J Glaucoma* 2010;19(2):132-5.
 89. Yip LW, Sothornwit N, Berkowitz J, Mikelberg FS. A comparison of interocular differences in patients with pigment dispersion syndrome. *J Glaucoma* 2009;18(1):1-5.
 90. Jonas JB, Gusek GC, Naumann GO. Optic disc morphometry in chronic primary open-angle glaucoma. I. Morphometric intrapapillary characteristics. *Graefes Arch Clin Exp Ophthalmol* 1988;226(6):522-30.
 91. Tuulonen A, Airaksinen PJ. Initial glaucomatous optic disk and retinal nerve fiber layer abnormalities and their progression. *Am J Ophthalmol* 1991;111(4):485-90.
 92. Pederson JE, Anderson DR. The mode of progressive disc cupping in ocular hypertension and glaucoma. *Arch Ophthalmol* 1980;98(3):490-5.
 93. Zeyen TG, Caprioli J. Progression of disc and field damage in early glaucoma. *Arch Ophthalmol* 1993;111(1):62-5.

94. Spaeth GL. Development of glaucomatous changes of the optic nerve. In: (eds) PK, ed. Varma, R, Spaeth, GL: The optic nerve in glaucoma. Philadelphia: J.B. Lippincott, 1993.
95. Airaksinen PJ, Tuulonen A, Alanko HI. Rate and pattern of neuroretinal rim area decrease in ocular hypertension and glaucoma. *Arch Ophthalmol* 1992;110(2):206-10.
96. Hoyt WF, Frisen L, Newman NM. Fundoscopy of nerve fiber layer defects in glaucoma. *Invest Ophthalmol* 1973;12(11):814-29.
97. Jonas JB, Nguyen NX, Naumann GO. The retinal nerve fiber layer in normal eyes. *Ophthalmology* 1989;96(5):627-32.
98. Airaksinen PJ, Drance SM, Douglas GR, et al. Visual field and retinal nerve fiber layer comparisons in glaucoma. *Arch Ophthalmol* 1985;103(2):205-7.
99. Healey PR, Mitchell P, Smith W, Wang JJ. Optic disc hemorrhages in a population with and without signs of glaucoma. *Ophthalmology* 1998;105(2):216-23.
100. Budenz DL, Anderson DR, Feuer WJ, et al. Detection and prognostic significance of optic disc hemorrhages during the Ocular Hypertension Treatment Study. *Ophthalmology* 2006;113(12):2137-43.
101. Leske MC, Heijl A, Hyman L, et al. Predictors of long-term progression in the early manifest glaucoma trial. *Ophthalmology* 2007;114(11):1965-72.
102. Uhler TA, Piltz-Seymour J. Optic disc hemorrhages in glaucoma and ocular hypertension: implications and recommendations. *Curr Opin Ophthalmol* 2008;19(2):89-94.
103. Bengtsson B, Leske MC, Yang Z, Heijl A. Disc hemorrhages and treatment in the early manifest glaucoma trial. *Ophthalmology* 2008;115(11):2044-8.
104. Jonas JB, Nguyen XN, Gusek GC, Naumann GO. Parapapillary chorioretinal atrophy in normal and glaucoma eyes. I. Morphometric data. *Invest Ophthalmol Vis Sci* 1989;30(5):908-18.
105. Teng CC, De Moraes CG, Prata TS, et al. Beta-Zone parapapillary atrophy and the velocity of glaucoma progression. *Ophthalmology* 2010;117(5):909-15.
106. Teng CC, De Moraes CG, Prata TS, et al. The region of largest beta-zone parapapillary atrophy area predicts the location of most rapid visual field progression. *Ophthalmology* 2011;118(12):2409-13.
107. See JL, Nicolela MT, Chauhan BC. Rates of neuroretinal rim and peripapillary atrophy area change: a comparative study of glaucoma patients and normal controls. *Ophthalmology* 2009;116(5):840-7.
108. Jonas JB, Gusek GC, Naumann GO. Optic disc, cup and neuroretinal rim size, configuration and correlations in normal eyes. *Invest Ophthalmol Vis Sci* 1988;29(7):1151-8.
109. Healey PR, Mitchell P, Smith W, Wang JJ. Relationship between cup-disc ratio and optic disc diameter: the Blue Mountains Eye Study. *Aust N Z J Ophthalmol* 1997;25 Suppl 1:S99-101.
110. Heijl A, Molder H. Optic disc diameter influences the ability to detect glaucomatous disc damage. *Acta Ophthalmol (Copenh)* 1993;71(1):122-9.
111. Medeiros FA, Zangwill LM, Bowd C, Weinreb RN. Comparison of the GDx VCC scanning laser polarimeter, HRT II confocal scanning laser ophthalmoscope, and stratus OCT optical coherence tomograph for the detection of glaucoma. *Arch Ophthalmol* 2004;122(6):827-37.
112. Strouthidis NG, Scott A, Peter NM, Garway-Heath DF. Optic disc and visual field progression in ocular hypertensive subjects: detection rates, specificity, and agreement. *Invest Ophthalmol Vis Sci* 2006;47(7):2904-10.
113. Leung CK, Liu S, Weinreb RN, et al. Evaluation of retinal nerve fiber layer progression in glaucoma a prospective analysis with neuroretinal rim and visual field progression. *Ophthalmology* 2011;118(8):1551-7.

114. Wollstein G, Garway-Heath DF, Fontana L, Hitchings RA. Identifying early glaucomatous changes. Comparison between expert clinical assessment of optic disc photographs and confocal scanning ophthalmoscopy. *Ophthalmology* 2000;107(12):2272-7.
115. Strouthidis NG, Garway-Heath DF. New developments in Heidelberg retina tomograph for glaucoma. *Curr Opin Ophthalmol* 2008;19(2):141-8.
116. Oddone F, Centofanti M, Rossetti L, et al. Exploring the Heidelberg Retinal Tomograph 3 diagnostic accuracy across disc sizes and glaucoma stages: a multicenter study. *Ophthalmology* 2008;115(8):1358-65, 65 e1-3.
117. Mai TA, Reus NJ, Lemij HG. Diagnostic accuracy of scanning laser polarimetry with enhanced versus variable corneal compensation. *Ophthalmology* 2007;114(11):1988-93.
118. Leung CK, Yu M, Weinreb RN, et al. Retinal nerve fiber layer imaging with spectral-domain optical coherence tomography: patterns of retinal nerve fiber layer progression. *Ophthalmology* 2012;119(9):1858-66.
119. Sung KR, Sun JH, Na JH, et al. Progression detection capability of macular thickness in advanced glaucomatous eyes. *Ophthalmology* 2012;119(2):308-13.
120. Araie M. Test-retest variability in structural parameters measured with glaucoma imaging devices. *Jpn J Ophthalmol* 2013;57(1):1-24.
121. Aulhorn EH, H. Early visual field defects in glaucoma. In: Leydhecker W, ed. *Glaucoma Tutzing Symposium*. Basel, Switzerland 1966.
122. Morales J, Weitzman ML, Gonzalez de la Rosa M. Comparison between Tendency-Oriented Perimetry (TOP) and octopus threshold perimetry. *Ophthalmology* 2000;107(1):134-42.
123. Shah NN, Bowd C, Medeiros FA, et al. Combining structural and functional testing for detection of glaucoma. *Ophthalmology* 2006;113(9):1593-602.
124. Sample PA, Medeiros FA, Racette L, et al. Identifying glaucomatous vision loss with visual-function-specific perimetry in the diagnostic innovations in glaucoma study. *Invest Ophthalmol Vis Sci* 2006;47(8):3381-9.
125. Tribble JR, Schultz RO, Robinson JC, Rothe TL. Accuracy of glaucoma detection with frequency-doubling perimetry. *Am J Ophthalmol* 2000;129(6):740-5.
126. van der Schoot J, Reus NJ, Colen TP, Lemij HG. The ability of short-wavelength automated perimetry to predict conversion to glaucoma. *Ophthalmology* 2010;117(1):30-4.
127. Bengtsson B, Heijl A. A visual field index for calculation of glaucoma rate of progression. *Am J Ophthalmol* 2008;145(2):343-53.
128. Chauhan BC, Garway-Heath DF, Goni FJ, et al. Practical recommendations for measuring rates of visual field change in glaucoma. *Br J Ophthalmol* 2008;92(4):569-73.
129. Brusini P, Filacorda S. Enhanced Glaucoma Staging System (GSS 2) for classifying functional damage in glaucoma. *J Glaucoma* 2006;15(1):40-6.
130. Ng M, Sample PA, Pascual JP, et al. Comparison of visual field severity classification systems for glaucoma. *J Glaucoma* 2012;21(8):551-61.
131. Leske MC, Heijl A, Hyman L, Bengtsson B. Early Manifest Glaucoma Trial: design and baseline data. *Ophthalmology* 1999;106(11):2144-53.
132. Mills RP, Budenz DL, Lee PP, et al. Categorizing the stage of glaucoma from pre-diagnosis to end-stage disease. *Am J Ophthalmol* 2006;141(1):24-30.
133. Hodapp E, Parrish RKL, Anderson DR. *Clinical decisions in glaucoma*. St Louis: The CV Mosby Co, 1993.



CHAPTER 2

Classification and Terminology

Classification and Terminology

2

2.1 - PRIMARY CONGENITAL FORMS/CHILDHOOD GLAUCOMAS

Primary congenital glaucoma is a rare disease but has a major impact on the child's development and quality of life over his/her whole life span. Early diagnosis and appropriate therapy can make a huge difference in the visual outcome and can prevent lifelong disability. Surgical treatment is always necessary^{1,2} [I,C].

2.1.1 Primary congenital glaucoma (PCG): from birth to >2 years of life

- (1) Neonatal or newborn onset (0-1 month)
- (2) Infantile onset (>1 until 24 months)
- (3) Late onset or late recognized (>2 years)
- (4) Spontaneously non-progressing cases with normal IOP but typical signs of PCG may be classified as PCG

Etiology:

Angle dysgenesis is caused by incomplete development of the trabecular meshwork before and/or after birth. Strong monogenetic influence. Heredity shows recessive inheritance with variable penetrance in most cases or is sporadic. Specific chromosomal abnormalities have been identified at chromosomes 1p36 and 2q21².

Pathogenic mechanism:

Decreased aqueous outflow causes significant elevation of IOP. Isolated trabeculodysgenesis is the most common form of primary congenital glaucoma.

Epidemiology:

Congenital glaucoma occurs in about 1 in 12-18,000 births among Caucasians. Incidence can be 5 to 10 times higher if consanguinity of parents is present. Severe visual disability is common. PCG is more common in males (65%), and is bilateral in 70% of patients.

Symptoms:

Crying unhappy child during first weeks or year of life.
Not always symptomatic.

Signs:

Photophobia, tearing, blepharospasm, and eye rubbing are typical early signs. Eyes are larger compared to age, with corneal diameter usually >10.5 mm at birth and >12 mm in the first year of life. Axial length is increased, >20 mm at birth or >22 mm after 1 year. Corneal oedema is frequent; epithelial and stromal oedema can be associated with ruptures of Descemet's Membrane, or Haab's striae, not to be confused with forceps delivery trauma.

IOP can sometimes be measured in the awaked child with hand-held tonometers. Under general anesthesia the level of IOP is often artificially lowered by sedation and anesthetic medications: IOP values alone are insufficient to confirm the diagnosis unless IOP is extremely elevated and confirmed by corneal signs. Severe cases show

extremely extended globe when the diagnosis is delayed, described as “buphthalmos” (Ox eye). A useful approach is to compare the width of the palpebral apertures.

The optic nerve head shows pressure distension or uniform cup enlargement in newborns; cupping is a typical signs for later stages (CDR >0.3). Optic disc signs may be reversible with the normalization of IOP.

Gonioscopy shows anterior insertion of the iris, forming a scalloped line with persistent uveal tissue and poorly differentiated structures and/or trabeculodysgenesis often described as Barkan’s “membrane”.

Treatment:

Initial surgery is indicated in nearly all cases with primary congenital glaucoma ²⁻⁵ [I,D]. Classical initial surgery is goniotomy or trabeculotomy^{1, 6-8}. 360° trabeculotomy using a catheter to open the whole circumference of Schlemm’s canal has been described with favourable results⁹⁻¹¹. Filtration surgery may be indicated if these are unsuccessful [I,D]. Repeat surgery is relatively frequent.

Medical treatment is usually neither effective nor practicable in the long term. Medications, including oral CAIs can be used while decision is made on a surgical approach and for eyes where surgery fails to achieve IOP control.² Cycloablation is an intermediate or add-on procedure when primary trabecular surgery has failed. Severe cases and secondary childhood glaucomas, particularly aphakic childhood glaucoma, sometimes need long-tube drainage device surgery.

Cases with later manifestation usually do not have enlargement of the globe and may have a more favourable outcome with surgery.

2.1.2 Late-onset childhood open-angle glaucoma/Early Juvenile (onset >2 to puberty)

Etiology and pathophysiology:

as in PCG, except :

- no ocular enlargement
- no congenital ocular anomalies or syndromes
- asymptomatic until field loss advanced

Signs:

open angle, elevated IOP, optic nerve and visual field damage depending on the stage of disease

Treatment:

See above 2.1.1.1

The treatment of pediatric glaucoma cases is particularly challenging due to the nature of the disease and to the intrinsic difficulties in operating them and in examining patients of this age. Treatment is to be adapted to the primary anomaly, and the mechanism of IOP elevation [I,D]. Whenever possible these cases should be referred to tertiary care centers.

2.1.3 Secondary Childhood Glaucoma

A variety of pathogenetic mechanisms are possible. A complete list and extensive discussion are outside the scope of the guidelines.

2.1.3.1 Glaucoma associated with non-acquired ocular anomalies

- Axenfeld Rieger anomaly (Syndrome if systemic associations)
- Peters anomaly (Syndrome if systemic associations)
- Ectropion uveae
- Congenital iris hypoplasia
- Aniridia
- Persistent fetal vasculature/PFV (if glaucoma present before cataract surgery)
- Oculodermal melanocytosis (Nevus of Ota)
- Posterior polymorphous dystrophy
- Microphthalmos
- Microcornea
- Ectopia lentis

2.1.3.2 Glaucoma Associated with Non-acquired Systemic Disease or Syndrome

- Chromosomal disorders such as Trisomy 21 (Down syndrome)
- Connective tissue disorders
 - Marfan syndrome
 - Weill-Marchesani syndrome
 - Stickler syndrome
- Metabolic disorders
 - Homocysteinuria
 - Lowe syndrome
 - Mucopolysaccharidoses
- Phacomatoses
 - Neurofibromatosis (NF-1, NF-2)
 - Sturge-Weber syndrome
 - Klippel-Trenaunay-Weber syndrome
 - Rubinstein-Taybi
 - Congenital rubella

2.1.3.3 Glaucoma Associated with Acquired Condition

- Uveitis
- Trauma (hyphema, angle recession, ectopialentis)
- Steroid induced
- Tumors (benign/malignant, ocular/orbital)
- Retinopathy of Prematurity

2.1.3.4 Glaucoma Following Childhood Cataract Surgery

Secondary glaucoma is a frequent serious complication after cataract surgery in early infancy. The incidence may increase up to 50% if cataract surgery is performed before the 9th month of life^{12, 13}. This secondary glaucoma is difficult to treat and often needs long-tube drainage device surgery for long-term IOP control.

2.1.3.5 Treatment of secondary childhood glaucoma [I,D]

The management of these cases is particularly challenging. Medical treatment is usually not effective nor practicable in long term. Medications, including oral CAs can be used while decision is made on a surgical approach and in case of failed surgery while awaiting for further options. Primary surgery: early goniotomy or trabeculotomy or filtration surgery may be indicated if these are unsuccessful. Repeat surgery is relatively frequent. Treatment to be adapted to the primary anomaly, the mechanism of IOP elevation and the quality of life of the patient. These cases require highly specialized care.

2.2 - PRIMARY OPEN-ANGLE GLAUCOMAS

The open-angle glaucomas are chronic, progressive optic neuropathies, that have in common characteristic morphological changes at the optic nerve head and retinal nerve fibre layer in the absence of other ocular disease or congenital anomalies. Progressive retinal ganglion cells death and visual field loss are associated with these changes.

2.2.1 Epidemiology

Glaucoma is the second leading cause of blindness both in Europe and worldwide. It is the most frequent cause of irreversible blindness. POAG is unusual under the age of 50 yrs. Its prevalence increases with age¹⁴⁻²⁵. However, the reported percentage largely depends on definition.

2.2.2 Risk factors for open-angle glaucoma

As most population studies did not differentiate between POAG and secondary open angle glaucomas such as pseudoexfoliation (PEX) glaucoma, the following statements apply to both varieties, here are labelled OAG.

- **Risk assessment**

Consideration of risk factors is important: it helps to identify individuals who can be targeted for early detection and to guide management decisions about the initiation and escalation of treatment in established glaucoma patients.

- **Terminology**

Risk Factors: risk factors for open-angle glaucoma (OAG) are those statistically associated with the development of OAG or conversion from ocular hypertension to glaucoma²⁶.

Prognostic Factors: prognostic factors for OAG are statistically associated with the progression of established OAG. Neither risk factors nor prognostic factors establish causation. Sometimes the terms risk factors and prognostic factors are used interchangeably.

Predictive Factors: the term predictive factors should be used for factors which are associated with increased risk for glaucoma and which are part of the definition of OAG, such as optic disc parameters and visual field indices.

2.2.2.1 Risk factors for the development of OAG (See FC V)

Initial evidence on potential risk factors for OAG has been provided by cross-sectional population-based studies. Firm conclusions on risk factors for the development of OAG can only be drawn by longitudinal population-based cohort studies²⁷⁻³⁰.

a) **Age**

Cross-sectional population-based studies have consistently reported that the prevalence of OAG increases dramatically with age^{14-17,19-25,31}. Longitudinal population-based studies have confirmed that older age is an important risk factor for OAG²⁷⁻³⁰. Two studies reported a 6% and 4% increased risk per year of age at baseline of developing OAG.

b) **Intraocular pressure (IOP)**

Higher IOP has been consistently associated with the prevalence^{14-17,19-25,31} and incidence of OAG^{27,28,30,32}. According to longitudinal data, the risk of developing OAG increases by 11-12% in Caucasians^{27,28}, 10% in people of African origin³² and 18% in Latinos³⁰ for each 1 mmHg increase in IOP. To date, IOP is the only modifiable risk factor for OAG.

c) **Race/ethnicity**

The prevalence of glaucoma is several times higher in African-Americans and Afro-Caribbeans than in Caucasians^{18,33,34}. In Latinos, it has been shown that the prevalence²⁰⁻²³ and incidence³⁵ of OAG is higher than in Caucasians, but lower than in Afro-Caribbeans.

d) **Family history of glaucoma**

Two studies studying different ethnic groups found that the risk of having OAG was 9.2-fold and 4 fold higher, respectively for individuals having a first-degree relative with confirmed OAG, compared with those who did not^{36, 37}. Also, self-reported family history of glaucoma has been associated with increased risk of developing OAG^{27,29}.

e) **Pseudoexfoliation**

Population-based studies which specifically assessed pseudoexfoliation and pseudoexfoliative glaucoma have consistently reported that pseudoexfoliation is associated with increased prevalence of OAG^{19,24,38-47}. Based on longitudinal data, the presence of pseudoexfoliation is associated with an 11.2-fold increased risk of developing OAG²⁷.

f) **Central corneal thickness (CCT)**

In two population based studies, there was a 41% and 30% increased risk of developing OAG per 40 μ m thinner CCT^{29,48}.

g) **Myopia**

Several cross-sectional population-based studies identified moderate to high myopia (greater than -3 diopters) as a factor associated with increased OAG

prevalence^{47,49-55}. A Dutch study showed that subjects with high myopia (greater than -4 D) had a 2.3-fold increased risk for developing OAG²⁸. Latinos in California had a risk of OAG increased by 48% with each 1 mm increase in axial length³⁰.

h) **Ocular perfusion pressure**

The association of low ocular perfusion pressure with increased OAG prevalence has been a consistent finding in population-based studies^{20,31, 56-61}. Recent evidence suggests that this association may depend on whether subjects are treated for systemic hypertension or not^{29,56,58,61-66}.

A phenotype characterized by vascular dysregulation has been described⁶⁴. The Barbados Eye Study confirmed that low ocular perfusion pressure increases the risk for the development of OAG²⁹.

Because of our limited understanding of this complex variable and of its interaction with potential risk factors for glaucoma, the exact place of ocular perfusion pressure in glaucoma management remains unclear⁶⁷⁻⁶⁹.

i) **Other factors**

There have been reports on other factors that may be associated with increased risk for OAG, such as diabetes, systemic blood pressure, migraine, Raynaud syndrome and obstructive sleep apnoea. However, data from the literature are inconsistent.

j) **Risk factors by type of OAG**

In general, population-based studies analyses have not differentiated between types of OAG. A recent analysis which considered POAG and PEX glaucoma revealed that IOP was the only factor associated with both of them; vascular systemic diseases and their treatment were associated only with POAG⁴⁷. This may suggest differences in pathogenesis between these two common types of OAG.

2.2.2.2 Risk factors and predictive factors for the conversion of ocular hypertension to POAG

The Ocular Hypertension Treatment Study (OHTS), and the European Glaucoma Prevention Study (EGPS)⁷⁰ are two randomized controlled trials (RCTs) which evaluated the effect of IOP-lowering treatment on the conversion of ocular hypertension to POAG. The following risk factors and predictive factors were consistently reported in both the OHTS and the EGPS:

- Age (risk increased by 26% per decade)
- IOP (risk increased by 9% per 1 mmHg)
- Vertical and horizontal cup-to-disc ratio (risk increased by 19% per 0.1 larger)
- Pattern standard deviation (PSD) in the visual field (risk increased by 13% per 0.2 dB greater)
- CCT (2.04 fold increased risk per 40 µm thinner)

Based on the pooled OHTS–EGPS predictive model, a quantitative calculator was developed to estimate the 5-year risk for the conversion of ocular hypertension to POAG⁷¹. This tool is available to the clinician and may help to discuss frequency of visits and possible treatment.

However, limitations should also be considered. Because the calculator was based on the OHTS and EGPS data sets, results may not apply to individuals < 40 years old, individuals who have untreated IOPs < 22 mmHg or who are not of Caucasian or of African origin. Also, the calculator does not take into account other factors associated with increased risk for glaucoma, such as family history of glaucoma and pseudoexfoliation. In addition, life expectancy issues should be addressed.

2.2.2.3 Prognostic factors for progression of OAG

Factors associated with the progression of established OAG have been identified by large RCTs: Early Manifest Glaucoma Trial (EMGT)⁷², Advanced Glaucoma Intervention Study (AGIS)⁷³, Collaborative Initial Glaucoma Treatment Study (CIGTS)⁷⁴, Collaborative Normal Tension Glaucoma Study (CNTGS)⁷⁵.

a) **Age**

Older age is significantly associated with increased risk for the progression of OAG. In the EMGT, after a mean follow-up of 8 years, patients ≥ 68 years old had a 51% increased risk of progression compared to those who were younger⁷². In the AGIS the risk of progression increased by 30% with every 5 years increase in age⁷³; in CIGTS the risk increased by 35% for every decade⁷⁴. Also, in the untreated arm of the EMGT, progression was considerably faster in older than in younger patients⁷⁶.

b) **IOP**

Most of the above RCTs suggest a positive effect of IOP reduction on the onset or progression of glaucomatous damage. In the EMGT the risk of progression decreased by about 10% with each mmHg of IOP reduction from baseline to the first follow-up visit⁷⁷. Conversely, the role of long term IOP fluctuation in glaucoma progression is still debated⁷⁸⁻⁸⁰. Also, the role of diurnal IOP fluctuation in glaucoma progression needs to be investigated more thoroughly in RCTs.

c) **Pseudoexfoliation**

In the EMGT, the risk of progression increased by a 2.12-fold in those with pseudoexfoliation compared with those without pseudoexfoliation⁷². In addition, in the untreated arm of the EMGT, progression was considerably faster in eyes with pseudoexfoliation, despite similar baseline IOP values between the pseudoexfoliative and non pseudoexfoliative eyes⁷⁶. Pseudoexfoliation has not been evaluated in the AGIS, CIGTS and CNTGS.

d) **CCT**

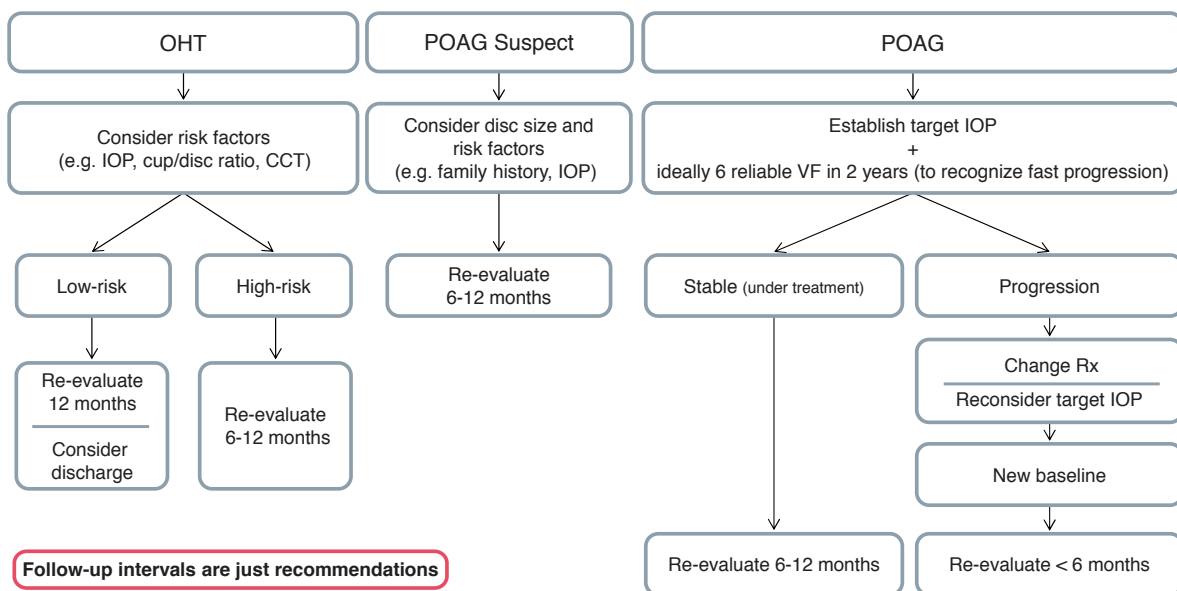
In the EMGT, thinner CCT was a significant but weak prognostic factor for OAG

and this association was observed only in patients with higher baseline IOP⁷². The role of CCT in glaucoma progression has not been evaluated in the AGIS, CIGTS and CNTGS.

e) **Disc haemorrhages**

In the CNTGS the presence of optic disc haemorrhages was significantly associated with glaucoma progression⁸⁰. Also, in the EMGT patients with disc haemorrhages had significantly shorter time to progression⁸¹. A systematic review (January 1950-January 2013) evaluating risk factors for glaucoma among routine diagnostic examination reported disc haemorrhage (LR, 12; 95% CI, 2.9-48) being highly suggestive of glaucoma, but the absence of a haemorrhage was nondiagnostic (LR, 0.94; 95% CI, 0.83-0.98)⁸².

FC V - Assessment and Follow-up



Follow-up intervals are just recommendations

POAG = primary open-angle glaucoma
 OHT = ocular hypertension
 IOP = intraocular pressure
 CCT = central corneal thickness
 Rx = therapy

RULE OUT PRIMARY ANGLE-CLOSURE

2.2.3 Primary Open-Angle Glaucoma

Definition:

Primary open-angle glaucoma (POAG) is a chronic progressive optic neuropathy with characteristic morphological changes at the optic nerve head and retinal nerve fibre layer in the absence of other ocular disease or congenital anomalies. Progressive retinal ganglion cell death and visual field loss are associated with these changes.

Etiology:

The etiology of primary open angle glaucoma remains unclear. Multiple genetic factors and the influence of co-morbidities are likely to play a role.

Pathophysiology:

The current concept of how damage is elicited includes deformation of the lamina cribrosa caused by IOP levels that are not tolerated by the individual eye. This is thought to result in axonal damage with consequent apoptotic death of the retinal ganglion cells. A substantial proportion of patients develop POAG at IOPs within the normal range. Any increase in IOP is caused by elevated outflow resistance in the trabecular meshwork outflow pathways.

Treatment:

POAG is treated by reducing intraocular pressure using medication, laser or incisional surgery (See Ch 3). So far, there is no evidence for other suggested treatment modalities, e.g. neuroprotection or modifying blood flow.

2.2.3.1 Primary Open-Angle Glaucoma / High Pressure Glaucoma (POAG/HPG)

The relative risk for POAG rises continuously with the level of the intra-ocular pressure (IOP), and there is no evidence of a threshold IOP for the onset of the condition. It is presumed that risk factors other than IOP have a relatively greater importance if there is glaucomatous optic neuropathy at the lower (statistically 'normal') pressure levels. POAG has been arbitrarily subdivided into High Pressure and Normal-Pressure disease to reflect this, even though they may represent a spectrum of optic neuropathies variably sensitive to the IOP. See Ch. Introduction.

Etiology:

Unknown

Pathomechanism:

Unknown.

TIGR and Myoc mutations may be associated^{83, 84}.

Features:

- Onset: from the young adult age onwards
- Signs and symptoms:
 - Asymptomatic until field loss advanced
 - Elevated IOP without treatment (diurnal tension curve)

- Optic nerve head: acquired characteristic glaucomatous damage and/or retinal nerve fiber layer changes (diffuse or localized defects) (See Ch. 1)
- Visual field: usually detectable glaucomatous defects corresponding to the optic disc damage may be present
- Gonioscopy: open anterior chamber angle (not occludable, no goniodysgenesis). (See Ch. 1).

Treatment:

Refer also to Introduction II and Ch. 3

A target pressure is to be identified for each case (See also Ch. 3.2 and FC IX-X) [I,D].

- a) Medical treatment (See FC XI-XIII)
 1. Mono therapy
 2. Combination therapy as needed in selected patients
- b) Laser trabeculoplasty (LTP)
- c) Filtration Surgery with / without antimetabolites
- d) Adjunctive medical therapy when needed
- e) Insertion of aqueous long- tube drainage implants
- f) Cyclodestructive procedures

Choice of primary therapeutic modality needs to be made on an individual patient basis [I,D].

Laser trabeculoplasty can be considered as primary treatment and as an alternative to additional medications [I,A].

2.2.3.2 Primary Open-Angle Glaucoma / Normal-Pressure Glaucoma (POAG/NPG)

Etiology:

Unknown

Pathomechanism:

Unknown.

Optineurin mutation has been found in families with NPG

Features:

- Onset: from the 35th year onwards
- Signs and symptoms:
 - Normal IOP without treatment (diurnal curve or 24-hour phasing). Asymptomatic until field loss advanced
 - Optic nerve head damage typical of glaucoma
 - Disc haemorrhages
- Visual field defects typical of glaucoma; e.g. paracentral defects
- Gonioscopy: open anterior chamber angle (exclude intermittent angle-closure; See Ch. 2)
- No history or signs of other eye disease or steroid use.
- Consider central corneal thickness if findings do not match; CCT may be thinner than average (See Ch. 1.1).

Treatment:

Refer also to Chapter Introduction II, Ch. 3 and FC VI

There are few prospective clinical trials indicating clearly the advantages of treatment [I,A]. Target pressure: in most cases a peak IOP = 8 mm - 15 mm Hg on diurnal curve or a 30% IOP reduction from baseline (See Ch. 3.2) [I,D]

- a) Medical therapy:
 - I. Any drug singly or in combination which is effective and tolerated, whose IOP lowering effect is sufficient to reach a maintain the target IOP [I,D]
 - II. Avoid medications with potential vasoconstrictive effects or with systemic hypotensive effects [II,D]
 - III. Oral calcium channel blockers are being investigated in selected patients by some investigators.
- b) Laser trabeculoplasty [I,D]
- c) Glaucoma Surgery:

In cases of progressive glaucomatous damage, in spite of maximal medical therapy or laser trabeculoplasty, or failure to reach target pressure [I,D]. Intensive postoperative care with bleb manipulation may be needed to maintain low IOPs [I,D]

Follow-up intervals, depending on the stage of disease and on the rate of progression, with examination of [II,D]:

- Optic disc
- Visual field
- IOP
- ONH and RNFL documentation

2.2.4 Primary Juvenile Glaucoma

- Etiology: Unknown
- Pathomechanism: Decreased aqueous outflow
- Features:
 - Onset: beyond infancy, usually after puberty or early adulthood. Heredity: if familiar frequently dominant trait. Genes associated with primary juvenile glaucoma have been identified as MYOC and CYP1B1
 - Signs and symptoms:
 - No enlargement of the globe
 - Asymptomatic until field loss is advanced
 - Elevated IOP without treatment (diurnal tension curve)
 - Optic nerve head and RNFL: Diffuse damage typical, but any type of glaucomatous damage
 - Visual field: glaucomatous defects
 - Gonioscopy: wide open anterior chamber angle, often poorly differentiated
 - No congenital or developmental anomalies

Treatment [I,D] (See FC VI):

- a. Medical therapy: any effective and well tolerated topical regimen. Pilocarpine causes fluctuating myopic shift, visual symptoms and headache particularly in the young and should be avoided.
- b. Surgery: early surgery often required filtering procedure or trabeculotomy; consider antimetabolites.
- c. Laser trabeculoplasty: not recommended due to poor and short-lived IOP lowering effect.

2.2.5 Primary Open-Angle Glaucoma Suspect (POAG)

Etiology:

Unknown

Pathomechanism:

Unknown

Features:

- Visual field and/or optic disc and/or nerve fiber layer normal or suspicious, with at least one being suspicious
- IOP can be normal or increased

Treatment [II,D] (See FC VI):

Risks and benefits of treatment need to be weighed against the risk of the development of glaucomatous disc damage. The risk of developing glaucoma increases with the number and strength of risk factors.

The indication for any form of therapy is relative

- a) Medical therapy: any topical agent alone or in combination as long as well tolerated and effective
- b) Avoid adjunctive medical treatment unless strictly needed
- c) Laser trabeculoplasty: not usually indicated
- d) Filtering operation: not indicated
- e) Follow-up [II,D] at intervals of 6-12 months initially, to be increased if all parameters remain normal with examination of:
 - I. Optic disc
 - II. Visual field
 - III. IOP
 - IV. ONH RNFL documentation initially and every 2-3 years

2.2.6 Ocular Hypertension (OH)

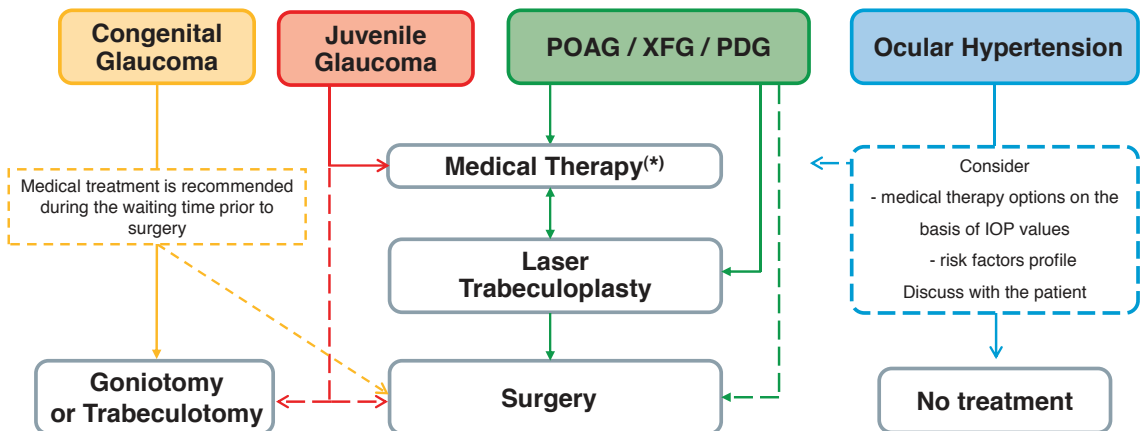
Etiology:
Unknown

Pathomechanism:
Unknown

Features:

- Signs and symptoms:
 - IOP > 21 mm Hg without treatment
 - Visual field: normal
 - Optic disc and retinal nerve fibre layer: normal
 - Gonioscopy: open anterior chamber angle (exclude intermittent angle-closure. See Ch 2.4.2.2)
 - No history or signs of other eye disease or steroid use.
- Other risk factors: none

FC VI - Treatment Options



If the above procedures not successful or feasible, consider repeat filtration surgery with anti-metabolites or long-tube drainage implant/cyclodestructive procedure

(*) Up to 2-3 different drugs. Do not add a drug to a non-effective one; consider switching

POAG = primary open-angle glaucoma

XFG = exfoliative/pseudoexfoliative glaucoma

PDG = pigment dispersion glaucoma

Treatment:

Although in the past it has been used as a diagnosis, Ocular Hypertension should be used to indicate that the IOP is consistently outside 2 or 3 standard deviations above the mean. Consider corneal thickness (See Introduction II and Ch. 1.1; FC II and IV). A modest increase in IOP is not sufficient reason for treatment, but consider it in patients with repeated IOPs in the high twenties, even without risk factors. For treatment modality See Ch. 4.2.3-a (See also Ch. 2.2.3. and flow-charts).

- If left untreated (See Ch. Introduction II)
 - up to 9.5% develop glaucoma over 5 year of follow-up
 - the risk of developing glaucoma increases with increasing IOP
 - prophylactic IOP-lowering therapy to be discussed with individual patients considering the presence of risk factors
 - Follow-up [I,D] at intervals of 12-24 months initially, to be increased if all parameters remain negative, with examination of:
 - Optic disc
 - Visual field
 - IOP
 - ONH and RNFL photographs initially and every 2-3 years

Patients for the ocular hypertension treatment study (Ch. Introduction II) were selected excluding myopes, labile diabetics, poor compliance. In most of Europe black Africans are a minority.

Assess each patient individually when deciding whether or not to treat [I,D].

2.3 - SECONDARY GLAUCOMAS

Secondary glaucomas are a heterogeneous group of conditions, in which elevated IOP is the leading pathological factor causing glaucomatous optic neuropathy. Most forms of secondary glaucoma like uveitic or traumatic glaucoma have complex pathomechanisms including both an open or closed angle.

2.3.1 Secondary Open-Angle Glaucoma

2.3.1.1 Secondary Open-Angle Glaucomas Caused By Ocular Disease

2.3.1.1.1 Exfoliative (pseudoexfoliative) glaucoma

Features:

- Onset: usually older than 60 years
- Asymptomatic until visual field loss advanced
- One or both eyes affected, often bilateral and asymmetrical

Etiology and pathogenic mechanisms.

Exfoliative glaucoma (XFG) develops from exfoliation (pseudoexfoliation) syndrome (XFS), in which an abnormal fibrillo-granular protein (exfoliation material) is produced in the eye and the body. Development of XFS is strongly associated with certain variants of the LOXL1 gene, but the onset of glaucoma may depend on other environmental and/or genetic factors. In the eye exfoliation material accumulates in a characteristic pattern on the anterior lens capsule, pupillary margin, trabecular meshwork and the zonules^{85, 86}. Pigment granules from the posterior layer of the iris are liberated and together with the exfoliation material play an important role in the development of decreased aqueous humour outflow and elevation of IOP, which may lead to the development of glaucoma. Clinically both XFS and XFG may appear in only one eye, but they may develop gradually in the fellow eye in many cases. To identify exfoliation material pupil dilation is recommended. Typically XFG develops after 60 years of age, the IOP is considerably higher than that in POAG, and the diurnal IOP fluctuation is high. As a consequence, in the involved eye(s) optic nerve head damage and visual field deterioration are frequently severe already at the time of the first visit. At a population level, this may partially be counterbalanced by the fact that in certain countries XFG is significantly less undiagnosed than POAG⁸⁷. In XFG the risk for progression is particularly high even when the eye is under IOP lowering treatment⁷⁶. XFS and XFG are associated with poor pupil dilation and other ocular alterations like dense nuclear cataract and zonular damage which make cataract surgery more difficult and increase the risk for surgical complications⁸⁶. Due to zonular damage lens dislocation and resulting secondary angle closure may occur.

Epidemiology:

XFG is the most common type of secondary open angle glaucomas, its prevalence varies considerably across populations^{24, 86}. According to population-based data, XFG develops in approximately 15% to 26% of eyes with XFS (depending on the definition of glaucomatous damage) over a 5 year period²⁷.

Also, it has been reported that XFS and XFG are associated with systemic diseases, particularly cardiovascular alterations⁸⁸. However, there are recent reports which do not support this association^{47, 61, 89-91}.

Signs and symptoms:

IOP: > 21 mm Hg, frequently higher than in average POAG cases.

Visual field loss as in POAG; frequently severe at least in one eye.

Dandruff-like exfoliation material on the pupil border and on the surface of the anterior lens capsule except the central zone, better visualized after pupillary dilation. The pupillary collarette is irregular and typically has a moth-eaten appearance.

Pigmentary loss from the central or mid-iris and positive transillumination are possible.

The angle can be open, narrow or closed; usually the TM is heavily pigmented with a blackish hue and dandruff-like particles and pigment granules may be seen in the lower angle recess.

When pigment accumulates along an undulating line on or anterior to the Schwalbe's line, this feature is called Sampaolesi's line, which is pathognomonic of XFS.

Loose zonules are frequent with occasional phacodonesis, lens subluxation and more frequent complications during cataract surgery.

Narrow or closed-angle is relatively common.

Treatment:

Decrease the IOP with all medications, laser trabeculoplasty and filtering surgery used in the treatment of POAG. Usually XFG responds well to laser trabeculoplasty⁹² To achieve target IOP usually more medications are needed than in POAG. Due to the high diurnal IOP fluctuation, to characterize untreated baseline IOP and IOP under treatment several IOP measurements are necessary. When XFG is clinically unilateral the fellow eye must be also carefully followed because there is a high probability of development of XFG⁹³.

2.3.1.1.2 Pigmentary glaucoma

Etiology:

Melanin granules cause an increase of trabecular meshwork outflow resistance and hence an elevation of IOP. The current understanding is that trabecular meshwork cells phagocytise pigment, which subsequently leads to their death⁹⁴.

Pathogenic mechanism:

Melanin pigment is released from the iris pigmented epithelium as the result of rubbing between lens zonules and posterior surface of the iris. Posterior bowing of the iris with "reverse pupillary block" configuration is noted in many eyes with pigment dispersion^{95,96}.

Three entities can be described:

- Pigment dispersion syndrome (PDS) - ocular condition, usually bilateral characterized by dispersion of iris pigment
- Pigmentary ocular hypertension (POH) - pigment dispersion syndrome with elevated IOP and without glaucomatous optic neuropathy
- Pigmentary glaucoma (PG) - glaucomatous optic neuropathy and pigment dispersion syndrome

Epidemiology:

PG represents 1-1.5% of all glaucoma cases⁹⁷. It is more common in Caucasian myopic men. It typically diagnosed at the age of 30-50 years. The risk of developing glaucoma in patients with PDS is 25 - 50%.

The estimated incidence of PDS and PG is 4.8/100 000 and 1.4/100 000 population per year respectively. The risk of developing pigmentary glaucoma from pigment dispersion syndrome is 10% at 5 years and 15% at 15 years⁹⁸.

Symptoms:

Patients may experience transient visual blurring or halos during episodes of IOP rise, particularly after exercise or pupillary dilation, uncommonly associated with mild to moderate pain.

Signs:

PDS maybe either unilateral or bilateral. Signs of PDS or PG are very deep anterior chamber with backward bowing of the peripheral iris, midperipheral iris transilluminations with a radial spoke like pattern due to pigment loss best visible with retroillumination, pigment deposition on the iris surface and lens equator among zonular insertions, pigment deposition in the corneal endothelium typically accumulating vertically as a Krukenberg spindle. The presence of Krukenberg spindle is not necessary to make the diagnosis of PDS and may occur in other conditions such as exfoliation syndrome. Gonioscopy shows a homogenously dark brown, densely pigmented trabecular meshwork around 360° and pigment at or anterior to the Schwalbe's line, not to be confused with the Sampaolesi's line of pseudoexfoliation; dim light in the examination room is recommended in order pupillary constriction and enhance gonioscopic observation of peripheral iris shape. Ultrasound biomicroscopy (UBM) can be helpful to confirm reverse pupillary block. PDS and PG can be independently combined with primary angle closure.

IOP is typically elevated with large fluctuations. Gradual decrease of IOP after 60 years of age has been reported⁹⁹.

Treatment:

- Medical treatment recommendations for PG are not different to that of POAG [I,D]. Pilocarpine is no longer a preferred drug, but if used, one should check the peripheral retina for tears [II,D].
- Laser trabeculoplasty [I,C] is effective. However, the heavily pigmented trabecular meshwork warrants power settings lower than usual [I,D]. The initially good pressure fall may be lost over time. Repeat ALT is rarely successful¹⁰⁰. c) Nd:YAG laser peripheral iridotomy (LPI) has been proposed as a means for eliminating

reverse pupillary block (if present). The benefit from an LPI in patients with PDS and pigmentary ocular hypertension is not established¹⁰¹. d) Filtering procedures [I,D] are usually as successful as in POAG. Young myopic patients are at increased risk of hypotony maculopathy¹⁰².

Examination after exercise should be considered, especially when visual symptoms after exercises are reported. Increased pigment dispersion with posterior iris bowing during exercise is a sign of potentially progressing disease; in such patients; LPI may be considered¹⁰³.

2.3.1.1.3 Lens-induced open-angle glaucoma

Etiology:

In lens induced open angle glaucoma trabecular meshwork outflow pathways are obstructed by lens particles and/or inflammatory cells¹⁰⁴.

Pathogenic mechanism:

- Phacolytic glaucoma: the trabecular meshwork is obstructed by lens material leaking from mature or hypermature cataract
- Traumatic lens injury: the trabecular meshwork is obstructed by lens particles from a traumatically or surgically injured lens
- Phacoanaphylactic glaucoma: lens proteins lead to granulomatous uveitis affecting the trabecular meshwork.
- Sympathetic Ophthalmia: in rare cases uneventful cataract surgery in one eye can induce inflammation of the previously healthy contralateral eye leading to IOP spikes

Clinical features:

Patients usually suffer from unilateral pain with redness and inflammation. Reduced vision and elevated IOP. Signs of injured lens and/or mature/hypermature cataract or cataract surgery are present, with or without iritis (cf aqueous flare and keratic precipitates).

Treatment:

Extraction of lens or lens fragments followed by topical anti-inflammatory medication, vitrectomy if needed [I,D].

2.3.1.1.4 Glaucoma associated with intraocular haemorrhage

Etiology:

Either acute bleeding in the anterior chamber or long standing blood in the vitreous of any source can cause IOP elevation. Sickle cell trait / disease should always be considered because these patients may be at a higher risk for elevated IOP.

Pathogenic mechanism:

Large quantity of normal red blood cells (hyphaema) or haemoglobin-laden macrophages

(haemolytic glaucoma) or degenerated red blood cells (ghost cell glaucoma) obstruct the trabecular meshwork.

Symptoms:

Pain and eye irritation.

Signs:

Elevated IOP is more common with larger hyphaemas and is more often due to recurrent haemorrhage or re-bleeding. Re-bleeding can follow traumatic hyphaema, usually after 3-7 days (incidence 5 - 10%). Patients with sickle cell disease / trait have an increased incidence of elevated IOP. They are also more prone to developing glaucomatous neuropathy and can be more difficult to treat¹⁰⁵.

In haemolytic glaucoma red-tinged cells in the aqueous humour and reddish brown discoloration of the trabecular meshwork are present. "Ghost cells" occur 1 to 4 weeks after vitreous haemorrhage and reach the anterior chamber. Small khaki-coloured cells may be seen circulating in anterior chamber. Gonioscopic examination may show layering of the ghost cells over the inferior part of trabecular meshwork.

Treatment:

- Topical and systemic IOP lowering medication as needed [I,D]. It is recommended to avoid carbonic anhydrase inhibitors and hyperosmotic agents in patients with sickle cell disease.
- Conservative treatment, bed rest, topical cycloplegics and steroids, can be considered for uncomplicated hyphaema [II,D]. Antifibrinolytic agents such as tranexamic acid can reduce the risk if re-bleeding¹⁰⁶. However it is not clear whether any of the interventions have an effect on visual acuity¹⁰⁷.
- Wash-out through a paracentesis of the anterior chamber [II,D] and/or vitrectomy for removing RBCs from vitreous if IOP remains high with the risk of causing corneal blood staining and/or optic neuropathy [II,D].

2.3.1.1.5 Uveitic glaucoma

Etiology:

Acute IOP elevation is typical in Posner-Schlossman syndrome or in viral infection such as HSV and VZV. Chronic IOP elevation is typical for Fuchs' uveitis, juvenile idiopathic arthritis, Behcet disease, pars planitis, sympathetic ophthalmia, sarcoidosis and syphilis.

Pathogenic mechanism:

Obstruction and oedema of the trabecular meshwork are caused by inflammatory cells, precipitates, debris, secondary scarring and neovascularization of the chamber angle. Secondary angle-closure glaucoma can be due to synechial closure of the chamber angle or seclusio pupillae with subsequent appositional angle closure. Corticoid treatment can also contribute to IOP elevation¹⁰⁸.

Symptoms:

Pain, redness, photophobia, decreased vision are possible.

Signs:

Features depend on the underlying cause. Elevated IOP; some forms are associated with wide oscillations or periodic rise in IOP.

Treatment [I,D]:

- Topical and systemic anti-inflammatory therapy according to the underlying disease
- Topical and systemic IOP lowering medication
 - traditionally topical β -blockers and CAIs were used as first-line treatment.
 - prostaglandin analogues are used as first-line therapy in eyes with controlled uveitis. There are studies that support the efficacy and safety of prostaglandin analogues as IOP lowering medication in uveitic glaucoma¹⁰⁹.
- Glaucoma surgery suited for the type of inflammatory disease, ALT and SLT should be avoided^{110,111}.

2.3.1.1.6 Neovascular Glaucoma (See Secondary Angle Closure Glaucoma)

2.3.1.1.7 Glaucoma due to intraocular tumour

Etiology:

Reduced aqueous humour outflow due to primary or secondary intraocular tumours, mainly of the anterior segment.

Pathogenic mechanism:

Infiltration of the trabecular meshwork by the tumour or tumour cells floating in the aqueous humour. Trabecular meshwork obstruction due to tumour related inflammation, tumour debris, haemorrhage or pigment dispersion. Secondary angle closure glaucoma may also develop¹¹².

Symptoms and signs:

Elevated IOP. A highly variable clinical picture, combining evidence of both tumour and glaucoma.

Treatment [I,D]:

- Treatment of underlying tumour (irradiation, surgical tumour excision, enucleation)
- Topical and systemic IOP lowering medication; medical therapy is often first-line treatment while awaiting definitive treatment:
 - topical β -blockers, α -agonists, topical and systemic CAIs are safe and effective
 - prostaglandin analogues (increasing uveoscleral outflow) and pilocarpine (increasing trabecular outflow) may theoretically promote metastasis
- Cycloablation
- Incisional glaucoma surgery indicated only after successful tumour therapy.

2.3.1.1.8 Glaucoma associated with retinal detachment

Etiology and pathogenic mechanism:

Long standing retinal detachment that leads to ischaemic neovascularization. Retinal detachment is usually associated with a reduction of IOP. Gas tamponade can elicit significant IOP spikes. Dispersed silicon oil may cause chronic IOP elevation.

The trabecular meshwork may be obstructed by neovascularization caused by proliferative retinopathy, or by scarring, pigment dispersion and inflammation, or by cellular debris from retinal cells outer segments (Schwartz's syndrome). Surgery for retinal detachment can also cause glaucoma¹¹³.

Symptoms and signs:

Elevated IOP and retinal detachment are present. Redness and pain are common features.

Treatment [I,D]:

- Topical and systemic IOP lowering medication
- Surgery for retinal detachment
- Consider glaucoma surgery

2.3.1.2 Open-angle glaucoma due to ocular trauma

Ocular trauma leads to glaucoma by several different mechanisms. The secondary traumatic glaucomas can be caused by both open-angle and angle-closure mechanisms. In order to identify and treat the causes of IOP elevation; careful evaluation of the ocular damage must be performed.

Etiology:

Blunt non-penetrating or penetrating trauma to the eye.

Pathogenic mechanisms:

Blunt non-penetrating trauma can lead to reduced trabecular outflow due to traumatic changes of the trabecular meshwork. Scarring and inflammation of the trabecular meshwork, obstruction by red blood cells and debris, angle recession, lens-induced glaucoma. Elevated IOP may occur a very long time after the trauma. Positive steroid response after anti-inflammatory treatment should also be considered. Penetrating injury may damage one or more intraocular structure leading to elevated IOP¹¹⁴.

Symptoms and signs:

Redness, pain, decreased vision with acute IOP elevation, or no symptoms with chronic IOP elevation. Acute or late IOP elevation (occurring months or even decades later) may follow blunt trauma.

Chemical burns, hyphaema, traumatic cataract, uveitis, angle recession, ruptured iris sphincter, iridodialysis can be present in various combinations.

Note: It is not recommended to perform gonioscopy in fresh ocular trauma to avoid compressing the eye. This examination can be delayed for several weeks.

Treatment [I,D]:

- Anti-inflammatory
- Topical and systemic IOP lowering medication
- Long-term IOP follow up in the presence of permanent anterior segment damage.
- Glaucoma surgery

2.3.2 Iatrogenic Secondary Open-Angle Glaucomas

2.3.2.1 Glaucoma due to corticosteroid treatment

Etiology:

Topical, intravitreal as well as high dose and long-term systemic corticosteroid therapy can induce acute or chronic IOP elevation¹¹⁵. The risk of IOP elevation depends on the chemical structure (strength) of the steroid, dose, frequency and duration of therapy, and route of administration. The risk factors for being steroid responder are: POAG, family history of glaucoma, diabetes, myopia, rheumatoid arthritis, children and elderly patients.

Pathogenic mechanism:

Corticosteroids induce changes in the trabecular extracellular matrix (glycoproteins) which lead to decreased outflow facility. A TIGR gene modification is present¹¹⁶.

Symptoms:

Pain and eye irritation are possible but not at all mandatory especially in acute IOP elevation.

Signs:

Elevated IOP usually develops 2 to 6 weeks after initiating therapy, but may occur at any time. Usually IOP elevation is slowly reversed after stopping the use of corticosteroid. Corneal oedema can be present. Prolonged IOP elevation can lead to typical glaucomatous optic nerve head changes and visual field damage.

Treatment [I,D]:

- Discontinuation of corticosteroid therapy is recommended; steroid-sparing therapy of underlying condition should be considered. If this is not possible, consider switching to weaker steroid (e.g. loteprednol, fluorometholone)
- Topical and systemic IOP lowering medication
- Laser trabeculoplasty
- Glaucoma surgery may be performed in intractable cases

2.3.2.2 Secondary open-angle glaucoma due to ocular surgery and laser

Ocular surgery can cause secondary open-angle glaucoma by some of the mechanisms discussed above: intraocular haemorrhage, inflammatory reaction, lens material, pigmentary loss from uveal tissue, or trauma¹¹⁷.

Pathogenic mechanism:

Open-angle glaucoma following ocular surgery or laser is a result of reduced trabecular outflow:

- IOP elevation after intraocular surgery is usually transient. The elevated IOP may be caused by: viscoelastic material, inflammatory debris, vitreous in the anterior chamber after cataract surgery, lens particles, intra-operative application of α -chymotrypsin, and prostaglandin release.
- Acute onset secondary IOP elevation after Nd:YAG laser iridotomy, capsulotomy and laser trabeculoplasty. IOP elevation is usually transient, within the first 24 hours, most frequent in the first 4 hours after treatment.
- IOP elevation with open-angle following vitrectomy with silicon oil implantation develops as a result of:
 - Migration of silicon oil into anterior chamber and obstruction of the trabecular meshwork (early post-op IOP increase) usually due to overflow of oil.
 - Migration of emulsified silicon oil into anterior chamber with obstruction of trabecular meshwork where oil particles are partially phagocytised by macrophages and accumulate in the trabecular meshwork especially in the upper quadrant and can induce trabeculitis (intermediate and late onset IOP increase). Prolonged contact of silicon oil with the trabecular meshwork may cause permanent structural changes. Risk factors for developing IOP elevation following vitrectomy with silicon oil implantation include pre-existing ocular hypertension or glaucoma, diabetes mellitus, and aphakia (closed angle type)^{118,119}.
- Uveitis-glaucoma-hyphema (UGH) syndrome - IOP elevation associated with an anterior chamber intraocular lens due to induced iris root bleeding and anterior uveitis. Modern IOLs pose a significantly lower risk of inducing UGH syndrome.

Treatment [I,D]:

- Topical and systemic IOP lowering medication
- Anti-inflammatory treatment
- Removal of silicone oil may be considered in eyes with IOP elevation secondary to silicon oil emulsification. However current data suggest that removal of silicon oil is not effective in all cases and the risk of re-detachment increases. Trans-scleral cyclophotocoagulation and aqueous drainage devices seem to represent more effective options, although the latter are associated with the risk of silicon oil escape into sub-conjunctival space. Endoscopic cyclophotocoagulation in eyes requiring silicon oil removal and antiglaucoma treatment seems to be effective option. Conventional filtration surgery is associated with poor prognosis.
- Removal of the intraocular lens may be needed in case of UGH syndrome
- Glaucoma surgery according to the specific condition

2.3.3 Secondary Open-Angle Glaucoma Caused By Extrabulbar Disease

2.3.3.1 Glaucoma caused by increased episcleral venous pressure

Etiology and pathogenic mechanism:

Episcleral, orbital or systemic diseases can cause the elevation of episcleral venous pressure with subsequent reduction of trabecular outflow and IOP elevation. The following disorders can be described:

- Episcleral and orbital causes: chemical burn or radiation damage of the episcleral veins, hemangioma in Sturge-Weber syndrome, Nevus of Ota, endocrine orbitopathy, orbital (retrobulbar) tumor, pseudotumor, orbital phlebitis, orbital or intracranial arteriovenous fistula
- Neurologic conditions: dural shunts, cavernous sinus thrombosis
- Other systemic causes: superior vena cava obstruction, jugular vein obstruction (radical neck dissection), pulmonary venous obstruction
- Idiopathic forms

Symptoms and signs:

IOP elevation can be acute with eye irritation and pain. Visual acuity can be decreased. Dilated, congested episcleral veins, chemosis, facial lymphedema, orbital bruit can be present. Vascular bruits are characteristic signs of A/V fistulae²⁰

Treatment [I.D]:

- a) Treatment of the underlying disease
- b) Topical and systemic IOP lowering medication
- c) Glaucoma surgery

2.4 - PRIMARY ANGLE-CLOSURE

Scientific publications on angle-closure have suffered from the lack of a uniform definition and specific diagnostic criteria. Only in recent years has there been recognition of the need to standardize definitions of the various types.

Angle-closure is defined by the presence of iridotrabecular contact (ITC). This can be either appositional or synechial. Either can be due to any one of a number of possible mechanisms. Angle closure may result in raised IOP and cause structural changes in the eye. Primary angle-closure (PAC) is defined as an occludable drainage angle and features indicating that trabecular obstruction by the peripheral iris has occurred. The term glaucoma is added if glaucomatous optic neuropathy is present: Primary angle-closure glaucoma (PACG). The main reason to distinguish Primary angle-closure glaucoma from Primary open-angle glaucoma is the initial therapeutic approach (i.e. iridotomy or iridectomy) and the possible late complications (synechial closure of the chamber angle) or the complications resulting when this type of glaucoma undergoes filtering surgery (uveal effusion, cilio-lenticular block leading to malignant glaucoma)^{121,122}.

The prevalence of primary angle closure glaucoma (PACG)

Ethnic background is one of the major factors determining susceptibility to primary angle-closure (PAC). Population surveys show that PAC is more common among people of Asian descent than those from Europe. Among people aged 40 years and over, the prevalence of PAC ranges from 0.1% in Europeans^{123,124} through 1.4% in East Asians^{123,124} and up to 5% in Greenland Inuit¹²⁵. Of those over 40 years old in European derived populations, 0.4% are estimated to have PACG. Three-quarters of cases occur in female subjects. There are 1.60 million people in Europe and 581 000 people in the USA with PACG¹²⁶.

Primary glaucoma cases should be examined and the anterior chamber angle shown to be open on gonioscopy before PACG is excluded¹²⁷.

Provocative Tests

In general provocative tests for angle-closure provide little additional information since even when negative they may not rule out the potential for angle-closure. In addition they may be hazardous, triggering an acute angle-closure attack even while the patient is monitored.

2.4.1 Primary Angle-Closure (PAC)

Angle-closure is defined by the presence of iridotrabeular contact (ITC). Gonioscopy remains the standard technique for identifying ITC. Primary angle-closure (PAC) results from crowding of the anterior segment, and as such, usually occurs in eyes with smaller than average anterior segment dimensions. Pathological angle-closure is defined by the presence of ITC combined with either elevated intraocular pressure (IOP) or peripheral anterior synechiae (PAS), or both. The absence of ocular diseases which may induce the formation of PAS such as uveitis, iris neovascularisation, trauma and surgery, defines primary angle-closure. Additionally, angle-closure resulting from the action of forces at the level of the lens or behind the lens is usually regarded as secondary (i.e. cataract, massive vitreous haemorrhage, and silicone oil or gas retinal tamponade) as the successful management is aimed at the underlying lens or posterior segment pathology. Angle-closure may impair aqueous outflow through simple obstruction of the trabecular meshwork (TM), or by causing irreversible degeneration and damage of the TM.

2.4.1.1 Natural History of PAC

PAC becomes more likely as the separation between the iris and TM decreases¹²⁸. The risk of iridotrabeular contact in a “narrow” angle begins to increase once the iridotrabeular angle is $\leq 20^\circ$ ¹²⁹. With angles of 20° or less, signs of previous angle-closure, such as PAS or iris pigment on the TM, should be carefully sought as signs of previous closure. Most angle-closure occurs asymptotically. Although symptoms of pain, redness, blurring of vision or haloes may help identify people with significant angle-closure, the sensitivity and specificity of symptoms for identifying angle-closure are very poor. The most commonly identified sign which indicates that treatment is required is ITC. There is not a precise extent of gonioscopically evident ITC which will dictate the indication to treatment for all cases.

An international group of experts reached a consensus that 2 quadrants or more of ITC is an indication for prophylactic treatment¹³⁰ [II,D].

Clearly, in established disease with high IOP, established PAS or glaucomatous optic neuropathy, any potential for angle-closure should be considered and treated on individual merits.

2.4.1.2 Staging of Primary Angle-closure¹²³

- a) Primary Angle-closure Suspect (PACS)
Two or more quadrants of iridotrabeular contact (ITC), normal IOP, no PAS, no evidence of glaucomatous optic neuropathy (GON).
- b) Primary Angle-closure (PAC)
Iridotrabeular contact resulting in PAS and/or raised IOP. No evidence of GON.
- c) Primary Angle-closure Glaucoma (PACG)
Iridotrabeular contact causing GON; PAS and raised IOP may be absent at the time of initial examination.

2.4.1.3 Ocular Damage in Angle-closure

Primary angle-closure (PAC) may cause ocular tissue damage in many ways. Corneal endothelial cell loss occurs after symptomatic “acute” angle-closure. With very high IOP values the iris may suffer ischaemic damage to musculature causing iris whirling (distortion of radially orientated fibres) and/or a dilated, unresponsive pupil. The lens epithelium may suffer focal necrosis causing anterior sub-capsular or capsular opacity of the lens associated with focal epithelial infarct called “Glaukomflecken”. The trabecular meshwork can be damaged by the formation of PAS, or as the result of long- standing appositional closure. Optic neuropathy in angle-closure may manifest in at least 2 ways. After an “acute” symptomatic episode, the disc may become pale but flat, suggesting an anterior ischaemic optic neuropathy. Typical glaucomatous optic neuropathy manifests in with an excavated surface and a pattern of visual field loss indistinguishable from open-angle glaucoma. Angle-closure accounts for 50% of all glaucoma blindness worldwide, and is probably the most visually destructive form of glaucoma.

2.4.1.4 Outcome following treatment

In asymptomatic (“chronic”) angle-closure, a high presenting pressure (>35 mmHg), more than 6 clock hours of peripheral anterior synechiae and/or established glaucomatous optic neuropathy are signs that a case of angle-closure will not respond fully to a laser iridotomy¹³¹, and that a trabeculectomy may be needed to control pressure” [II,D].

2.4.1.5 Mechanisms of angle-closure

It is important to identify secondary causes of narrow or closed-angles, such as phacomorphic, uveitic and neovascular cases, as the management of these cases is initially directed at controlling the underlying disease. In isometric eyes it is helpful to compare axial anterior chamber depths of the two eyes. Asymmetry of > 0.2 mm (3 standard deviations) is suggestive of a secondary pathological process. A-mode or ultrasound biomicroscopy may be helpful in measuring axial dimensions (length, AC depth and lens thickness) and defining anatomical relationships. In primary angle-closure these will be the same in each eye. Mechanisms responsible for angle-closure are described in terms of anatomical location of obstruction to aqueous flow, successively, at the pupil, the iris and ciliary body, the lens and behind the lens. This is also order of decreasing frequency of each mechanism. Two mechanisms may co-exist, especially levels I and II (i.e. pupil and iris/ciliary body). Often, one mechanism predominates.

I. Pupillary block mechanism

Pupillary block is the predominant mechanism in around 75% of cases of primary angle-closure. Pupillary block is an exaggeration of a physiological phenomenon in which the flow of aqueous from the posterior chamber through the pupil to the

anterior chamber is impeded causing the pressure in the posterior chamber to become higher than the pressure in the anterior chamber. As a result, the peripheral iris bows forward and comes into contact with the trabecular meshwork and/or peripheral cornea.

In a minority of cases, this becomes a self-perpetuating cycle with obstruction of trabecular outflow leading to a rise in IOP up to 50-80 mmHg. When total trabecular obstruction occurs rapidly (within a few hours), it causes the symptoms and signs of acute angle-closure (AAC).

The increased resistance to trans-pupillary aqueous flow is believed to result from co-activation of both sphincter and dilator muscles, causing the pupil margin to grip the anterior surface of the lens. This may occur in response to physiological stimuli, such as reading in poor light, or pharmacologically, such as with miotic therapy and concomitant dilator muscle stimulation by phenylephrine (the Mapstone provocation test)¹³². In most cases, the predisposition to pupil block is created by a narrow anterior segment and the age-related increase of lens volume (See Ch. 2.5.1 and 2.5.3).

The prevalence of PAC is higher in elderly people women and in some races (especially East Asians). There is a weaker association with hypermetropia, exfoliation syndrome, diabetes and retinitis pigmentosa.

II. Anomalies at the level of the iris and/or ciliary body (“plateau iris configuration”)

This group of anterior, non-pupil-block mechanisms are sometimes erroneously referred to under the umbrella term “plateau iris”. They are the result of variations in iris and ciliary body anatomy that brings the peripheral iris into contact with the trabecular meshwork. These include a thicker iris, a more anterior iris insertion and a more anterior ciliary body position. These anatomical factors predict failure of a laser iridotomy to open an appositionally closed angle¹³³.

Anteriorly positioned ciliary processes cause “typical” plateau iris configuration¹³⁴. Plateau iris “syndrome” should be differentiated from plateau iris configuration. The “configuration” refers to a situation in which the iris plane is flat and the anterior chamber is not shallow axially. In most cases, the angle-closure glaucoma associated with the plateau iris configuration is cured by a peripheral iridectomy. “*Plateau iris syndrome*” refers to a post-laser condition in which a patent iridotomy has removed the relative pupillary block, but gonioscopically confirmed angle closure recurs without shallowing of the anterior chamber axially. Plateau iris syndrome is rare compared to the configuration, which itself is not common. It usually occurs in a younger age group than pupillary-block angle-closure. The treatment is laser iridoplasty or the long-term use of pilocarpine postoperatively as long as it is needed [II,D]. This syndrome must be considered in the differential diagnosis when the intraocular pressure rises unexpectedly following an adequate peripheral iridectomy procedure for angle-closure glaucoma¹³⁵.

Ideally, treatment should be instituted before synechial closure of the angle occurs [II,D]

III. Anomalies at the Level of the Lens

The most widely recognised risk factor for primary angle-closure is a shallow anterior chamber. The anterior surface of the lens marks the depth of the anterior chamber, and as such, PAC patients typically have a thicker, more anteriorly positioned lens

than people with wide open angles. Nuclear sclerotic cataract is a frequent finding in primary angle-closure. If a separate pathological or iatrogenic process causes the lens to suddenly increase in thickness (e.g. "classic" diabetic or post-traumatic cataract), become more anteriorly positioned (retinal gas or oil tamponade) or subluxate (Marfan syndrome or trauma), this may cause secondary angle-closure (See Ch. 2.5.1 and 2.5.3).

IV. Anomalies posterior to the Lens (Aqueous misdirection syndrome)

In rare cases, aqueous misdirection can complicate the management of primary angle-closure. This may occur following trabeculectomy, lens extraction, laser iridotomy and other surgical procedures. Forward movement of the lens iris diaphragm causes secondary angle-closure resulting in IOP elevation. These cases, typically have very small eyes (axial length <21 mm) and higher hypermetropic refraction (> +6D). It is believed that the ciliary processes come into contact with the lens equator, and/or a firm zonule/posterior capsule diaphragm, causing misdirection of aqueous into the vitreous^{135, 136}. As a consequence, the lens/iris diaphragm is pushed forward and occludes the anterior chamber angle. After iridotomy or iridectomy, the use of miotics raises the IOP, whereas the use of cycloplegics reduces the IOP. This 'inverse' or 'paradoxical' reaction to parasympathomimetics should be tested only after iridotomy has been performed. Ultrasound biomicroscopy can demonstrate abnormal posterior chamber anatomy in these rare cases (See Ch. 2.5.3).

Asymmetry of anterior chamber depth is a cardinal sign of secondary (types III and IV) angle-closure.

Systemic drugs and angle-closure

Systemic drugs which may induce angle-closure in pre-disposed individuals are: nebulised bronchodilators (ipratropium bromide and/or salbutamol), selective serotonin re-uptake inhibitors (SSRI's), tricyclic antidepressants, proprietary cold and flu medications, muscle relaxants, anti-epileptics (topiramate) and other agents with a parasympatholytic and sympathomimetic action¹³⁷.

2.4.1.6 Demographic risk factors for Primary Angle-Closure^{135,138}

- Older age
- Female
- Asian and Eskimoan Race

Family history of primary angle-closure: family screening is vital in these families as robust evidence now exists for significant increased risk of angle closure in family members of an affected patient: first degree relatives may have a 1 in 4 risk of a PAC disease requiring treatment¹³⁹.

2.4.1.7 Descriptions of subtypes:

Primary angle-closure has previously been divided into 5 clinical subtypes according to mode of presentation. *There is debate on whether this approach to classification is useful in determining the prognosis or optimal management.*

- Primary Angle-Closure Suspect (PACS)
- Acute Angle-Closure (AAC)
- Intermittent Angle-Closure (IAC)
- Chronic Angle-Closure Glaucoma (CACG)
- Status Post-Acute Angle-closure Attack

2.4.1.7.1 Primary Angle-Closure Suspect (PACS) or “occludable” angle

Etiology and pathomechanism:

Pupillary block or plateau iris configuration; each component plays different roles in different eyes (See Ch. 2.4.1.5).

Features:

Signs:

- Two or more quadrants of iridotrabecular contact (ITC)
- Normal IOP
- No peripheral anterior synechia (PAS)
- No evidence of glaucomatous optic neuropathy (GON)
- No glaucomatous visual field defect

The fellow eye of a documented non-secondary angle-closure is considered capable of occlusion.

Treatment:

PACS or “occludable angle” is a clinical assessment. Whether to treat or not is the responsibility of the ophthalmologist. There is not a precise extent of gonioscopically evident ITC which will dictate the indication to treatment for all cases.

If a PAC suspect has narrow angle with two or more quadrants of ITC but no synechial angle closure, the treatment to offer the patient is laser peripheral iridotomy (LPI) followed by argon laser peripheral iridoplasty (ALPI) in cases with plateau iris configuration [I,D].

The same applies to fellow eyes of primary angle-closure [I,C]. All cases must be assessed individually [I,D]. In general, the risks of treatment are to be balanced against the perceived risk of angle-closure.

2.4.1.7.2 Acute Angle-Closure (AAC) with pupillary block mechanism

Etiology:

Circumferential iris apposition to the trabecular meshwork with rapid and excessive increase in IOP that does not resolve spontaneously.

Pathomechanism:
See Ch. 2.4.1.5

Features:

Signs:

- IOP >21 mmHg, often to 50-80 mmHg.
- Decreased visual acuity
- Corneal oedema, initially mostly epithelial oedema. Shallow or flat peripheral anterior chamber
- Peripheral iris pushed forward and in contact with Schwalbe's line. Gonioscopy: iridotrabecular contact 360°
- Pupil mid-dilated and reduced or no reactivity
- Venous congestion and ciliary injection
- Fundus: disc oedema, with venous congestion and splinter haemorrhages, or the disc may be normal or show glaucomatous excavation
- Bradycardia or arrhythmia
- Gonioscopy clues from the other eye

Symptoms:

- Blurred vision, "halos" around lights
- Pain
- Frontal headache of variable degree on the side of the affected eye
- Nausea and vomiting, occasionally
- Palpitations, abdominal cramps, occasionally

Treatment options:

See also flowchart FC VII-VIII

- A. Medical treatment
- B. Laser peripheral iridotomy (LPI)
- C. Argon Laser Peripheral Iridoplasty (ALPI)
- D. Lens Extraction
- E. Trabeculectomy
- F. Anterior Chamber Paracentesis
- G. Goniosynechialysis (GSL)

Iridotomy or iridectomy together with medical treatment is the preferred definitive treatment of acute angle-closure glaucoma with a pupillary block component [I,D]

A: Medical Treatment [I,D]

Medical treatment serves to lower IOP, to relieve the symptoms and signs so that laser iridotomy or iridectomy is possible

Medical therapy aims for

1. withdrawal of aqueous from vitreous body and posterior chamber by hyperosmotics
2. pupillary constriction to open the chamber angle
3. reduction of aqueous production reduction of inflammation.

All the above steps of medical therapy should be implemented concurrently [I,D]

Consider contraindications to each of the medications to be used

- Reduction of aqueous production
 - acetazolamide 10 mg/Kg intravenously or orally. Topical carbonic anhydrase inhibitors (CAIs) are not potent enough to break the pupillary block
 - topical alpha-2 agonists
 - topical beta-blockers
- Dehydration of vitreous body

Hyperosmotics are the effective agents but carry significant systemic risk in some patients: patients must be evaluated for heart or kidney disease because hyperosmotics increase blood volume which increases the load in the heart [IID]. Glycerol may alter glucose blood levels and should not be given to diabetics (FC VII) [I,D]

- glycerol 1.0 - 1.5 g/Kg orally
- mannitol 1.0 - 1.5 g/Kg intravenously

- Pupillary constriction [I,D]
 - pilocarpine 1% or 2% or aceclidine 2% twice or three times within 1 hour
Note: while the sphincter is ischaemic and the pupil non-reactive to light for sphincter paresis, multiple applications of topical parasympathomimetics is not helpful, will not cause pupillary constriction and may cause forward rotation of the ciliary muscle, thereby increasing the pupillary block. Since miotics in large doses can cause systemic side effects due to trans-nasal absorption leading to abdominal spasms and sweating, intensive topical parasympathomimetics are no longer indicated to treat this condition. Miotics are likely to constrict the pupil only after IOP has been lowered.
 - dapiprazole 0.5%
 - Alpha-1 blockers relax the dilator muscle. They do not reduce pupil size when the sphincter-muscle is parietic.
- Reduction of inflammation
Topical steroid every 5 minutes for three times, then 4-6 times daily, depending on duration of raised IOP and severity of inflammation.

B: Surgical Treatment

- Neodymium YAG laser iridotomy
Laser iridotomy should be attempted if the cornea is sufficiently clear [I,C]. Argon laser iridotomy is rarely performed nowadays but thermal laser pre-treatment (e.g., argon) of dark irides reduces total YAG energy required¹²⁷ [II,B]
- Surgical iridectomy
 - 1) Transcorneal approach.
 - Advantages:
 - No conjunctival scarring
 - A water-tight self-sealing incision is possible

- Disadvantages:
 - Technically more difficult in dilated fixed pupil and flat anterior chamber
 - More traction on iris with increased risk of haemorrhage
- 2) Corneoscleral approach
 - Advantages:
 - Iridectomy can be basal
 - Disadvantages:
 - Conjunctival wound may lead to scarring compromising the outcome of a filtering procedure which may become necessary at a later stage insufficient wound closure and aqueous misdirection may occur in rare cases
- 3) General advantages of surgical iridectomy:
 - It can be performed even when the cornea is cloudy
 - It allows deepening of the anterior chamber, breaking freshly formed PAS
- 4) General disadvantages of surgical iridectomy:
 - All the potential risks of any intraocular procedure in an eye with angle closure

C: Argon Laser Peripheral Iridoplasty (ALPI)

There is now some evidence from randomised controlled trials that ALPI can break an attack of acute angle closure as or more swiftly than medical therapy¹⁴⁰. Many glaucoma specialists now routinely use ALPI if topical treatment + acetazolamide have not broken an attack within an hour, prior to considering hyper-osmotics. ALPI is also a useful procedure to eliminate appositional angle closure resulting from mechanisms other than pupillary block (i.e: plateau iris configuration)¹⁴¹.

Diode Laser Peripheral Iridoplasty has greater penetration of an oedematous cornea but has been less extensively studied.

Anterior chamber paracentesis is being evaluated to break the attack in cases that are refractory to medical management¹⁴².

D: Lens extraction See FC VII

Clinical reports of phacoemulsification with posterior chamber intraocular lens implantation in the treatment of acute, chronic, and secondary angle-closure +/- glaucoma describe very favourable results. The appropriate role for lensectomy in the management of primary angle closure, however, still remains unproven. The first case-series study showed that cataract extraction was associated with a good reduction in IOP and a reduction in the number of medications required to control IOP¹⁴³.

A few prospective case series or randomized clinical trials have been performed¹⁴³⁻¹⁴⁶ or are ongoing¹⁴⁷ to determine the value and comparative risks and efficacy of lens surgery, both clear lens extraction and cataract surgery, versus medical therapy, laser peripheral iridotomy, laser iridoplasty, and filtration procedures for the treat-

ment of acute and chronic primary angle closure and for the prevention of chronic angle-closure glaucoma, both after and instead of laser peripheral iridotomy. Cataract surgery in PACG is generally more challenging and prone to complications than in normal eyes or eyes with POAG because of the shallow AC, larger lens, corneal oedema, poorly dilated or miotic pupil, extensive posterior synechiae, lower endothelial cell count, weaker zonules, especially after an acute angle closure attack.

In an eye with a clear lens: laser PI first. If the angle does not open and IOP not well controlled with unquestionable glaucomatous damage, consider to proceed with phacoemulsification and IOL implantation [I,D].

E: Trabeculectomy

Trabeculectomy in chronic PACG is also associated with higher risk of postoperative anterior chamber shallowing, malignant glaucoma, and a significant rate of cataract formation compared to POAG¹³⁷. Even when filtration surgery has successfully reduced the IOP, the ailing trabecular meshwork does not regain its function, and so the disease is not cured.

Combined lens extraction and trabeculectomy

In a study in CACG eyes with coexisting cataract, combined phacotrabeculectomy resulted in significantly more surgical complications than phacoemulsification alone. Visual acuity or disease progression did not differ between the 2 treatment groups¹⁴⁸.

F: Anterior Chamber Paracentesis^{139, 142}

- Rapidly lowers IOP in APAC
- Instantaneous relief of symptoms
- Prevention of further optic nerve and trabecular meshwork damage secondary to the acutely elevated IOP
- The IOP-lowering benefit may decrease by 1 hour after the procedure
- Anti-glaucoma medications are necessary to maintain IOP control.

Paracentesis will not directly break the pupillary block but can allow the cornea to clear permitting to perform LPI

Possible complications include

- Excessive shallowing of the anterior chamber
- Puncture of iris, lens
- Choroidal effusion
- Haemorrhage due to the sudden decompression

G: Goniosynechialysis¹³⁸

Often performed with other procedures such as lens extraction, to detach synechia from the angle, in eyes with minimal to moderate optic nerve damage.

The procedure may be complicated by:

- hyphema
- fibrinous inflammation and
- recurrent synechial closure of the angle

2.4.1.7.3 Acute Angle-Closure (AAC) with plateau iris configuration (See FC VII)

In plateau iris configuration the iris plane is flat and the anterior chamber is not shallow axially. (See above under Staging of Primary Angle-closure).

Medical treatment [II,D]:

- Pupillary constriction to pull the peripheral iris centripetally
- In plateau iris configuration, a modest pupillary constriction may prevent further angle- closure
 - pilocarpine 1%, aceclidine 2%, carbachol 0.75%
 - dapiprazole 0.5%

Surgical treatment [I,D]:

- Iridotomy is essential to confirm the diagnosis because it eliminates any pupillary block component
- Argon Laser Peripheral Iridoplasty (ALPI) stretches the iris and widens the chamber angle¹⁴⁹.

“Plateau iris syndrome” refers to a post-laser iridotomy condition in which a patent iridotomy has removed the relative pupillary block, but gonioscopically confirmed angle closure recurs without central shallowing of the anterior chamber. Isolated plateau iris syndrome is rare compared to the plateau configuration, which itself is not common. It usually occurs in a younger age group than pupillary-block angle-closure. The treatment is laser iridoplasty or the long-term use of pilocarpine postoperatively [II,D]. This condition must be considered in the differential diagnosis when the intraocular pressure rises unexpectedly following an adequate peripheral iridectomy procedure for angle-closure glaucoma¹³⁵.

2.4.1.7.4 Intermittent Angle-Closure (IAC)

Etiology:

Similar but milder clinical manifestations than AAC, it resolves spontaneously.

Pathomechanism:

See above Ch. 2.4.1.5

Features:

Signs:

- May vary according to amount of iridotrabecular contact of chamber angle and mimic acute angle-closure in a mild form
- When not on miotics, pupil is round and reactive
- The optic disc rim may show atrophy with an afferent pupillary defect

Symptoms:

- Mild, intermittent symptoms of acute angle-closure type

Treatment:

Pupillary constriction, iridotomy, iridoplasty or lens extraction are to be considered according to the main mechanism determining angle occlusion [II,D]

FC VII - Management of Acute Primary Angle Closure Attack

Medical Procedures

Decrease AH* production

Topical therapy

β -blockers / α_2 -agonists

Systemic therapy (IV / oral)

Acetazolamide / Mannitol
(repeat if necessary)

+

Re-open the angle

Pharmacologically

Pilocarpine 2%

Mechanically

Corneal indentation (4 mirror lens)
Consider clear cornea paracentesis

+

Reduce inflammation

Topical Steroids

Laser / Surgical procedures

Break pupillary block + re-open angle

Iris procedures

← and/or →

Lens extraction

Clear Cornea ←-----Try topical glycerin 10%----- Cloudy Cornea

Iridotomy / Iridectomy

Iridectomy

**!Remember prophylactic
iridotomy
in the other eye!**

* Aqueous Humor

Depending on availability, consider laser
iridotomy a first treatment option

2.4.1.7.5 Chronic Angle-Closure Glaucoma (CACG) (See FC VIII)

Etiology:

Permanent synechial closure of any extent of the chamber angle as confirmed by indentation gonioscopy.

Pathomechanism:

See Ch. 2.4.1.5

Features:

Signs:

- Peripheral anterior synechiae of any degree at gonioscopy
- IOP elevated to a variable degree depending on the extent of iridotrabeular contact, above 21 mmHg
- Visual acuity according to functional status (may be normal)
- Damage of optic nerve head compatible with glaucoma
- Visual field defects “typical” of glaucoma may be present
- Superimposed intermittent or acute iridotrabeular contact possible

Symptoms:

- Visual disturbances according to functional states.
- Usually no pain; sometimes discomfort
- Transient “halos” when intermittent closure of the total circumference causes acute IOP elevations

Treatment:

Medical treatment alone is contraindicated as all patients require relief of pupil block by iridotomy, iridectomy or lens extraction [I,D]. If the synechial closure is less than half the circumference, iridectomy/iridotomy may be sufficient.

Since complications of iridotomy are uncommon, its use as the initial procedure is justified in practically every case [I,D].

Argon laser trabeculoplasty is contraindicated as it may increase synechial angle-closure [I,D]. Lens removal may be considered at all stages and can lead to relief of pupil block and sufficient IOP control [II,D].

If IOP cannot be controlled medically after breaking pupil block (with or without lens extraction), a filtering procedure is indicated [II,D].

These eyes are more frequently prone to develop posterior aqueous misdirection and the necessary precautions must be taken when considering surgery.

2.4.1.7.6 Status Post-Acute Angle-closure Attack

Etiology:

Previous episode of acute angle-closure attack

Pathomechanism:

See Ch. 2.4.1.5

Features:

Signs:

- Patchy iris atrophy Iris torsion/spiralling posterior synechiae
- Pupil either poorly reactive or non-reactive
- “Glaukomflecken” of the anterior lens surface
- Peripheral anterior synechiae on gonioscopy
- Endothelial cell count can be decreased

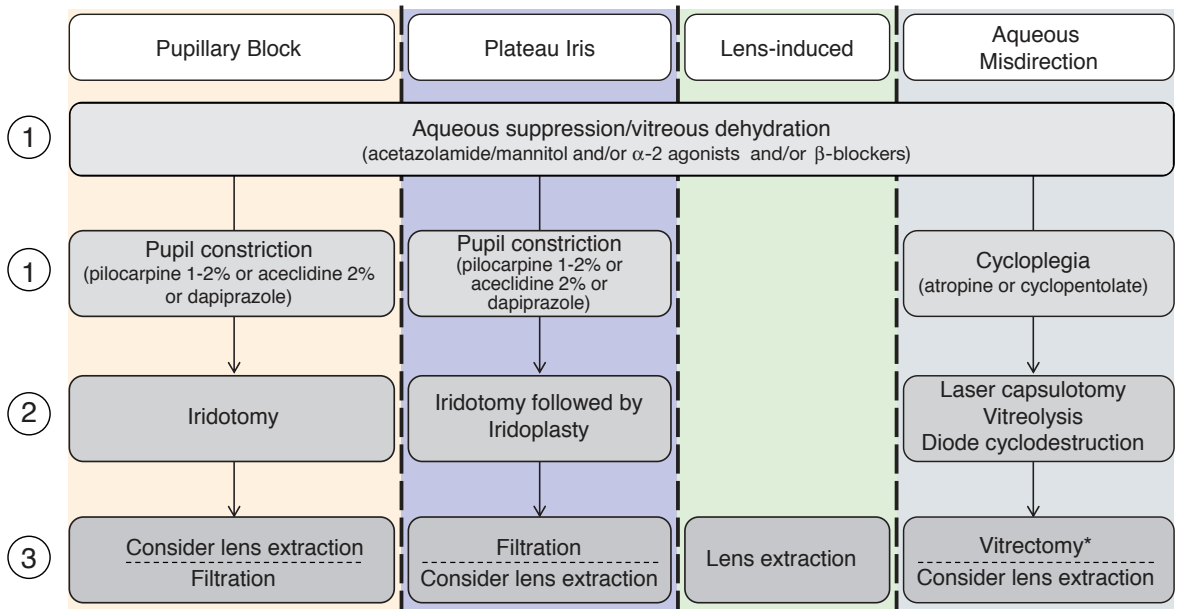
Therapy:

Management according to angle, lens, IOP and disc/visual field. In case of cataract surgery, non dilatable pupil, low endothelial cell count and loose zonules are of concern.

FC VIII - Management of Chronic Angle Closure

IDENTIFY THE PATHOPHYSIOLOGICAL MECHANISM(S) RESPONSIBLE

Make sure a **patent iridotomy** is present/made before considering mechanisms other than pupillary block



* Combined with zonulectomy-iridectomy in pseudophakia

2.5 - SECONDARY ANGLE-CLOSURE

There are many different causes of secondary angle-closure and the clinical signs vary according to the underlying condition. For example in secondary acute angle-closure, the chamber angle is closed by iridotrabecular contact that can be reversed, whereas in chronic secondary angle-closure, the angle-closure is irreversible due to peripheral anterior synechiae.

A complete discussion of these topics is outside the scope of this text.

2.5.1 Secondary Angle-Closure With Pupillary Block

Etiology:

The following is a limited list of other etiologies for relative or absolute pupillary block:

- Enlarged, swollen lens (cataract, traumatic cataract)
- Anterior lens dislocation (trauma, zonular laxity; Weil-Marchesani's syndrome, Marfans's syndrome etc.)
- Posterior synechiae, seclusion or occlusion of the pupil
- Protruding vitreous face or intravitreal silicone oil in aphakia
- Microspherophakia
- Miotic-induced pupillary block (also the lens moves forward)
- IOL-induced pupillary block; anterior chamber IOL, phakic intraocular lens (PIOL), anteriorly dislocated posterior chamber intraocular lens (PC-IOL)¹⁵⁰

Pathomechanism:

Pupillary block pushes the iris forward to occlude the angle. In iritis or iridocyclitis, the development of posterior synechiae may lead to absolute pupillary block with consequent forward bowing of the iris or "iris bombé". Acute secondary angle-closure glaucoma may result.

Features:

- IOP > 21 mmHg
- Disc features compatible with glaucoma

Treatment:

Several steps may be considered, according to the clinical picture of causative mechanisms [II,D]

- Topical and systemic IOP lowering medication
- Nd:YAG laser iridotomy
- Peripheral surgical iridectomy
- Lens extraction, vitrectomy
- Discontinuing miotics in miotic-induced pupillary block
- Pupillary dilation
- Nd:YAG laser synechiolysis of posterior synechiae

2.5.2 Secondary Angle-Closure With Anterior “Pulling” Mechanism Without Pupillary Block

Pathomechanism:

The trabecular meshwork is obstructed by iris tissue or a membrane. The iris and/or a membrane are progressively pulled forward to occlude the angle.

Features:

- IOP > 21 mmHg
- Disc features compatible with glaucoma

2.5.2.1 Neovascular glaucoma

The iridotrabecular fibrovascular membrane is induced by ocular microvascular disease with retinal ischemia; initially the neovascular membrane covers the angle, causing a secondary form of open angle glaucoma (See Ch 2.3 Secondary Open Angle Glaucoma)

Treatment [II,D]:

- a) Topical atropine or equivalent
- b) Topical steroid initially
- c) Topical and systemic IOP lowering medication as needed
- d) Retinal ablation with laser or cryotherapy
- e) Cyclodestruction
- f) Filtering procedure with antimetabolites
- g) Aqueous drainage devices
- h) Miotics are contraindicated

The intravitreal injection of anti-VEGF molecules has shown benefit for this indication [II,C] and is in widespread use.

2.5.2.2 Iridocorneal endothelial syndrome

Iridocorneal Endothelial (ICE) Syndrome, with progressive endothelial membrane formation and progressive iridotrabecular adhesion.

Peripheral anterior synechiae, due to prolonged primary angle-closure; this is theoretically a primary angle-closure.

Treatment [II,D]:

- a) Topical and systemic IOP lowering medications as needed
- b) Filtering procedure, with antimetabolite according to risk factors
- c) Aqueous drainage device

2.5.2.3 Posterior polymorphous dystrophy

Treatment [II,D]:

- a) Topical and systemic IOP lowering medication as needed
- b) Filtering procedure, with antimetabolite according to risk factors

2.5.2.4 Epithelial and fibrous ingrowth *after* anterior segment surgery or penetrating trauma

Epithelial and fibrous ingrowth after anterior segment surgery or penetrating trauma
Inflammatory membrane.

Treatment [II,D]:

- a) Topical and systemic IOP lowering medication as needed
- b) Excision, destruction of the immigrated tissue
- c) Filtering procedure, with antimetabolite according to risk factors
- d) Aqueous drainage device
- e) Cyclodestruction

2.5.2.5 Inflammatory membrane

Treatment [II,D]:

- a) Anti-inflammatory medications and cycloplegics
- b) Topical and systemic IOP lowering medication as needed
- c) Filtering procedure with antimetabolite
- d) Aqueous drainage device
- e) Cyclodestruction

2.5.2.6 Peripheral anterior synechiae *after* ALT and endothelial membrane covering the trabecular meshwork late *after* ALT

After argon laser trabeculoplasty (ALT), early and late peripheral anterior synechiae and endothelial membrane covering the trabecular meshwork

Treatment [II,D]:

- a) Topical and systemic IOP lowering medication as needed
- b) Filtering procedure

2.5.2.7 Aniridia

Treatment [II,D]:

- a) Topical and systemic IOP lowering medication as needed
- b) Trabeculotomy

- c) Filtering procedure with antimetabolites
- d) Aqueous drainage device
- e) Cyclodestruction

2.5.3 Secondary Angle-Closure With Posterior ‘Pushing’ Mechanism Without Pupillary Block

2.5.3.1 Aqueous misdirection (also known as cilio-lenticular block, ciliary block or malignant glaucoma)

Etiology:

Angle-closure is caused by the ciliary body and iris rotating forward. Aqueous misdirection, or malignant glaucoma, is a rare type of secondary angle-closure glaucoma most commonly encountered after filtering surgery. The syndrome, also known as ciliary block glaucoma, can occur spontaneously or following any type of intraocular surgery.

Pathomechanism:

- The lens may be proportionally abnormally large or swollen, “phacomorphic glaucoma”
- Aqueous humour accumulates in the vitreous body (posterior aqueous humour misdirection) or behind and around the crystalline lens (perilenticular misdirection) or behind the iridocapsular diaphragm or posterior chamber intraocular lens (PCL) after extracapsular cataract surgery, with or without PCL implantation, “retrocapsular misdirection”
- Frequently precipitated by ocular surgery and flat anterior chamber
- Predisposition may be similar in both eyes particularly in small eyes

Treatment:

Medical treatment

- a) Parasympatholytics (atropine, cyclopentolate) both initially and for long-term pupillary dilation and cycloplegia [I,C]
- b) Aqueous production suppressants given orally and/or topically [I,D]
- c) Hyperosmotics (Ch. 3.3.1.3) [I,D]

Miotics are contraindicated!

Surgical treatment

- a) A patent iridotomy must be present or, if not present, iridotomy should be performed [I,D]
- b) YAG laser vitreolysis/capsulotomy, especially in aphakia, pseudophakia [II,C]
- c) Anterior vitrectomy, especially in aphakia, pseudophakia [II,C]
- d) Cyclo diode laser
- e) In selected cases lens extraction [II,D]

2.5.3.2 Iris and ciliary body cysts, intraocular tumors

Treatment:

- a) Tumour irradiation or excision
- b) Filtering surgery
- c) Cyclodestruction

2.5.3.3 Silicon oil or other tamponading fluids or gas implanted in the vitreous cavity¹³⁸

Treatment:

- a) Topical/systemic IOP lowering medications as needed
- b) Silicon oil or gas aspiration
- c) Filtering surgery
- d) Drainage device
- e) Cyclodestruction

2.5.3.4 Uveal effusion^{151,152}

It is due to:

- Inflammation as in scleritis, uveitis, HIV infection
- Increased choroidal venous pressure as in nanophthalmos, scleral buckling, panretinal photocoagulation, central retinal vein occlusion, arterio-venous communication
- Tumor

Treatment:

- a) Anti-inflammatory medication (for 1)
- b) Topical and systemic IOP lowering medication as needed (for 1,2 and 3)
- c) Relaxation of scleral buckling; vitrectomy, sclerectomy in nanophthalmus (for Tumor excision or irradiation (for 3)
- d) Cyclodestruction

2.5.3.5 Retinopathy of prematurity (stage V)

Features:

Signs and Symptoms:

- Variable discomfort, pain, redness, corneal oedema IOP \geq 21 mmHg
- Axially shallow anterior chamber

Treatment:

- a) Topical and systemic IOP lowering medications
- b) Cyclodestruction
- c) Filtering procedure with or without antimetabolite
- d) Drainage devices

2.5.3.6 Congenital anomalies that can be associated with secondary glaucoma

These conditions are extremely variable in pathogenesis, clinical presentation and required management; an extensive discussion is outside the scope of this chapter.

Etiology:

Familial iris hypoplasia, anomalous superficial iris vessels, aniridia, Sturge-Weber syndrome, neurofibromatosis, Marfan's syndrome, Pierre Robin syndrome, homocystinuria, goniodysgenesis, Lowe's syndrome, microcornea, microspherophakia, rubella, broad thumb syndrome, persistent hyperplastic primary vitreous.

Pathomechanism:

Angle-closure is caused by pushing forward the ciliary body and iris. Increase of volume of the posterior segment of the eye.

Features:

Signs and Symptoms:

- IOP > 21 mmHg
- Pain, redness, corneal oedema
- Axially shallow anterior chamber
- Laser iridotomy and surgical iridectomy are not effective

Some differential diagnoses:

Acute IOP elevation with corneal oedema but open-angle may result from Posner Schlossman syndrome (iridocyclitic crisis), or from endothelitis/trabeculitis as in disciform herpetic keratitis.

Neovascular glaucoma may be associated with an open or closed-angle and may mimic some signs and the symptoms of acute angle-closure.

Some differential diagnoses:

Acute IOP elevation with corneal oedema but open-angle may result from Posner Schlossman syndrome (iridocyclitic crisis), or from endothelitis/trabeculitis as in disciform herpetic keratitis.

Neovascular glaucoma may be associated with an open or closed-angle and may mimic some signs and the symptoms of acute angle-closure.

Treatment:

Treatment to be adapted to the primary anomaly, the mechanism of IOP elevation and the quality of life of the patient.

References

1. Papadopoulos M, Khaw PT. Advances in the management of paediatric glaucoma. *Eye (Lond)* 2007;21(10):1319-25.
2. Weinreb RN, Papadopoulos, M. Consensus on Childhood glaucoma. Amsterdam: Kugel publications, 2013.
3. Alsheikheh A, Klink J, Klink T, et al. Long-term results of surgery in childhood glaucoma. *Graefes Arch Clin Exp Ophthalmol* 2007;245(2):195-203.
4. Grehn F. Congenital glaucoma surgery: a neglected field in ophthalmology? *Br J Ophthalmol* 2008;92(1):1-2.
5. Papadopoulos M, Cable N, Rahi J, Khaw PT. The British Infantile and Childhood Glaucoma (BIG) Eye Study. *Invest Ophthalmol Vis Sci* 2007;48(9):4100-6.
6. Meyer G, Schwenn O, Grehn F. [Trabeculotomy in congenital glaucoma: comparison to goniotomy]. *Ophthalmologie* 2000;97(9):623-8.
7. Meyer G, Schwenn O, Pfeiffer N, Grehn F. Trabeculotomy in congenital glaucoma. *Graefes Arch Clin Exp Ophthalmol* 2000;238(3):207-13.
8. Mendicino ME, Lynch MG, Drack A, et al. Long-term surgical and visual outcomes in primary congenital glaucoma: 360 degrees trabeculotomy versus goniotomy. *J AAPOS* 2000;4(4):205-10.
9. Beck AD, Lynch MG. 360 degrees trabeculotomy for primary congenital glaucoma. *Arch Ophthalmol* 1995;113(9):1200-2.
10. Beck AD, Lynn MJ, Crandall J, Mobin-Uddin O. Surgical outcomes with 360-degree suture trabeculotomy in poor-prognosis primary congenital glaucoma and glaucoma associated with congenital anomalies or cataract surgery. *J AAPOS* 2011;15(1):54-8.
11. Girkin CA, Rhodes L, McGwin G, et al. Goniotomy versus circumferential trabeculotomy with an illuminated microcatheter in congenital glaucoma. *J AAPOS* 2012;16(5):424-7.
12. Rabiah PK. Frequency and predictors of glaucoma after pediatric cataract surgery. *Am J Ophthalmol* 2004;137(1):30-7.
13. Swamy BN, Billson F, Martin F, et al. Secondary glaucoma after paediatric cataract surgery. *Br J Ophthalmol* 2007;91(12):1627-30.
14. Tielsch JM, Katz J, Singh K, et al. A population-based evaluation of glaucoma screening: the Baltimore Eye Survey. *Am J Epidemiol* 1991;134(10):1102-10.
15. Klein BE, Klein R, Sponsel WE, et al. Prevalence of glaucoma. The Beaver Dam Eye Study. *Ophthalmology* 1992;99(10):1499-504.
16. Dielemans I, Vingerling JR, Wolfs RC, et al. The prevalence of primary open-angle glaucoma in a population-based study in The Netherlands. The Rotterdam Study. *Ophthalmology* 1994;101(11):1851-5.
17. Mitchell P, Smith W, Attebo K, Healey PR. Prevalence of open-angle glaucoma in Australia. The Blue Mountains Eye Study. *Ophthalmology* 1996;103(10):1661-9.
18. Leske MC, Connell AM, Schachat AP, Hyman L. The Barbados Eye Study. Prevalence of open angle glaucoma. *Arch Ophthalmol* 1994;112(6):821-9.
19. Weih LM, Nanjan M, McCarty CA, Taylor HR. Prevalence and predictors of open-angle glaucoma: results from the visual impairment project. *Ophthalmology* 2001;108(11):1966-72.
20. Quigley HA, West SK, Rodriguez J, et al. The prevalence of glaucoma in a population-based study of Hispanic subjects: Proyecto VER. *Arch Ophthalmol* 2001;119(12):1819-26.
21. Dandona L, Dandona R, Srinivas M, et al. Open-angle glaucoma in an urban

- population in Southern India: the Andhra Pradesh eye disease study. *Ophthalmology* 2000;107(9):1702-9.
22. Iwase A, Suzuki Y, Araie M, et al. The prevalence of primary open-angle glaucoma in Japanese: the Tajimi Study. *Ophthalmology* 2004;111(9):1641-8.
 23. Varma R, Ying-Lai M, Francis BA, et al. Prevalence of open-angle glaucoma and ocular hypertension in Latinos: the Los Angeles Latino Eye Study. *Ophthalmology* 2004;111(8):1439-48.
 24. Topouzis F, Wilson MR, Harris A, et al. Prevalence of open-angle glaucoma in Greece: the Thessaloniki Eye Study. *Am J Ophthalmol* 2007;144(4):511-9.
 25. Shen SY, Wong TY, Foster PJ, et al. The prevalence and types of glaucoma in Malay people: the Singapore Malay eye study. *Invest Ophthalmol Vis Sci* 2008;49(9):3846-51.
 26. Coleman AL, Miglior S. Risk factors for glaucoma onset and progression. *Surv Ophthalmol* 2008;53 Suppl1:S3-10.
 27. Le A, Mukesh BN, McCarty CA, Taylor HR. Risk factors associated with the incidence of open-angle glaucoma: the visual impairment project. *Invest Ophthalmol Vis Sci* 2003;44(9):3783-9.
 28. Czudowska MA, Ramdas WD, Wolfs RC, et al. Incidence of glaucomatous visual field loss: a ten-year follow-up from the Rotterdam Study. *Ophthalmology* 2010;117(9):1705-12.
 29. Leske MC, Wu SY, Hennis A, et al. Risk factors for incident open-angle glaucoma: the Barbados Eye Studies. *Ophthalmology* 2008;115(1):85-93.
 30. Jiang X, Varma R, Wu S, et al. Baseline risk factors that predict the development of open-angle glaucoma in a population: the Los Angeles Latino Eye Study. *Ophthalmology* 2012;119(11):2245-53.
 31. Leske MC, Connell AM, Wu SY, et al. Risk factors for open-angle glaucoma. The Barbados Eye Study. *Arch Ophthalmol* 1995;113(7):918-24.
 32. Nemesure B, Honkanen R, Hennis A, et al. Incident open-angle glaucoma and intraocular pressure. *Ophthalmology* 2007;114(10):1810-5.
 33. Mason RP, Kosoko O, Wilson MR, et al. National survey of the prevalence and risk factors of glaucoma in St. Lucia, West Indies. Part I. Prevalence findings. *Ophthalmology* 1989;96(9):1363-8.
 34. Tielsch JM, Sommer A, Katz J, et al. Racial variations in the prevalence of primary open-angle glaucoma. The Baltimore Eye Survey. *JAMA* 1991;266(3):369-74.
 35. Varma R, Wang D, Wu C, et al. Four-year incidence of open-angle glaucoma and ocular hypertension: the Los Angeles Latino Eye Study. *Am J Ophthalmol* 2012;154(2):315-25 e1.
 36. Wolfs RC, Klaver CC, Ramrattan RS, et al. Genetic risk of primary open-angle glaucoma. Population-based familial aggregation study. *Arch Ophthalmol* 1998;116(12):1640-5.
 37. Leske MC, Nemesure B, He Q, et al. Patterns of open-angle glaucoma in the Barbados Family Study. *Ophthalmology* 2001;108(6):1015-22.
 38. McCarty CA, Taylor HR. Pseudoexfoliation syndrome in Australian adults. *Am J Ophthalmol* 2000;129(5):629-33.
 39. Mitchell P, Wang JJ, Hourihan F. The relationship between glaucoma and pseudoexfoliation: the Blue Mountains Eye Study. *Arch Ophthalmol* 1999;117(10):1319-24.
 40. Astrom S, Linden C. Incidence and prevalence of pseudoexfoliation and open-angle glaucoma in Northern Sweden: I. Baseline report. *Acta Ophthalmol Scand* 2007;85(8):828-31.
 41. Hirvela H, Luukinen H, Laatikainen L. Prevalence and risk factors of lens opacities in the elderly in Finland. A population-based study. *Ophthalmology* 1995;102(1):108-17.
 42. Arvind H, Raju P, Paul PG, et al. Pseudoexfoliation in South India. *Br J Ophthalmol* 2003;87(11):1321-3.

43. Arnarsson A, Damji KF, Sverrisson T, et al. Pseudoexfoliation in the Reykjavik Eye Study: prevalence and related ophthalmological variables. *Acta Ophthalmol Scand* 2007;85(8):822-7.
44. Krishnadas R, Nirmalan PK, Ramakrishnan R, et al. Pseudoexfoliation in a rural population of Southern India: the Aravind Comprehensive Eye Survey. *Am J Ophthalmol* 2003;135(6):830-7.
45. Thomas R, Nirmalan PK, Krishnaiah S. Pseudoexfoliation in Southern India: the Andhra Pradesh Eye Disease Study. *Invest Ophthalmol Vis Sci* 2005;46(4):1170-6.
46. Ringvold A, Blika S, Elsas T, et al. The middle-Norway eye-screening study. II. Prevalence of simple and capsular glaucoma. *Acta Ophthalmol (Copenh)* 1991;69(3):273-80.
47. Topouzis F, Wilson MR, Harris A, et al. Risk factors for primary open-angle glaucoma and pseudoexfoliative glaucoma in the Thessaloniki eye study. *Am J Ophthalmol* 2011;152(2):219-28 e1.
48. Gordon MO, Beiser JA, Brandt JD, et al. The Ocular Hypertension Treatment Study: baseline factors that predict the onset of primary open-angle glaucoma. *Arch Ophthalmol* 2002;120(6):714-20; discussion 829-30.
49. Mitchell P, Hourihan F, Sandbach J, Wang JJ. The relationship between glaucoma and myopia: the Blue Mountains Eye Study. *Ophthalmology* 1999;106(10):2010-5.
50. Attebo K, Ivers RQ, Mitchell P. Refractive errors in an older population: the Blue Mountains Eye Study. *Ophthalmology* 1999;106(6):1066-72.
51. Kuzin AA, Varma R, Reddy HS, et al. Ocular biometry and open-angle glaucoma: the Los Angeles Latino Eye Study. *Ophthalmology* 2010;117(9):1713-9.
52. Xu L, Wang Y, Wang S, Jonas JB. High myopia and glaucoma susceptibility the Beijing Eye Study. *Ophthalmology* 2007;114(2):216-20.
53. Grodum K, Heijl A, Bengtsson B. Refractive error and glaucoma. *Acta Ophthalmol Scand* 2001;79(6):560-6.
54. Wong TY, Klein BE, Klein R, et al. Refractive errors, intraocular pressure, and glaucoma in a white population. *Ophthalmology* 2003;110(1):211-7.
55. Perera SA, Wong TY, Tay WT, et al. Refractive error, axial dimensions, and primary open-angle glaucoma: the Singapore Malay Eye Study. *Arch Ophthalmol* 2010;128(7):900-5.
56. Hulsman CA, Vingerling JR, Hofman A, et al. Blood pressure, arterial stiffness, and open-angle glaucoma: the Rotterdam study. *Arch Ophthalmol* 2007;125(6):805-12.
57. Bonomi L, Marchini G, Marraffa M, et al. Vascular risk factors for primary open angle glaucoma: the Egna-Neumarkt Study. *Ophthalmology* 2000;107(7):1287-93.
58. Tielsch JM, Katz J, Sommer A, et al. Hypertension, perfusion pressure, and primary open-angle glaucoma. A population-based assessment. *Arch Ophthalmol* 1995;113(2):216-21.
59. Memarzadeh F, Ying-Lai M, Chung J, et al. Blood pressure, perfusion pressure, and open-angle glaucoma: the Los Angeles Latino Eye Study. *Invest Ophthalmol Vis Sci* 2010;51(6):2872-7.
60. Zheng Y, Wong TY, Mitchell P, et al. Distribution of ocular perfusion pressure and its relationship with open-angle glaucoma: the singapore malay eye study. *Invest Ophthalmol Vis Sci* 2010;51(7):3399-404.
61. Topouzis F, Wilson MR, Harris A, et al. Association of open-angle glaucoma with perfusion pressure status in the Thessaloniki Eye Study. *Am J Ophthalmol* 2013;155(5):843-51.
62. Gherghel D, Orgul S, Gugleta K, et al. Relationship between ocular perfusion pressure and retrobulbar blood flow in patients with glaucoma with progressive damage. *Am J Ophthalmol* 2000;130(5):597-605.

63. Flammer J, Orgul S, Costa VP, et al. The impact of ocular blood flow in glaucoma. *Prog Retin Eye Res* 2002;21(4):359-93.
64. Grieshaber MC, Mozaffarieh M, Flammer J. What is the link between vascular dysregulation and glaucoma? *Surv Ophthalmol* 2007;52 Suppl 2:S144-54.
65. Sommer A. Glaucoma risk factors observed in the Baltimore Eye Survey. *Curr Opin Ophthalmol* 1996;7(2):93-8.
66. Leske MC, Wu SY, Nemesure B, Hennis A. Incident open-angle glaucoma and blood pressure. *Arch Ophthalmol* 2002;120(7):954-9.
67. Topouzis F, Founti P. Weighing in ocular perfusion pressure in managing glaucoma. *Open Ophthalmol J* 2009;3:43-5.
68. Caprioli J, Coleman AL. Blood pressure, perfusion pressure, and glaucoma. *Am J Ophthalmol* 2010;149(5):704-12.
69. Khawaja AP, Crabb DP, Jansonius NM. The role of ocular perfusion pressure in glaucoma cannot be studied with multivariable regression analysis applied to surrogates. *Invest Ophthalmol Vis Sci* 2013;54(7):4619-20.
70. Miglior S, Zeyen T, Pfeiffer N, et al. Results of the European Glaucoma Prevention Study. *Ophthalmology* 2005;112(3):366-75.
71. Gordon MO, Torri V, Miglior S, et al. Validated prediction model for the development of primary open-angle glaucoma in individuals with ocular hypertension. *Ophthalmology* 2007;114(1):10-9.
72. Leske MC, Heijl A, Hyman L, et al. Predictors of long-term progression in the early manifest glaucoma trial. *Ophthalmology* 2007;114(11):1965-72.
73. Nouri-Mahdavi K, Hoffman D, Coleman AL, et al. Predictive factors for glaucomatous visual field progression in the Advanced Glaucoma Intervention Study. *Ophthalmology* 2004;111(9):1627-35.
74. Musch DC, Gillespie BW, Lichter PR, et al. Visual field progression in the Collaborative Initial Glaucoma Treatment Study the impact of treatment and other baseline factors. *Ophthalmology* 2009;116(2):200-7.
75. The effectiveness of intraocular pressure reduction in the treatment of normal-tension glaucoma. Collaborative Normal-Tension Glaucoma Study Group. *Am J Ophthalmol* 1998;126(4):498-505.
76. Heijl A, Bengtsson B, Hyman L, Leske MC. Natural history of open-angle glaucoma. *Ophthalmology* 2009;116(12):2271-6.
77. Leske MC, Heijl A, Hussein M, et al. Factors for glaucoma progression and the effect of treatment: the early manifest glaucoma trial. *Arch Ophthalmol* 2003;121(1):48-56.
78. Bengtsson B, Leske MC, Hyman L, Heijl A. Fluctuation of intraocular pressure and glaucoma progression in the early manifest glaucoma trial. *Ophthalmology* 2007;114(2):205-9.
79. Caprioli J, Coleman AL. Intraocular pressure fluctuation a risk factor for visual field progression at low intraocular pressures in the advanced glaucoma intervention study. *Ophthalmology* 2008;115(7):1123-9 e3.
80. Bengtsson B, Heijl A. Diurnal IOP fluctuation: not an independent risk factor for glaucomatous visual field loss in high-risk ocular hypertension. *Graefes Arch Clin Exp Ophthalmol* 2005;243(6):513-8.
81. Bengtsson B, Leske MC, Yang Z, Heijl A. Disc hemorrhages and treatment in the early manifest glaucoma trial. *Ophthalmology* 2008;115(11):2044-8.
82. Hollands H, Johnson D, Hollands S, et al. Do findings on routine examination identify patients at risk for primary open-angle glaucoma? The rational clinical examination systematic review. *JAMA* 2013;309(19):2035-42.

83. Miglior S, Torri V, Zeyen T, et al. Intercurrent factors associated with the development of open-angle glaucoma in the European glaucoma prevention study. *Am J Ophthalmol* 2007;144(2):266-75.
84. Kim SH, Park KH. The relationship between recurrent optic disc hemorrhage and glaucoma progression. *Ophthalmology* 2006;113(4):598-602.
85. Ritch R, Schlotzer-Schrehardt U, Konstas AG. Why is glaucoma associated with exfoliation syndrome? *Prog Retin Eye Res* 2003;22(3):253-75.
86. Holló G, Konstas AGP. *Exfoliation syndrome and exfoliative glaucoma*, 2nd ed. Savona (IT): Publicomm S.r.l., 2012.
87. Topouzis F, Coleman AL, Harris A, et al. Factors associated with undiagnosed open-angle glaucoma: the Thessaloniki Eye Study. *Am J Ophthalmol* 2008;145(2):327-35.
88. Visontai Z, Merisch B, Kollai M, Hollo G. Increase of carotid artery stiffness and decrease of baroreflex sensitivity in exfoliation syndrome and glaucoma. *Br J Ophthalmol* 2006;90(5):563-7.
89. Anastasopoulos E, Topouzis F, Wilson MR, et al. Characteristics of pseudoexfoliation in the Thessaloniki Eye Study. *J Glaucoma* 2011;20(3):160-6.
90. French DD, Margo CE, Harman LE. Ocular pseudoexfoliation and cardiovascular disease: a national cross-section comparison study. *N Am J Med Sci* 2012;4(10):468-73.
91. Tarkkanen A, Reunanen A, Kivela T. Frequency of systemic vascular diseases in patients with primary open-angle glaucoma and exfoliation glaucoma. *Acta Ophthalmol* 2008;86(6):598-602.
92. Traverso CE, Spaeth GL, Starita RJ, et al. Factors affecting the results of argon laser trabeculoplasty in open-angle glaucoma. *Ophthalmic Surg* 1986;17(9):554-9.
93. Arnarsson A, Sasaki H, Jonasson F. Twelve-year Incidence of Exfoliation Syndrome in the Reykjavik Eye Study. *Acta Ophthalmol* 2013;91(2):157-62.
94. Gottanka J, Johnson DH, Grehn F, Lutjen-Drecoll E. Histologic findings in pigment dispersion syndrome and pigmentary glaucoma. *J Glaucoma* 2006;15(2):142-51.
95. Carassa RG, Bettin P, Fiori M, Brancato R. Nd:YAG laser iridotomy in pigment dispersion syndrome: an ultrasound biomicroscopic study. *Br J Ophthalmol* 1998;82(2):150-3.
96. Liu L, Ong EL, Crowston J. The concave iris in pigment dispersion syndrome. *Ophthalmology* 2011;118(1):66-70.
97. Yang JW, Sakiyalak D, Krupin T. Pigmentary glaucoma. *J Glaucoma* 2001;10(5 Suppl 1):S30-2.
98. Siddiqui Y, Ten Hulzen RD, Cameron JD, et al. What is the risk of developing pigmentary glaucoma from pigment dispersion syndrome? *Am J Ophthalmol* 2003;135(6):794-9.
99. Niyadurupola N, Broadway DC. Pigment dispersion syndrome and pigmentary glaucoma - a major review. *Clin Experiment Ophthalmol* 2008;36(9):868-82.
100. Ayala M. Long-term Outcomes of Selective Laser Trabeculoplasty (SLT) Treatment in Pigmentary Glaucoma Patients. *J Glaucoma* 2013.
101. Reistad CE, Shields MB, Campbell DG, et al. The influence of peripheral iridotomy on the intraocular pressure course in patients with pigmentary glaucoma. *J Glaucoma* 2005;14(4):255-9.
102. Suner IJ, Greenfield DS, Miller MP, et al. Hypotony maculopathy after filtering surgery with mitomycin C. Incidence and treatment. *Ophthalmology* 1997;104(2):207-14; discussion 14-5.
103. Jensen PK, Nissen O, Kessing SV. Exercise and reversed pupillary block in pigmentary glaucoma. *Am J Ophthalmol* 1995;120(1):110-2.

104. Papaconstantinou D, Georgalas I, Kourtis N, et al. Lens-induced glaucoma in the elderly. *Clin Interv Aging* 2009;4:331-6.
105. Sihota R, Kumar S, Gupta V, et al. Early predictors of traumatic glaucoma after closed globe injury: trabecular pigmentation, widened angle recess, and higher baseline intraocular pressure. *Arch Ophthalmol* 2008;126(7):921-6.
106. Rahmani B, Jahadi HR. Comparison of tranexamic acid and prednisolone in the treatment of traumatic hyphema. A randomized clinical trial. *Ophthalmology* 1999;106(2):375-9.
107. Gharaibeh A, Savage HI, Scherer RW, et al. Medical interventions for traumatic hyphema. *Cochrane Database Syst Rev* 2011(1):CD005431.
108. Siddique SS, Suelves AM, Baheti U, Foster CS. Glaucoma and uveitis. *Surv Ophthalmol* 2013;58(1):1-10.
109. Horsley MB, Chen TC. The use of prostaglandin analogs in the uveitic patient. *Semin Ophthalmol* 2011;26(4-5):285-9.
110. Dupas B, Fardeau C, Cassoux N, et al. Deep sclerectomy and trabeculectomy in uveitic glaucoma. *Eye (Lond)* 2010;24(2):310-4.
111. Iwao K, Inatani M, Seto T, et al. Long-term Outcomes and Prognostic Factors for Trabeculectomy With Mitomycin C in Eyes With Uveitic Glaucoma: A Retrospective Cohort Study. *J Glaucoma* 2012.
112. Radcliffe NM, Finger PT. Eye cancer related glaucoma: current concepts. *Surv Ophthalmol* 2009;54(1):47-73.
113. Gedde SJ. Management of glaucoma after retinal detachment surgery. *Curr Opin Ophthalmol* 2002;13(2):103-9.
114. Bai HQ, Yao L, Wang DB, et al. Causes and treatments of traumatic secondary glaucoma. *Eur J Ophthalmol* 2009;19(2):201-6.
115. Detry-Morel M, Escarmelle A, Hermans I. Refractory ocular hypertension secondary to intravitreal injection of triamcinolone acetonide. *Bull Soc Belge Ophthalmol* 2004(292):45-51.
116. Jones R, 3rd, Rhee DJ. Corticosteroid-induced ocular hypertension and glaucoma: a brief review and update of the literature. *Curr Opin Ophthalmol* 2006;17(2):163-7.
117. Mangouritsas G, Mourtzoukos S, Portaliou DM, et al. Glaucoma associated with the management of rhegmatogenous retinal detachment. *Clin Ophthalmol* 2013;7:727-34.
118. Lalezary M, Kim SJ, Jiramongkolchai K, et al. Long-term trends in intraocular pressure after pars plana vitrectomy. *Retina* 2011;31(4):679-85.
119. Ichhpujani P, Jindal A, Jay Katz L. Silicone oil induced glaucoma: a review. *Graefes Arch Clin Exp Ophthalmol* 2009;247(12):1585-93.
120. Nassr MA, Morris CL, Netland PA, Karcioğlu ZA. Intraocular pressure change in orbital disease. *Surv Ophthalmol* 2009;54(5):519-44.
121. Liebmann JMR, R. Complications of glaucoma surgery. In: Mosby SL, ed. Ritch R, Shields MB, Krupin T *The Glaucomas* 1986.
122. Simmons RJM, F.A. Malignant Glaucoma. In: Mosby SL, ed. Ritch, R Shields, MB Krupin, T: *The Glaucomas* 1996.
123. Foster PJ, Buhmann R, Quigley HA, Johnson GJ. The definition and classification of glaucoma in prevalence surveys. *Br J Ophthalmol* 2002;86(2):238-42.
124. Foster PJ, Johnson GJ. Glaucoma in China: how big is the problem? *Br J Ophthalmol* 2001;85(11):1277-82.
125. Congdon N, Wang F, Tielsch JM. Issues in the epidemiology and population-based screening of primary angle-closure glaucoma. *Surv Ophthalmol* 1992;36(6):411-23.
126. Day AC, Baio G, Gazzard G, et al. The prevalence of primary angle closure

- glaucoma in European derived populations: a systematic review. *Br J Ophthalmol* 2012;96(9):1162-7.
127. De Silva DJ, Gazzard G, Foster P. Laser iridotomy in dark irides. *Br J Ophthalmol* 2007;91(2):222-5.
 128. Foster PJ, Aung T, Nolan WP, et al. Defining "occludable" angles in population surveys: drainage angle width, peripheral anterior synechiae, and glaucomatous optic neuropathy in East Asian people. *Br J Ophthalmol* 2004;88(4):486-90.
 129. Becker B, Shaffer RN. *Diagnosis and therapy of the glaucomas*. St. Louis: C. V. Mosby Co., 1961; 360 p.
 130. Friedman DSW, R. N. Consensus on Angle-closure and Angle-closure Glaucoma. AIGS/WGA Consensus Series 2008.
 131. Salmon JF. Long-Term Intraocular Pressure Control After Nd-YAG Laser Iridotomy in Chronic Angle-Closure Glaucoma. *J Glaucoma* 1993;2(4):291-6.
 132. Mapstone R. Provocative tests in closed-angle glaucoma. *Br J Ophthalmol* 1976;60(2):115-9.
 133. He M, Friedman DS, Ge J, et al. Laser peripheral iridotomy in eyes with narrow drainage angles: ultrasound biomicroscopy outcomes. The Liwan Eye Study. *Ophthalmology* 2007;114(8):1513-9.
 134. Ritch R. Plateau Iris Is Caused by Abnormally Positioned Ciliary Processes. *J Glaucoma* 1992;1(1):23-6.
 135. Wand M, Grant WM, Simmons RJ, Hutchinson BT. Plateau iris syndrome. *Trans Sect Ophthalmol Am Acad Ophthalmol Otolaryngol* 1977;83(1):122-30.
 136. Lowe RF. Primary Angle-Closure Glaucoma. Family Histories and Anterior Chamber Depths. *Br J Ophthalmol* 1964;48:191-5.
 137. Lachkar Y, Bouassida W. Drug-induced acute angle closure glaucoma. *Curr Opin Ophthalmol* 2007;18(2):129-33.
 138. Tanihara H, Nishiwaki K, Nagata M. Surgical results and complications of goniosynechialysis. *Graefes Arch Clin Exp Ophthalmol* 1992;230(4):309-13.
 139. Lam DS, Chua JK, Tham CC, Lai JS. Efficacy and safety of immediate anterior chamber paracentesis in the treatment of acute primary angle-closure glaucoma: a pilot study. *Ophthalmology* 2002;109(1):64-70.
 140. Lai JS, Tham CC, Chua JK, et al. To compare argon laser peripheral iridoplasty (ALPI) against systemic medications in treatment of acute primary angle-closure: mid-term results. *Eye (Lond)* 2006;20(3):309-14.
 141. Ritch R, Tham CC, Lam DS. Argon laser peripheral iridoplasty (ALPI): an update. *Surv Ophthalmol* 2007;52(3):279-88.
 142. Arnavielle S, Creuzot-Garcher C, Bron AM. Anterior chamber paracentesis in patients with acute elevation of intraocular pressure. *Graefes Arch Clin Exp Ophthalmol* 2007;245(3):345-50.
 143. Greve EL. Primary angle closure glaucoma: extracapsular cataract extraction or filtering procedure? *Int Ophthalmol* 1988;12(3):157-62.
 144. Tarongoy P, Ho CL, Walton DS. Angle-closure glaucoma: the role of the lens in the pathogenesis, prevention, and treatment. *Surv Ophthalmol* 2009;54(2):211-25.
 145. Lai JS, Tham CC, Chan JC. The clinical outcomes of cataract extraction by phacemulsification in eyes with primary angle-closure glaucoma (PACG) and co-existing cataract: a prospective case series. *J Glaucoma* 2006;15(1):47-52.
 146. Husain R, Gazzard G, Aung T, et al. Initial management of acute primary angle closure:

- a randomized trial comparing phacoemulsification with laser peripheral iridotomy. *Ophthalmology* 2012;119(11):2274-81.
147. Azuara-Blanco A, Burr JM, Cochran C, et al. The effectiveness of early lens extraction with intraocular lens implantation for the treatment of primary angle-closure glaucoma (EAGLE): study protocol for a randomized controlled trial. *Trials* 2011;12:133.
 148. Tham CC, Kwong YY, Leung DY, et al. Phacoemulsification vs phacotrabeculectomy in chronic angle-closure glaucoma with cataract: complications [corrected]. *Arch Ophthalmol* 2010;128(3):303-11.
 149. Ritch R, Tham CC, Lam DS. Long-term success of argon laser peripheral iridoplasty in the management of plateau iris syndrome. *Ophthalmology* 2004;111(1):104-8.
 150. Traverso CE, Tomey KF, Gandolfo E. The glaucomas in pseudophakia. *Curr Opin Ophthalmol* 1996;7(2):65-71.
 151. Nash RW, Lindquist TD. Bilateral angle-closure glaucoma associated with uveal effusion: presenting sign of HIV infection. *Surv Ophthalmol* 1992;36(4):255-8.
 152. Moorthy RS, Mermoud A, Baerveldt G, et al. Glaucoma associated with uveitis. *Surv Ophthalmol* 1997;41(5):361-94.



CHAPTER 3

Treatment Principles and Options

Treatment Principles and Options

3

3.1 - GENERAL PRINCIPLES OF GLAUCOMA TREATMENT

The purpose of this chapter is to give a summary overview and it is not meant to be an all-inclusive text

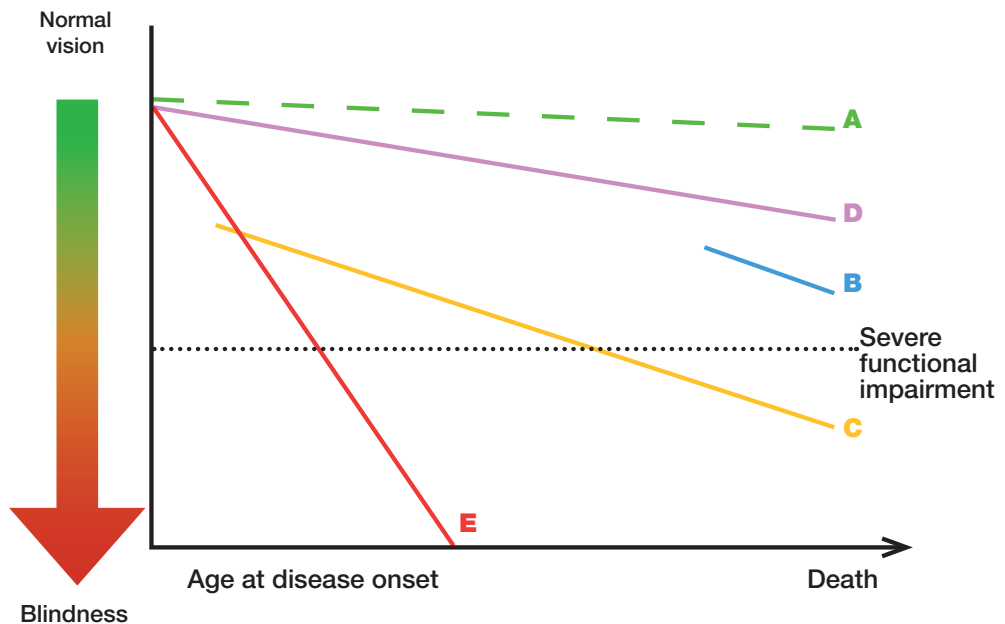


Figure 3.1. THE WHOM-TO-TREAT GRAPH The rate of ganglion cell loss and resulting functional decay is very different among different glaucoma eyes. Quality of life is clearly reduced when visual field defects become severe, cf. the severe functional impairment. Line A represents the effect of aging alone. In glaucoma loss of visual function is often much more rapid. An older patient, diagnosed late in life, with a moderate rate of progression (B) has a much lower risk of developing severe functional impairment than a younger patient with the same amount of field loss at diagnosis and rate of progression (C). A very slow rate of progression may be tolerated by the patient and treatment left unchanged (D), while a rapid rate of progression (E) needs a considerably lower target pressure.

It needs to be remembered that it is the extent of binocular visual field or the field of the better eye that largely determines the patient's quality of life, while the rates of progression of each eye separately are needed to determine treatment.

To assess the likely Rate of Progression (RoP) is an important part of patient management and the measured rate is a very important factor that should determine target pressure and treatment intensity (See Ch. Introduction) [1, D]. Many studies have found that progression is usually linear¹⁻⁴, but the goal of intensifying treatment is to decrease rate of progression.

Please observe that perimetric printouts of progression using the MD or VFI indices are age-corrected, so that a normal eye would not show any age-related deterioration over time.

The goal of glaucoma treatment is to maintain the patient's visual function and related quality of life, at a sustainable cost. The cost of treatment in terms of inconvenience and side effects as well as financial implications for the individual and society requires careful evaluation (See Ch. Introduction). Quality of life is closely linked with visual function and, overall, patients with early to moderate glaucoma damage have good visual function and modest reduction in quality of life, while quality of life is considerably reduced if both eyes have advanced visual function loss.

Glaucoma is still a leading cause of blindness in Europe. A considerable percentage of glaucoma patients become blind in both eyes or encounter serious field loss in both eyes⁵⁻⁷. Major risk factors for glaucoma blindness are the severity of the disease at presentation and life expectancy^{8,9}. A 60-year-old patient with bilateral moderate visual function damage at diagnosis has a greater risk of blindness than an 85-year-old patient with a similar amount of damage. Similarly a young patient with mild bilateral damage is at much larger risk of disability in his lifetime than an 80-year-old patient with moderate unilateral disease. Thus, treatment must be individualised to the needs and rate of progression (RoP) of each patient (See Fig. 1 Ch. Introduction) [I,D]. The risk of ever encountering loss of quality of life from glaucoma should determine target pressure, intensity of treatment, and frequency of follow-up [I,D].

Thus, patients with severe functional loss or younger patients with manifest disease should have more aggressive treatment and closer follow-up than patients with little or no risk, e.g., very old patients with early field loss or unilateral disease [I,D]. Glaucoma suspects, e.g., patients with elevated IOP and otherwise normal findings, have even smaller risks.

In most patients with advanced glaucoma and reasonable life expectancy, aggressive IOP lowering treatment might be recommended^{10,11} [I,D]. Very old patients with mild loss, relatively low IOP levels and significant health problems, might prefer being followed without treatment (See also Ch. Introduction) [II,D]. When treatment options are discussed with a patient, his general health status and personal preferences must be considered and respected. It is also important to ensure that patients are able to comply and persist with therapy [I,D].

Disease progression rates (RoP) in POAG, the most common form of glaucoma differ very much between patients, from rapid to very slow¹²⁻¹⁶. This makes it necessary to determine the RoP in patients with manifest glaucoma (See Fig. 1 Ch. Introduction) [I,D]. Many patients with POAG/NTG show no or only small deterioration despite years of follow-up^{17,18}, while rapid progression is common in others, e.g. in exfoliation glaucoma¹⁸. Glaucoma patients may continue to show progression despite treatment, even with IOP levels within the statistically normal range. Relying on tonometry alone for glaucoma follow-up is, therefore, insufficient regardless of IOP level^{17,18}.

Determining the rate of visual field progression is a new standard in glaucoma care. The EGS recommends three visual field tests per year for the first two years after

diagnosis to make it possible to identify rapidly progressing patients [II,D]. After two years of perimetric monitoring without progression being detected the frequency of tests may be reduced [II,D].

Once the progression rate has been determined the target pressure is re-evaluated and be based on the measured rate of progression and IOP values measured during the follow-up time [II,D]. Risk factors are then less important than at diagnosis (See Ch. 2.2).

Individualized glaucoma treatment aims at providing glaucoma management tailored to the individual needs of the patient; patients with severe functional loss or younger patients with manifest disease should have more aggressive treatment and closer follow-up than patients with little or no risk, e.g., patients with ocular hypertension or elderly patients with mild field loss and low IOP levels¹⁹⁻²³ [I,D]. (See FC VI)

In most Western countries approximately half of patients with manifest glaucoma are undiagnosed²⁴⁻²⁷, and glaucoma is often diagnosed late⁸. Improved case finding and possibly screening of high risk groups are necessary to allow diagnosis at earlier disease stages. Screening options for high risk groups should be evaluated. To discover and treat those at risk of losing functionally significant vision is a more important goal for effective glaucoma management than widespread treatment of patients with ocular hypertension.

Currently, the only approach proven to be efficient in preserving visual function is lowering IOP²⁸⁻³¹ (See Ch. Introduction and FC VI to XI) [I,A]. Other possible treatment areas have been investigated, including ocular blood flow and neuroprotection. There are experimental as well population based studies indicating that perfusion pressure may be relevant in glaucoma³¹⁻³⁷ but very difficult to measure³⁸ a specific glaucoma phenotype characterised by vascular dysregulation has been described^{32,33}. An increase of IOP will lead to a reduction of perfusion pressure. Blood pressure levels may also be important in glaucoma^{17,36,37}. However, there is no conclusive evidence to support the idea that perfusion pressure can be increased by manipulating blood pressure or ocular blood flow in glaucoma patients.

Neuroprotection can be defined as a “therapeutic approach” aiming to directly prevent, hinder and, in some cases, reverse neuronal cell damage. Since glaucoma patients can continue deteriorating in spite of an apparently well controlled IOP, the need for effective non-IOP related treatments is widely acknowledged. Several compounds have been shown to be neuroprotective in animal models of experimental glaucoma³⁹⁻⁴³.

So far, no compound has reached a sufficient level of evidence to be considered as a neuroprotectant in humans. A large long-term randomized trial using a neuroprotective agent, memantine, was analysed several years ago, but with negative results. A more recent study claiming that topical brimonidine might have neuro-protective properties in glaucoma patients, has been questioned in a systematic review on neuroprotection in glaucoma^{44,45}.

In most western countries, approximately half of patients with manifest glaucoma are undiagnosed²⁴⁻²⁷.

3.2 - TARGET IOP AND QUALITY OF LIFE

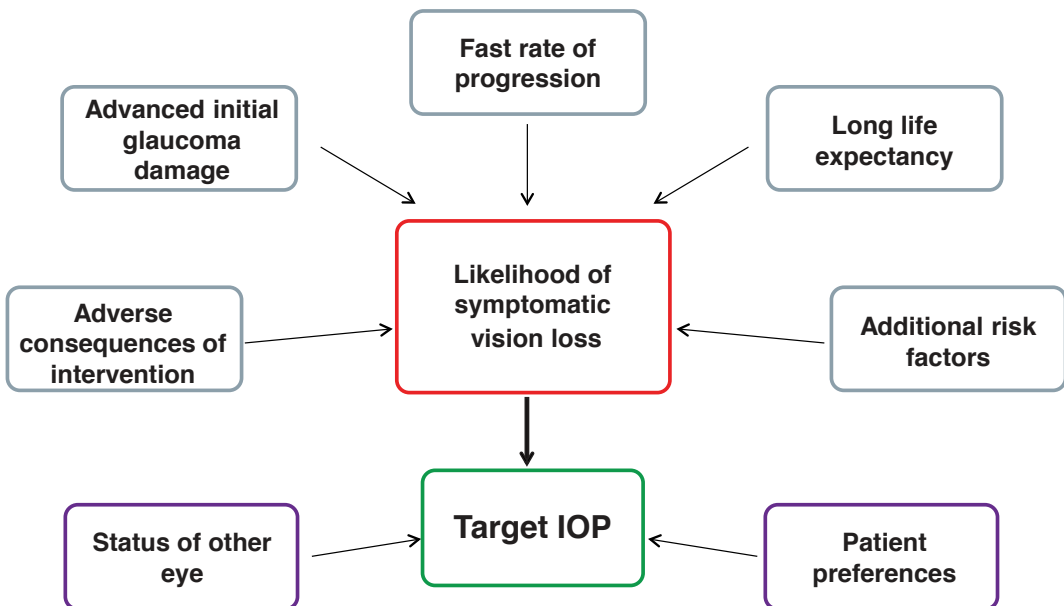
3.2.1 Target Intraocular Pressure (Target IOP)

Therapy in glaucoma management aims to lower IOP to slow the rate of visual field deterioration.

Target IOP is the upper limit of the IOP estimated to be compatible with a rate of progression sufficiently slow to maintain vision-related quality of life in the expected lifetime of the patient. It should be re-evaluated regularly and, additionally, when progression of disease is identified or when ocular or systemic comorbidities develop [II,D].

There is no single Target IOP level that is appropriate for every patient, so the Target IOP needs to be estimated separately for each eye of every patient (See FC IX and X) [II,D].

FC IX - Considerations on Target IOP



The treatment target is a compromise between reducing the risk of symptomatic vision loss and the consequences of therapy. Patient preferences should be taken into account.

Factors to consider when setting the Target IOP include^{19, 28, 46} [I,D]:

- Stage of glaucoma
 - The greater the pre-existing glaucoma damage, the lower the Target IOP should be
- IOP level before treatment
 - The lower the untreated IOP levels, the lower the Target IOP should be
- Age and life expectancy
 - Whilst younger age implies greater life expectancy and, therefore, a lower Target IOP, older age is a risk factor for more rapid progression
- Rate of progression during follow-up
 - The faster the rate of progression, the lower the Target IOP should be
- The presence of other risk factors, e.g., exfoliation syndrome
- The side effects and risks of treatment
- Patient preference

When taking the IOP reading, it is advisable to consider CCT [I,C].

Several clinical studies have identified that worse initial visual field loss is the most important predictor of blindness from glaucoma^{7, 47-49}. When considering the Target IOP for one eye, the vision status of the other eye should be taken into account.

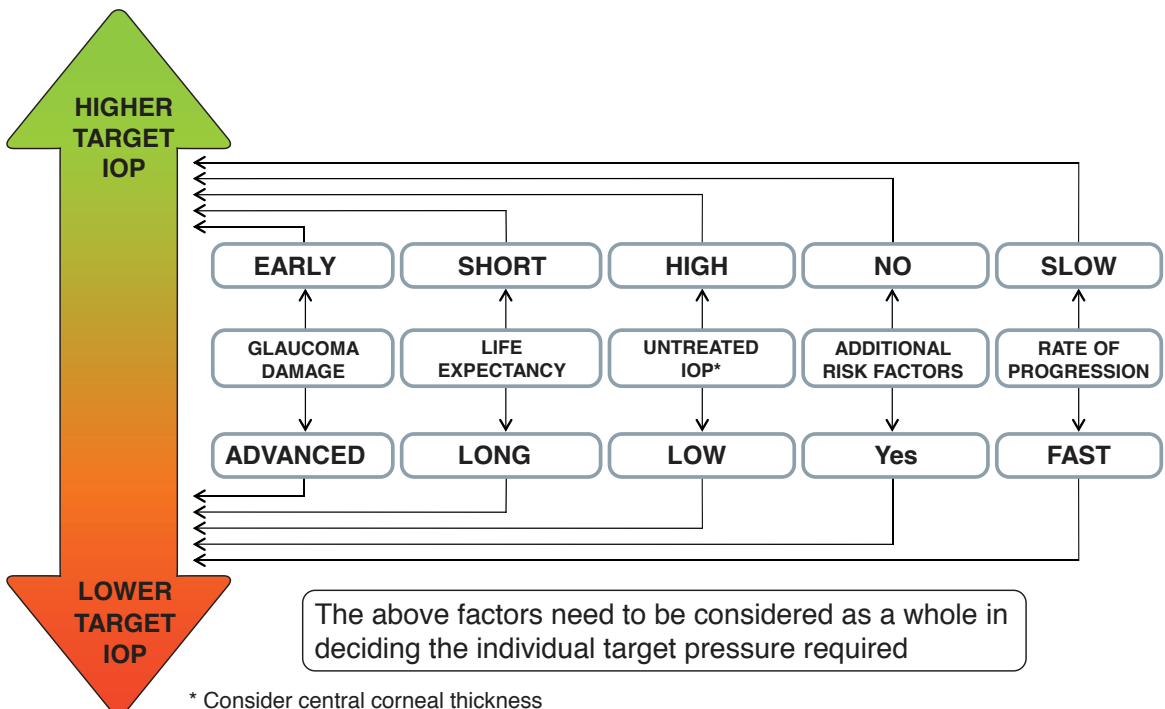
In a newly-diagnosed patient, the rate of progression is unknown and Target IOP is based on risk factors for progression (See Ch. 2.2.2.1). After sufficient follow-up and with sufficient visual field tests to reliably determine the progression status, usually 2-3 years, the importance of the risk factors for decision-making decreases and importance of the measured rate of progression increases; the rate of progression should be used to adjust the Target IOP, taking into account IOP levels over the observation period, life expectancy, and current levels of visual function damage (See FC X)²².

3.2.1.1 Setting the Target IOP

There is little evidence base to support any particular algorithm to set the Target IOP, but data from clinical trials may be used as a guide. As clinical trials have shown that progression occurs in eyes that have an IOP within the statistically normal range (<21 mmHg), older recommendations that treated IOP should be simply within the statistically normal range are no longer regarded as sufficiently ambitious.

In newly diagnosed patients, the Target IOP is initially determined according to stage of disease and the starting IOP, with the treatment goal being a specific IOP level or a percentage reduction, whichever is the lower⁵⁰ [II,D]. For instance, in early glaucoma, an IOP of <21 mmHg with a reduction of at least 20% may be sufficient. In moderate glaucoma, an IOP <18 mmHg with a reduction of at least 30% may be required [II,D]. Lower Target pressures may be needed in more advanced disease [I,D]. The Target IOP based on stage of disease and IOP then needs to be refined according to the presence of other risk factors, expected longevity of the patient, the burden of therapy and the patient preferences (See FC X)⁴⁶ [II,D].

FC X - Setting the Target IOP

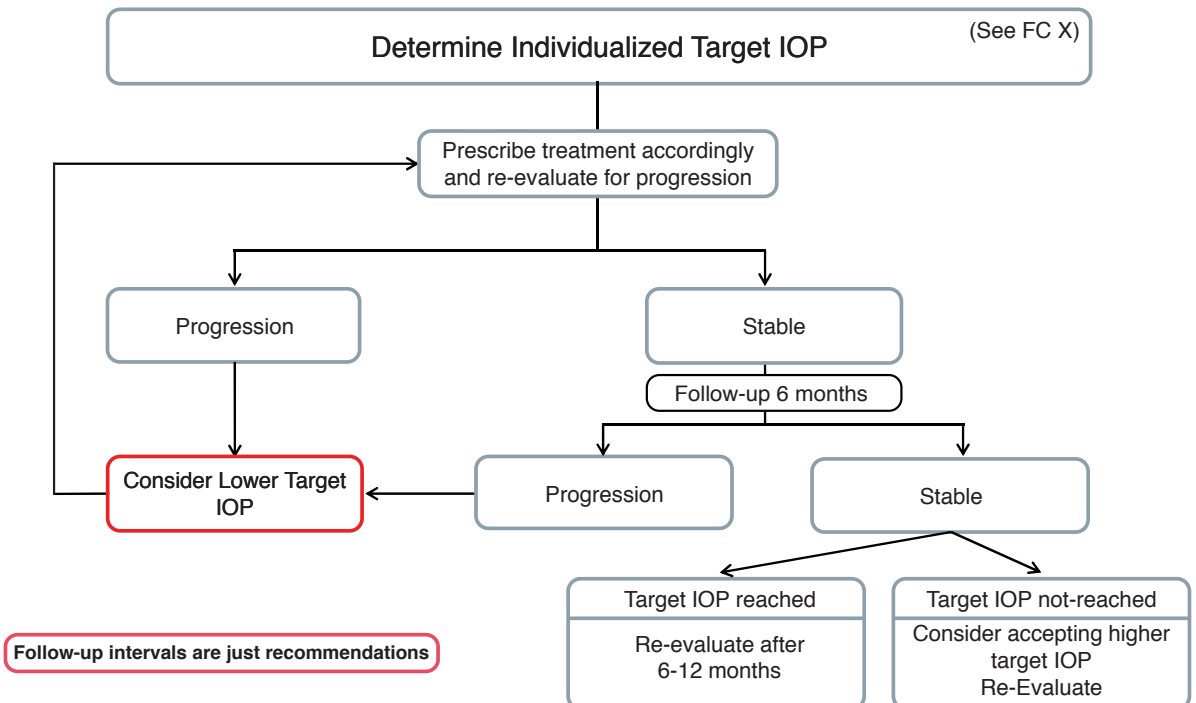


* Consider central corneal thickness

3.2.1.2 Achieving the Target IOP

Initial therapy may be with topical medication or laser trabeculoplasty [I,A]. The principles of adjusting therapy to achieve treatment targets are shown in Flow Charts IX - X - XI. To minimize side effects, the least amount of medication required to achieve the desired therapeutic response should be given. If a patient fails to attain the Target IOP during follow-up, and additional therapy is being considered, then the Target IOP should be reaffirmed to ensure that it is still appropriate [II,D].

FC XI - Adjustment of Target IOP



3.2.1.3 Re-evaluating Target IOP

If the visual field is worsening at a rate that may threaten Quality of Life during the patient's expected lifetime, then the Target IOP, if previously met, should be lowered; a further 20% reduction has been shown to be effective⁵¹. If the Target IOP had not previously been met, then additional therapy should be considered, in consultation with the patient, weighing the risks and benefits of the additional intervention (See FC XI) [I,D].

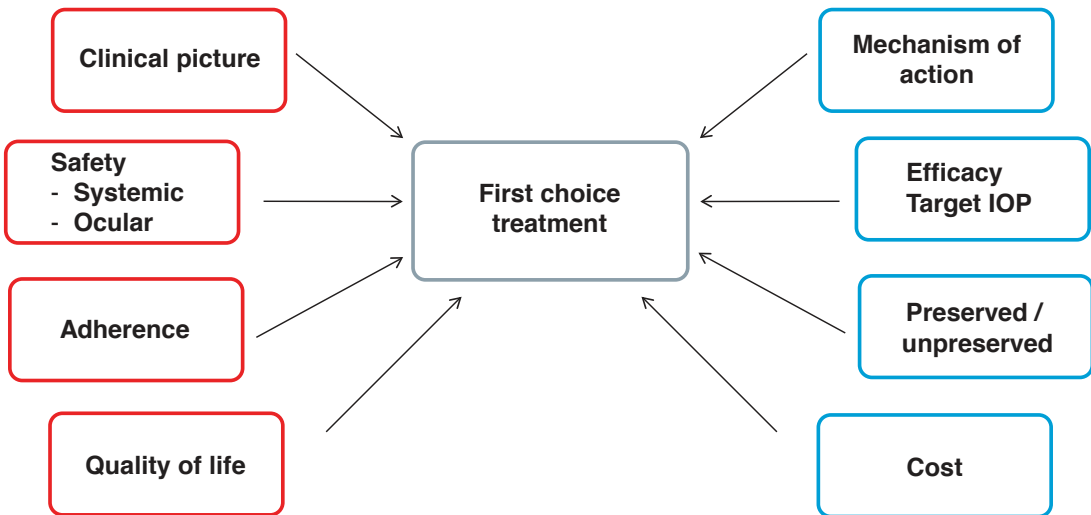
If there are sufficient visual fields to judge the rate of progression, and this rate is sufficiently slow not to impact on the patient's quality of life, then the Target IOP may be revised upward if the Target IOP has not been met or if the patient is on excessive therapy or is experiencing side effects [II,D].

If there are insufficient visual fields to judge the rate of progression and the Target IOP has not been met, then additional therapy should be considered, as above [II,D].

FC XII - Considerations on First Choice Treatment

PATIENT CHARACTERISTICS

DRUG PROPERTIES



A first choice treatment is considered a drug that the treating physician prefers to use as initial IOP lowering therapy as opposed to the first line treatment, which is one that has been approved by an official controlling body, like EMEA, FDA or National Agencies.

3.3 - ANTI GLAUCOMA DRUGS

Several prospective randomized multi-centre controlled clinical studies have clearly established the benefits of IOP reduction in managing POAG at various stages of the disease whether of the ‘high pressure’ or ‘normal pressure’ variety as well as reducing the conversion of OHT to POAG^{10,18,28,52-56} [I,A].

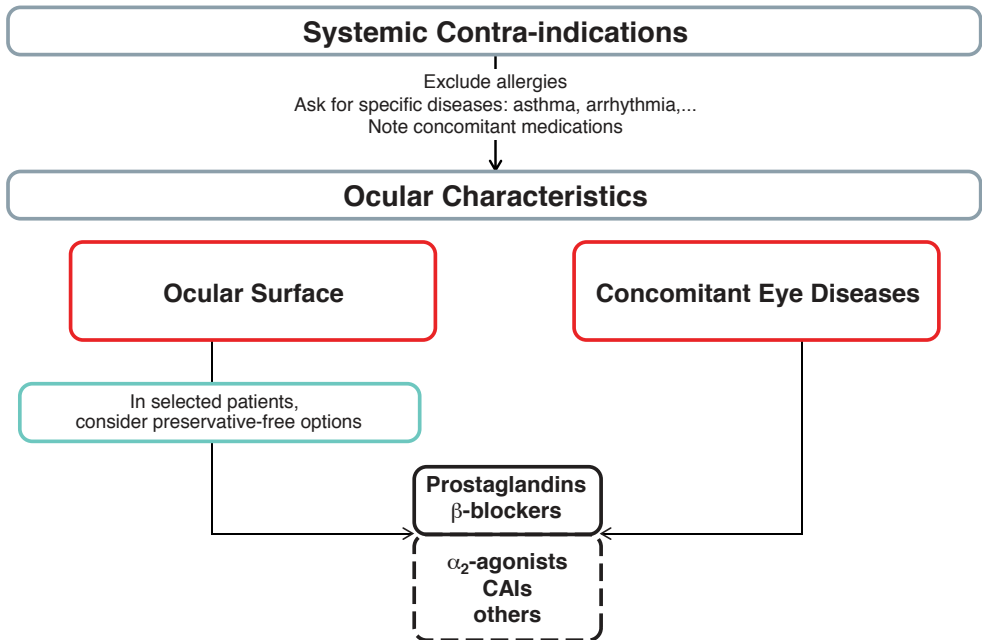
Most forms of open-angle glaucoma and many types of chronic angle-closure glaucoma are initially treated with topical and occasionally orally administered agents that act either on the reduction of aqueous humour production or enhancement of the aqueous outflow or on both. An uncommon exception to initiating treatment with medical therapy is for eyes with a very high level of IOP at presentation causing an immediate threat to sight. Additionally many forms of childhood glaucoma are managed with early surgery [I,D].

Although acute angle closure with or without glaucoma needs rapid laser or incisional surgery, medical treatment usually will be initiated as a first step in most cases.

Laser treatment may be a suitable first option for patients with known intolerance or allergy to topical agents or suspected poor compliance [I,A].

When initially selecting medical therapy it is important to consider some relevant patient’s characteristics as well as features related to the drug (See FC XII and XIII).

FC XIII - Medical Management - Choosing Therapy



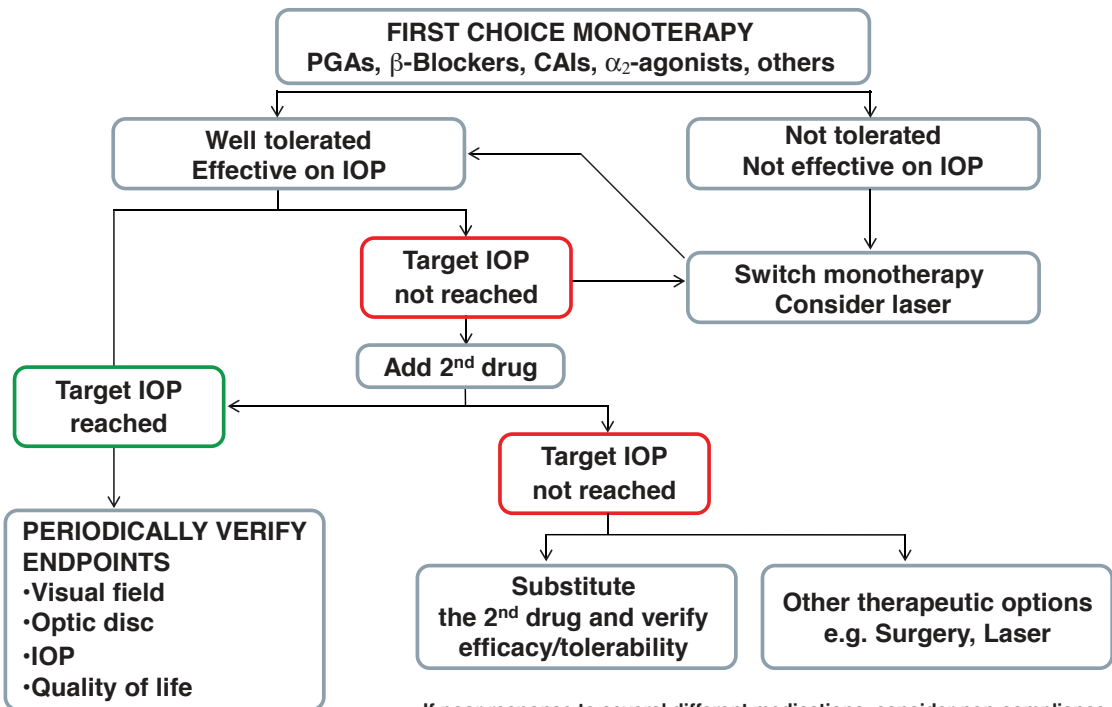
3.3.1. Start with Monotherapy

It is recommended to initiate the treatment with monotherapy (See FC XIII - XIV) [I,D]. Treatment is considered “effective” when the achieved IOP reduction on treatment is comparable to the published average range for that drug in a similar population. According to a meta-analysis of randomised controlled trials, the highest reduction of IOP is obtained with prostaglandins, followed by non-selective b-blockers, alpha-adrenergic agonists, selective b-blockers and at last topical carbonic anhydrase inhibitors⁵⁷.

It should be noted, however, that treatment effects depend on baseline IOP, with larger reductions in patients with higher pre-treatment pressure levels. At low IOP values medical and/or laser therapy have smaller effect on IOP. Therefore, when evaluating the efficacy of a therapy or a drug it is important to consider the pre-treatment baseline IOP⁵⁸.

If this initial therapy reduces IOP to the target and is well tolerated, therapy can be left unchanged, but the patient needs to be monitored with regular checking of endpoints [I,D].

FC XIV - Therapeutical Algorithm in Glaucoma Topical Therapy



If poor response to several different medications, consider non-compliance

3.3.1.1 Switch to Another Monotherapy

If the initial therapy does not seem effective, with the target pressure not being reached, or the drug is not tolerated, one should switch to another monotherapy rather than adding a second drug [II,D]. This applies also to prostaglandin analogues, (PGA) when used as first choice. As there are non-responders to certain PG analogues the switch to another PGA or another class of monotherapy might be of benefit [II,D]. Laser therapy may also be a therapeutical option (See FC XIII) [I,A].

3.3.1.2 Add Second Drug / Combination Therapy

If the first choice monotherapy is well tolerated and has effective IOP lowering but has not succeeded in reaching the target pressure, the addition of a second drug should be considered [II,D]. While individualizing adjunctive therapy, issues to consider in selecting an adjunctive agent include additive efficacy, safety, frequency of dosing and cost. It is recommended to combine agents with different modes of action, one that affects production of aqueous humour and another that influences outflow [II,D]. In general, treatment with a combination of agents of different classes is associated with superior IOP lowering efficacy compared to each of the components used alone [I,A] (see Tables 3.1-3.2). However poly-drug regimens for glaucoma pose several important clinical challenges: multiple topical treatments may jeopardize adherence^{59,60}, result in reduced efficacy through wash-out of earlier medications with later medications^{61,62} and increase exposure to preservatives^{63, 64}.

Therefore, fixed combination therapy, when available, should be preferable to two separate instillations of agents [I, B].

Currently, all fixed combinations available in Europe contain a beta-blocker. However, beta-blocking agents can be associated with systemic side effects and need to be used cautiously in patients with serious concomitant cardiopulmonary diseases. It is therefore mandatory to exclude patients with these contra-indications before prescribing fixed combinations [I,D]. It is not recommended to combine two bottles of fixed combinations as both will contain a β -blocker and double the amount of this active drug with the risk of more systemic side effects [I,D]. On the other hand, fixed combinations containing timolol may be associated with a better local tolerability in some patients, though data are limited⁶⁵.

Fixed combinations usually have clinical equivalence to unfixed combinations; slight differences in IOP-lowering efficacy may be seen in some cases^{66,67}.

Occasionally IOP-lowering agents are available as fixed combinations in some countries and are in development in others. A new fixed combination without a β -blocker, containing a carbonic anhydrase inhibitor (brinzolamide 1.0%) and an alpha 2 adrenergic receptor agonist (brimonidine tartrate 0.2%) has been recently approved by the FDA and submitted to EMEA but is not yet widely available. Also, a new fixed combination of tafluprost 0.0015% and timolol 0.5% has been submitted to EMEA.

Combination therapy, either as poly-drug regime or as fixed combination, is not recommended as first-line treatment [II,D]. However, in selected cases, such as advanced glaucoma and/or very high levels of IOP, the requested IOP reduction

may exceed the efficacy range that can be expected by a single agent. Therefore, although the standard treatment algorithm remains unchanged, the time interval between incremental therapeutic steps may be decreased, combination therapy, fixed or unfixed, can be adopted more quickly than usual or even immediately [II,D]. If combination therapy fails to lower IOP sufficiently, one can either substitute the second drug or add a third medication to the fixed combination. At this stage however laser or incisional surgery, if possible, should be considered [II,D].

Table 3.1

Combined IOP-lowering topical medications	
Bimatoprost 0.03%	Timolol 0.5%
Latanoprost 0.005%	Timolol 0.5%
Travoprost 0.0004%	Timolol 0.5%
Brimonidine 0.2%	Timolol 0.5%
Dorzolamide 2%	Timolol 0.5%
Pilocarpine 2%	Timolol 0.5%
Pilocarpine 4%	Timolol 0.5%
Pilocarpine 2%	Metipranolol 0.1%
Pilocarpine 2%	Carteolol 2%
Brinzolamide 1%	Brimonidine 0.2%
Tafluprost 0.0015%	Timolol 0.5%

Table 3.2

DRUG COMBINATIONS - ADDITIVE EFFECT					
CURRENT DRUG	ADDITIONAL DRUG				
	Alpha2-agonists	Beta-Blockers	Topical CAIs	Cholinergic	Prostaglandin/ Prostaglandins
Alpha2-agonists		+	+	+	+
Beta-Blockers	+		+	+	+
Topical CAIs	+	+		+	+
Cholinergic	+	+	+		+/-
Prostaglandin/ Prostaglandins	+	+	+	+/-	

3.3.2 The Effect on IOP

The pre-post IOP graph shown below is a useful tool to show the IOP changes induced by treatment and its use should be encouraged in publications.

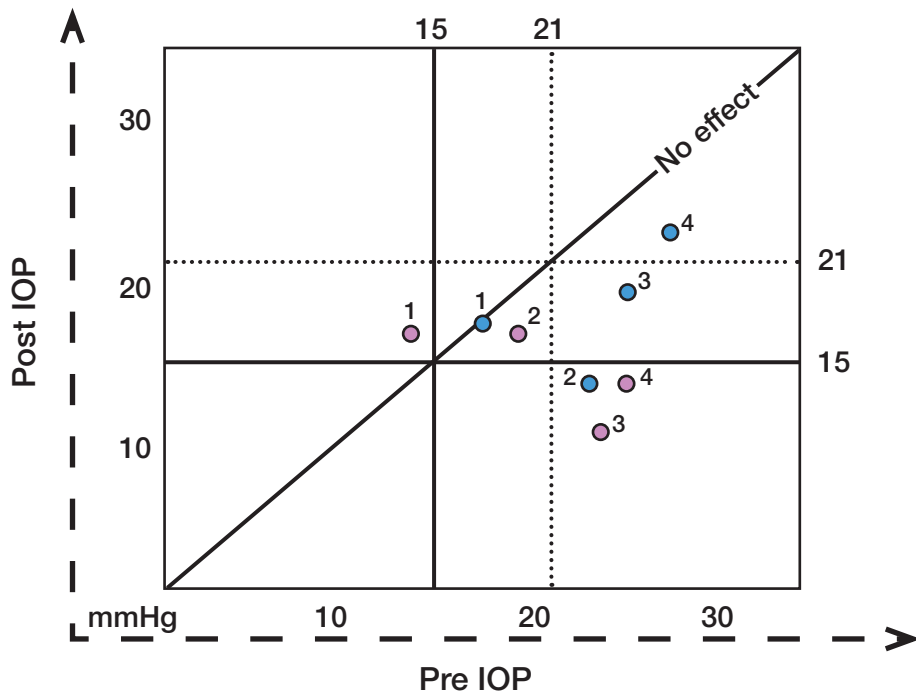


Figure 3.2. The Pre - Post IOP Graph.

A simple graph can be used to show the IOP lowering effect. Different shapes/colours can be used to show different patient series or different observation times. Vertical and horizontal lines show respectively Pre and Post Treatment IOP levels of interest, here placed as examples at 15 and 21 mmHg. Areas of desired effect under the oblique “no effect” line can thus be defined.

Treatment “A” blue dots: eye n 1 lies on the “no effect” line. Eyes n 2 and n 3 both show a large effect, with only the former below the 15 mmHg line. Eye n 4 shows a sizeable decrease of IOP but the absolute level is still >21 mmHg.

Treatment “B” red dots. Eyes n 1 and n 2 show a slight increase and a slight decrease of IOP, respectively; eye n 3 shows a very large effect, as well as eye n 4, both remaining below the 15 mmHg line.

REMEMBER: [I,D]

- * Assess each eye individually when deciding the most appropriate therapy.
- * It is essential to involve patients as informed partners in decisions regarding the management of their condition.
- * The least amount of medication (and consequent inconvenience, costs and side effects) to achieve the therapeutic response should be a consistent goal.
- * A therapeutic medical trial on one eye first can be useful to determine the IOP lowering efficacy, although not always logistically feasible or advisable (e.g., very high IOP or advanced disease).
- * Usually there is no need to start treatment until all baseline diagnostic data are collected, unless the IOP is very high and there is severe damage.
- * After diagnosis it is advisable to measure untreated IOP more than once before initiating IOP-lowering treatment

The following pages outline the most frequently used anti-glaucoma medications, and emphasize their mode of action, dosage and side effects. A complete list of all possible medications is beyond the scope of the Guidelines.

Antiglaucoma drugs have been available since 1875. The following diagram shows the chronology of the introduction of topical intraocular pressure-lowering medications (Fig. 3.3).

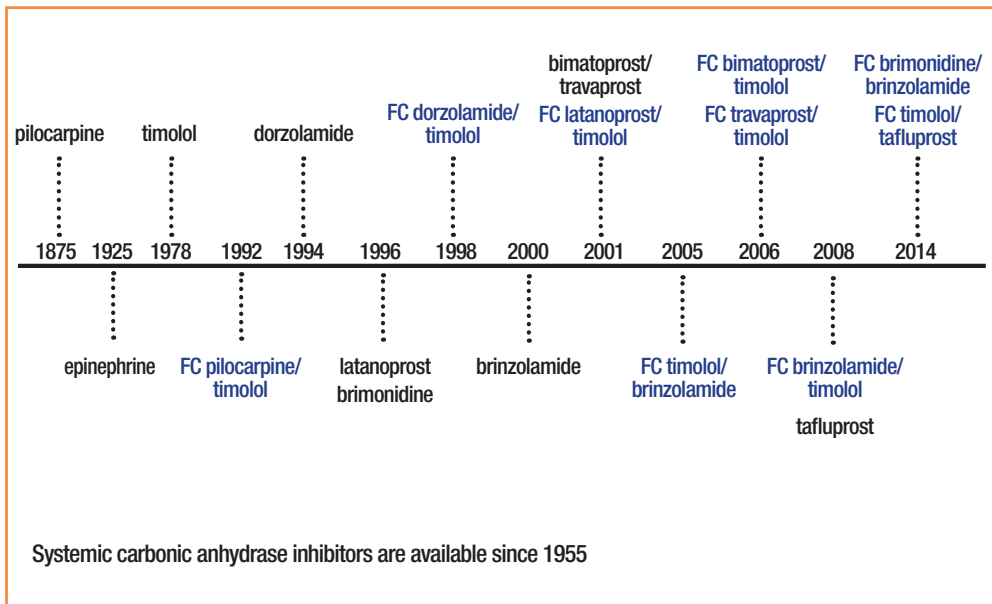


Figure 3.3. IOP lowering molecules and year of first clinical use. FC: fixed combination. In black: monotherapy.

There are six classes of topical antiglaucoma drugs. The following tables contain only the most common classes and compounds, their most common side effects and contraindications. They are listed in order of first and second line drugs.

The seventh category is systemically administered osmotics.

The use of some compounds like epinephrine and dipivefrin has decreased significantly since drugs with better efficacy and fewer side effects became available.

The text should be considered as a general guide, and cannot be all-inclusive.

3.3.3 First Line Drugs

Table 3.3 Class: PROSTAGLANDIN ANALOGUES

	Compound	Mode of action	IOP reduction	Contra-indications	Side effects
Prostaglandin analogues	Latanoprost 0.005% Tafluprost 0.0015% Travoprost 0.003% - 0.004%	Increase in uveo-scleral outflow	25-35%	Contact lenses (unless reinserted 15 minutes following administration of the drugs)	<p>Local: Conjunctival hyperaemia, burning stinging, foreign body sensation, itching, increased pigmentation of periocular skin, periorbital fat atrophy, eyelash changes. Increased iris pigmentation, (in green-brown, blue/ grey-brown or yellow-brown irides). Cystoid macular oedema (aphakic/ pseudophakic patients) with posterior lens capsule rupture or in eyes with known risk factors for macular oedema, reactivation of herpes keratitis, uveitis</p> <p>Systemic: Dyspnea, chest pain/angina, muscle-back pain, exacerbation of asthma.</p>
Prostamide	Bimatoprost 0.03% Bimatoprost 0.01%	Increase in uveo-scleral outflow	25-35%		

Table 3.4 Class: Beta-RECEPTOR ANTAGONISTS

	Compound	Mode of action	IOP reduction	Contra-indications	Side effects
Nonselective	Timolol 0.1-0.25-0.5% Levobunolol 0.25% Metipranolol 0.1-0.3% Carteolol 0.5-2.0% Befunolol 0.5%	Decreases aqueous humour production	20-25%	Asthma, history of COPD, sinus bradycardia (< 60 beats/min), heart block, or cardiac failure	Local: Conjunctiva hyperaemia, SPK, dry eye, corneal anesthesia, allergic blepharoconjunctivitis Systemic: Bradycardia, arrhythmia, heart failure, syncope, bronchospasm, airways obstruction, distal oedema, hypotension, Hypoglycemia may be masked in Insulin dependent Diabetes Mellitus (IDDM), nocturnal systemic hypotension, depression, sexual dysfunction
Beta-1-selective	Betaxolol 0.5%	Decreases aqueous humour production	±20%	Asthma, history of COPD, sinus bradycardia (< 60 beats/min), heart block, or cardiac-coronary failure	Local: Burning, stinging more pronounced than with non-selective compounds Systemic: Respiratory and cardiac side effects less pronounced than with non-selective compounds, depression, erectile dysfunction

Table 3.5 Class: CARBONIC ANHYDRASE INHIBITORS

	Compound	Mode of action	IOP reduction	Contra-indications	Side effects
Topical	Brinzolamide 1% Dorzolamide 2%	Decreases aqueous humour production	20%	Patients with low corneal endothelial cell count, due to increased risk of corneal oedema	Local: Burning, stinging, bitter taste, superficial punctate keratitis, blurred vision, tearing Systemic: Headache, urticaria, angioedema, pruritus, asthenia, dizziness, paresthesia and transient myopia.
Systemic	Acetazolamide Methazolamide Dichlorphenamide	Decreases aqueous humour production	30-40%	Depressed sodium and/or potassium blood levels, cases of kidney and liver disease or dysfunction, suprarenal gland failure, hyperchloremic acidosis.	Systemic: Paresthesias, hearing dysfunction, tinnitus, loss of appetite, taste alteration nausea, vomiting, diarrhoea, depression, decreased libido, kidney stones, blood dyscrasias, metabolic acidosis, electrolyte imbalance

Table 3.6 Class: Alpha-2 SELECTIVE ADRENERGIC AGONISTS

	Compound	Mode of action	IOP reduction	Contra-indications	Side effects
Alpha-2-selective	Apraclonidine 0.5-1.0%	Decreases aqueous humour production	25-35%	Oral monoamine oxidase (MAO) inhibitor users Pediatric age Very low body weight in adults	Local: Lid retraction, conjunctival blanching, limited mydriasis (apraclonidine), allergic blepharoconjunctivitis, periocular contact dermatitis, allergy or delayed hypersensitivity (apraclonidine and clonidine >brimonidine) Systemic: Dry mouth and nose (apraclonidine). Systemic hypotension, bradycardia (clonidine), fatigue, sleepiness (brimonidine)
	Brimonidine 0.2%	Decreases aqueous humour production and increases uveo-scleral outflow			
	Clonidine 0.125-0.5%	Decreases aqueous humour production	18-25%		

3.3.4 Second Line Drugs

Table 3.7 Class: NON SELECTIVE ADRENERGIC AGONISTS

	Compound	Mode of action	IOP reduction	Contra-indications	Side effects
Non-selective	Epinephrine 0.25-2.0% Dipivefrin 0.1%	Decreases aqueous humour production and may increase uveo-scleral outflow	15-20%	Occludable angles (iridotomy needed) Aphakic patients (macular oedema)	Local: Conjunctival hyperemia, conjunctival pigmentation. Burning, stinging, ocular pain, blurred vision, macular oedema Systemic: systemic hypertension, headache, anxiety, confusion, chest pain, shortness of breath, tachycardia, sweating

Table 3.8 Class: PARASYMPATHOMIMETICS (CHOLINERGIC DRUGS)

	Compound	Mode of action	IOP reduction	Contra-indications	Side effects
Direct-acting	Pilocarpine 0.5-4% Carbachol 0.75-3%	Facilitates aqueous outflow by contraction of the ciliary muscle, tension on the scleral spur and traction on the trabecular meshwork	20-25%	Post-operative inflammation, uveitis neovascular glaucoma. Patient at risk for retinal detachment, spastic gastrointestinal disturbances, peptic ulcer, pronounced bradycardia, hypotension, recent myocardial infarction, epilepsy, Parkinsonism	Local: Reduced vision due to miosis and accommodative myopia, conjunctival, hyperaemia, retinal detachment, lens opacities, precipitation of angle closure, iris cysts Systemic: Intestinal cramps, bronchospasm, headache
Indirect-acting	Demecarium bromide 0.125-0.25% Ecothiophate iodide 0.03% Diisopropyl fluorophosphates 0.025-0.1%		15-25%	Same as direct acting drugs	Local and systemic: Side effects are similar but more pronounced than with direct acting compounds

Table 3.9 OSMOTICS

	Compound	Mode of action	IOP reduction	Contra-indications	Side effects
Oral	Glycerol	Dehydration and reduction in vitreous volume Posterior movement of the iris-lens plane with deepening of the AC	15-20%	Cardiac or renal failure	Nausea, Vomiting, dehydration (special caution in diabetic patients). Increased diuresis, hyponatremia when severe may lead to lethargy, obtundation, seizure, coma. Possible increase of blood glucose. Acute oliguric renal failure. Hypersensitivity reaction
	Isosorbide				
	Alcohol				
Intravenous	Mannitol	15-30%			
	Urea				

3.3.4.1 Prostaglandin Analogues

Since their development in the 1990s, prostaglandin derivatives (latanoprost, travoprost, bimatoprost and tafluprost) (Table 3.3) have progressively replaced beta-blockers as first-choice/first line therapy. This is mainly because they are the most effective IOP-lowering agents⁵⁴, lack relevant systemic side effects and require just once-daily administration. Recently, a number of latanoprost generics as well as preservative-free and BAC-free prostaglandin formulations have entered the glaucoma market.

The primary mechanism of action of prostaglandins is to increase uveoscleral outflow, reducing IOP by 25%-35%. Reduction of IOP starts approximately 2-4 h after the first administration, with the peak effect within approximately 8-12 h. Thus, IOP measurements taken in the morning represent the peak effect of the prostaglandin analogues for patients administering the drug in the evening. Clinical trials that measured 24-hour IOP suggested that evening administration is generally preferable because it gave a better circadian IOP profile⁶⁸⁻⁷⁰ [II, B]. These studies also reported that eyes treated with PG derivatives have reduced short-term IOP variability as compared to eyes treated with other classes of drugs⁷¹.

Maximum IOP lowering is often achieved 3-5 weeks from commencement of treatment. Differences among drugs within this class in the capability of reducing IOP did not exceed 1 mmHg⁷². When combined with most of the other antiglaucoma drug classes, prostaglandin agents provide additive IOP lowering.

Non-responders to prostaglandin analogues (e.g. eyes with IOP reductions of less than 10% or 15% from baseline) are fewer than 10%^{73,74}. Some reports indicate that poor responders to one prostaglandin agent might respond to another agent within the same class^{75,76}. Conjunctival hyperemia, generally mild, is a common finding with slight difference in frequency and level among agents within this drug class. It usually decreases over time. Other PG side effects are reported in Table 3.3.

Details on the mode of action, IOP lowering effect, contraindications and side effects of other first line drugs (β -blockers, carbonic anhydrase inhibitors, alpha-2 selective adrenergic agonists) and second line drugs are listed in Tables 3.5-3.10.

3.3.5 Local Toxicity of Topical IOP - Lowering Treatment. The Role of Preservatives

Long-term topical glaucoma medications may cause and/or exacerbate pre-existing ocular surface disease (OSD), such as dry eye, meibomian gland dysfunction and chronic allergy⁷⁷, which, in glaucoma patients, has a much higher prevalence than in the general population^{63,64,78}. OSD may follow chronic use of antiglaucoma medication and/or the preservative benzalkonium chloride (BAC). BAC, a quaternary ammonium compound is the most frequently used preservative agent in eye drops and its usage correlates well with the signs and symptoms of OSD^{63, 64,79-82}. Such signs and symptoms can diminish if BAC-preserved drops are substituted with non-preserved drops⁶³. An unwanted effect of BAC is a reduction in the success rate of filtering surgery⁸³⁻⁸⁵. In vitro studies suggest that alternative preservatives are significantly less toxic than BAC⁸⁶⁻⁹¹.

Other therapeutic possibilities are the use of preservative-free or BAC-free medication, decreasing the number of preserved eyedrops i.e. by using fixed combinations; treating the ocular surface with unpreserved tear substitutes and performing earlier laser or surgery. When considering OSD four factors have to be considered: the active compound, the specific preservative, the ability of the patient to use single-dose preparations and the patient's ocular surface.

The European Medicines Agency (EMA) has suggested that the use of preservatives should be avoided in "patients who do not tolerate eye drops with preservatives" and in those on long-term treatment, or to use "concentration at the minimum level consistent with satisfactory antimicrobial function in each individual preparation", with a specific indication to avoid mercury containing preparations⁹².

Not all patients are sensitive to preservatives and not all the local side effects observed with topical antiglaucoma medications are induced by preservatives.

Particular attention should be paid to glaucoma patients with pre-existing OSD or to those developing dry eye or ocular irritation over time. This can be done by careful assessment of redness of the eyelid margin, positive corneal and conjunctival fluorescein staining or reduced tear break-up time [I,D].

3.3.6 Generic IOP - Lowering Topical Medications

By definition a generic drug is identical to a brand name drug in dosage, strength, route of administration, performance characteristics and intended use. For the purposes of drug approval, the interchangeability of a generic drug and the corresponding brand-name drug is based on the criterion of "essential similarity". In ophthalmology this concept is problematic, because it is difficult to prove "essential similarity" in clinical studies. With systemic drugs bioequivalence studies are performed using blood samples to determine whether the plasma concentration within certain limits equals the branded drug. With topical eye drops such studies obviously cannot be performed.

No clinical studies are usually required for generic approval in ophthalmology, and a 10% difference between the concentration of the active principle between the generic and the branded products is considered acceptable. Whereas the active principle is assumed to be equal, the adjuvants can vary considerably. This is a critical issue

because different adjuvants may alter the viscosity, osmolarity and pH of the eye drops and therefore have an impact on both tolerability and corneal penetration. Nevertheless anti-glaucoma generics drugs are currently prescribed at a large scale, as many drugs are becoming off patent. For latanoprost, the generic share is more than 65% in most European countries. To which degree these generics are similar in efficacy and tolerability is not well studied. Only few clinical studies have compared the effect of generic and brand IOP lowering medications in glaucoma, with variable results depending on the type of generic drug^{93,94}. Other studies have shown a difference between the branded and the generic preparations concerning the size and amount of drops in the bottle, the structure of the bottle and the bottle tips⁹⁵⁻⁹⁸. Safety issues with corneal epithelial disorders have also been described with generics, due to an additional stabiliser compound⁹⁹. When switching patients from branded to generic drugs, the IOP should be closely monitored [I,D].

3.3.7 Dietary Supplementation and Glaucoma

Although there is no clinical evidence for clinical benefits arising from the use of dietary supplements in glaucoma, a recent survey has found that 1 in 9 glaucoma patients were using complementary and alternative medicine (CAM). Most were using herbal medicines (34.5%), dietary modifications (22.7%) or dietary supplements (18.8%)¹⁰⁰. Based on the fact that some glaucoma patients continue to progress at low IOPs, there is much room for hypotheses, preclinical experiments, clinical trials and speculation. Some data from experimental studies suggest that dietary supplementation may reduce oxidative stress¹⁰¹, or that the omega 3 polyunsaturated fatty acids (PUFAs) decrease IOP in rats¹⁰². At the present time there is no robust interventional dietary supplementation study demonstrating the positive effect of such a treatment in glaucoma patients. Observational studies have suggested a reduced risk for glaucoma with higher fruit and vegetable intake¹⁰³ or higher omega 3 PUFAs consumption in selected populations¹⁰⁴. Conversely there is evidence that some of these compounds may cause harm, such as an increased intake of magnesium associated with a higher incidence of glaucoma¹⁰⁵.

DIETARY SUPPLEMENTATION

At the present time there is no robust interventional dietary supplementation study demonstrating the positive effect of such a treatment in glaucoma patients

3.3.8 Management of Glaucoma During Pregnancy and Breast-feeding

Pregnancy-related changes in ocular physiology can influence IOP as well as the reliability of its measurements. Changes in hormonal levels, are thought to induce an IOP-lowering effect that increases throughout pregnancy (but particularly during the 24th-30th week) and can last for months after delivery¹⁰⁶⁻¹⁰⁸.

The most sensitive period is the first trimester due to concerns relating teratogenicity,

as the majority of IOP-lowering medications are within class C (See Table 3.10) meaning that adverse effects have been seen in animals or that there are no human or animal data (See Table 3.11). Therefore, for a woman with glaucoma who is of child bearing age, who might wish to conceive, the treatment strategy during pregnancy should be discussed [I,D]. The patient should be instructed to inform the ophthalmologist when pregnancy occurs. The potential risks to the fetus (and neonate) of continuing anti-glaucoma medications must be balanced against the risk of vision loss in the mother [I,D]. As IOP levels generally decrease during pregnancy, temporary treatment discontinuation can be considered under strict follow-up in some patients. However, if continuation of treatment is mandated, the lowest effective dosage of medication should be used. Moreover, systemic absorption should be reduced by punctal occlusion, eyelid closure, and blotting excess drops away during administration¹⁰⁹ [I,D].

Drugs are classified in Classes A to X for use during pregnancy based on a hierarchy of estimated fetal risk (See Tables 3.10-3.11)¹¹⁰. Although very similar, some countries (e.g., Sweden, Australia, the Netherlands, Switzerland, and Denmark) have their own classification systems.

Table 3.10 Drug classification for use of drugs during pregnancy

Class A	Controlled studies show no risk. Adequate well-controlled studies in pregnant women have failed to demonstrate risk to the foetus
Class B	No evidence of risk in humans. Either animal findings show risk, but human findings do not or, if no adequate human studies have been done, animal findings are negative
Class C	Risk cannot be ruled out. Human studies are lacking, and animal studies are either positive for foetal risk or lacking as well. However, potential benefits may justify the potential risk
Class D	Positive evidence of risk. Investigational or post-marketing data show risk to the foetus. Nevertheless, potential benefits may outweigh the potential risk
Class X	Contraindicated in pregnancy. Studies in animals or human, or investigational or post-marketing reports, have shown foetal risk which clearly outweighs any possible benefit to the patient

(FDA Classification of Drugs for Teratogenic Risk. Teratology society public affairs committee. Teratology 1994: 49:446-447).

Brimonidine is a Class B medication: however, there are reports of central nervous system side effects in young children¹¹. The ability of this drug to cross the placenta and the lack of well controlled human studies during pregnancy do not allow ruling out possible adverse effects on the fetus. Betaxolol is also in class B and is characterized by a larger volume of distribution in the fetal circulation, high binding to proteins and therefore fewer central nervous systemic effects on the fetus. Timolol although class C, is available in low dosage (0.1%), in slow-release preparations which can be used once daily. Although these formulations are thought to reduce systemic absorption, strong evidence to support this is still lacking. Once-a-day timolol 0.1% gel may be a valid option if a beta-blocker is considered [I,D]. Prostaglandin-analogues should be considered with caution because of the theoretical risk of increased uterine contractility in pregnancy. If premature contractions appear PG should be discontinued immediately [I,D].

There have been no reports on any fetal complications related to the use of topical carbonic anhydrase inhibitors in humans, but animal studies have shown that high systemic doses, are associated with low weight offspring (*Manufacturer's Information: Azopt product monograph. Fort Worth, Texas, Alcon Ophthalmics, 1998 Manufacturer's Information: Trusopt product monograph. West Point, Pennsylvania, Merck Inc., 1999*). At clinically used concentrations, BAC has no known impact on the fetus¹².

Table 3.11 summarizes known adverse effects of anti-glaucoma drugs during pregnancy and breast-feeding.

Although results from animal studies are worrisome, the overall level of evidence for the risk of giving anti-glaucoma drugs to pregnant women is low.

Laser trabeculoplasty is considered to be a safe alternative¹³ except in patients with angle dysgenesis. However, IOP lowering success is lower in younger patients, such as in women of childbearing age¹⁴.

Laser cyclodestruction, in spite of having been suggested as a valid option should be considered with caution because of risk of sight-threatening complications¹⁵.

If surgery is planned, there are a number of considerations to be made. A supine position should be avoided¹⁶. For intervention under local anesthesia, topical, subconjunctival or retrobulbar, lidocaine is considered to be a safe option¹⁷. The use of anti-metabolites is strictly contraindicated, due to the mutagenic related risk. Depending on previous ocular surgeries and the age of patient, filtering surgery, including tube shunt implantation, can be considered¹² [II,D].

Topical prednisolone and erythromycin have been shown to cross the placenta to a lesser extent than other medications of their classes, and can therefore be chosen as postoperative medication^{17,118} [II,D].

Special attention should be paid also during breast-feeding. Carbonic anhydrase inhibitors and beta-blockers may be used in nursing mothers as suggested by the American Academy of Pediatricians¹⁹. These are also the first line choices in infants with congenital glaucoma when medical therapy is being considered.

Fixed combinations are all class C. Prescribing physicians should separately consider each of the drugs involved [I,D].

Table 3.11 Adverse effects of IOP-lowering medications during pregnancy/breast-feeding

	Class	Pregnancy			Breast-feeding
		Animal Studies	Human		
			Theoretical risk	Reported cases	
Parasympathetic agents	C	Teratogenic	Teratogenicity Dysregulation of placental perfusion	Meningism in newborn	Seizures, fever, diaphoresis
Sympathetic agents • brimonidine	B	No significant effect	Delay in labor/ uterine hypotony	No reported side-effects	CNS depression, hypotension and apnea
Prostaglandin analogs	C	High incidence of miscarriage	Uterine contractions	One case of miscarriage	No reported side-effects
Beta-blockers	C	Delayed fetal ossification, fetal resorption	Teratogenicity (1st trimester) Cardiac rhythm changes Respiratory	Arrhythmia and bradycardia Impaired respiratory control in newborns	Controversy over concentrations in breast milk. Apnea and bradycardia
Carbonic anhydrase inhibitors					
• Topical	C	Decreased weight gain Vertebral body malformation	Lower fetal weight	No reported side-effects	No reported side-effects
• Oral	C	Forelimb anomalies	Limb malformations	One case of teratoma	No reported side-effects

NOTE: there is a lack of well-controlled human studies during pregnancy. Therefore it is not possible to accurately determine the real incidence of the stated adverse effects, or to exclude the existence of any additional unforeseen adverse effects on the fetus.

3.3.8 Neuroprotection and Glaucoma Treatment

Neuroprotection can be defined as a “therapeutic approach” aiming to directly prevent or significantly hinder neuronal cell damage. Since glaucoma patients can continue deteriorating in spite of an apparently well controlled IOP, the need for effective non-IOP related treatments is widely acknowledged. Several compounds have been neuroprotectant in preclinical studies¹²⁰. Only two have reached large scale clinical trials: a large long-term RCT using an NMDA antagonist, memantine, was analysed in 2008 with negative results. More recently, the results from a multi-center RCT of adults with low-pressure glaucoma (Low-pressure Glaucoma Treatment Study, LoGTS) has been claimed to show that brimonidine may have neuroprotective properties in comparison to Timolol⁴⁴. No direct comparison has been done with other substances such as PG. However, the authors of the study and a systematic literature review have (both?) suggested that more substantial evidence is needed^{121,122}.

3.3.9 Practical Considerations Related to Topical Medical Treatment

The majority of topically applied drugs, particularly if lipophilic, penetrate the eye via the cornea, in a lesser amount via the conjunctiva and thereafter the sclera.

On average, the total tear film volume is around 7 μl and the rate of tear film turnover is approximately 15% ($\pm 1 \mu\text{l}$) per minute but can double (washout effect) after the application of a topical drop with a volume estimated at 30-50 μl ¹²³. Although the cul-de-sac and tear film compartment can expand transiently after instillation of a drop it still cannot accommodate this whole volume and less than 5% manages to enter the eye; the rest will run down the cheek or will be drained through the nasolacrimal duct where an individually variable systemic absorption takes place through the highly vascularised nasal mucosa¹²⁴.

Once the medication is instilled into the conjunctival sac, the spontaneous tear flow will cause complete washout within 5 minutes.

The washout effect depends not only on the increased tear fluid turnover, but also on the addition of a second drop within a short period. Therefore when poly-drug regimen is used, a minimum time span between different drops should be respected. When two drugs are instilled only 30 seconds apart, almost 50% of the first drug will be washed out. The recommended delay between drops is 5 minutes with a washout effect of less than 15%^{61,62} [I,B].

Blinking also may influence washout and allow only 15% of a topically applied drug to remain in the eye approximately five minutes after instillation.

As drugs absorbed through the highly vascularised nasal mucosa avoid hepatic first-pass metabolism this might lead to systemic side effects. The instillation of one drop of timolol 0.5% for example may lead to a serum concentration of timolol that equals the intake of an oral 10 mg non-selective beta-blocker¹²⁵.

There is no evidence that nasolacrimal duct obstruction may increase the efficacy of a topical drug¹²⁶ however it may reduce systemic side effects particularly from beta-blockers by minimizing the drainage into the highly vascularised nasopharyngeal mucosa^{109,127,128} [I,D].

Patients should be advised to shake the bottle before use as micro-suspensions tend to settle to the bottom of the bottle leaving the vehicle at the surface. Thus, patients may be simply applying mainly vehicle to the eye, rather than the active drug ingredient [I,D].

GENERAL RECOMMENDATIONS [I,D]:

- Monotherapy is the first choice when initiating therapy
- Baseline IOP should be considered when evaluating the efficacy of a therapy
- Fixed Combination therapy should be considered when patients fail to achieve their individualized intraocular pressure (IOP) targets with monotherapy
- The prescription of more than two bottles of IOP lowering eye drops for simultaneous use should be avoided as it can lead to noncompliance
- Fixed combination preparations may be preferable to the use of separate instillation of two agents
- However Fixed Combination are not first-line medications and they are only indicated in patients who need adjunctive therapy, when IOP is not sufficiently controlled by one single agent
- Ocular surface should be evaluated and considered in clinical management of glaucoma patients. In case of ocular surface disease, preservative-free formulations should be considered
- Generic drops can differ from brand drops and it may be necessary to monitor patients more closely after switching
- During pregnancy, the potential risks of continuing anti-glaucoma medications to the fetus (and neonate) must be balanced against the risk of vision loss in the mother

See FC IX to XIII

3.4 - ADHERENCE, COMPLIANCE AND PERSISTENCE IN GLAUCOMA

Glaucoma is a chronic progressive disease that requires continuous long-term cooperation of the patient with the glaucoma management proposed by the doctor.

3.4.1 Terminology

The commonly used term “**compliance**” has been increasingly replaced in recent times by the term “**adherence**”. Both are defined as the ‘cooperation of the patient with the recommendations given by the doctor’. However, the former is more passive (“I am taking the medication”), while the latter implies the active part of the patient in the process (“I am taking the medication exactly as you told me”).

“**Persistence**” is defined as the length of time during which the patient is taking the medication as prescribed¹²⁹.

Finally three terms should be mentioned:

- “White coat compliance” means that the patient’s adherence rises a week before the consultation and drops quickly afterwards¹³⁰
- “Dyscompliance” is used when physical problems of a patient, like arthritis, lead to difficulties in correctly applying a therapy
- “Alliance” is a special form of adherence meaning that the people around the patient ensure the correct application of the medication¹³¹

3.4.2 Measured Adherence

Despite easier medication schemes (for example drugs which require application once-daily) and more information for the patients about the disease, the rate of non-adherence has remained almost the same over the last 25 years; between 30%-70%.

It is important to mention that the patients themselves overestimate their adherence and persistence rate (GAPS)¹³².

3.4.3 Factors Associated with Non-Adherence

Four groups of factors encountered as common obstacles to glaucoma medication adherence have been described¹³³:

- Situational / environmental (for example a major event in the patients life, unsteady life-style with many travels)
- Medication (for example costs of the drugs, side effects, complicated dosing regimen)
- Patients (for example comorbidity, poor understanding of the disease)
- Provider (for example lacking communication with the doctor)

Other influencing factors:

- Gender (men are more likely to be non adherent)
- Stage of the disease (patients with a less advanced disease tend to be less adherent)

3.4.4 Types of Non-Adherence

Every patient is different and there are several types of non-adherence¹³⁴.

- Failure to take the medication as prescribed (including under- and overdosing, inadequate doses and wrong timing of dosages)
- Failure to use the correct medication (including the application of the wrong medication or the self administration of not prescribed drugs)
- Failure to apply the medication correctly (including incorrect self administration of the medication)
- Failure to continue applying the medication (including problems with side-effects, issue of costs and missed refills)

3.4.5 Improving Adherence

There are different ways for improving the adherence of patients. The most important measures are informing the patient about his/her disease and finding a therapeutic regimen which fits into the patient's life-style¹³⁵ [I,D].

Other factors which should improve adherence [I,D]:

- The therapy should be simple i.e. not more than two bottles and an application not more than twice a day
- The patient should be instructed how to apply the drops correctly. If necessary, hints reminders should be given like a daily routine which the patient can connect to the application of the drops. If a patient has physical problems applying the drops as arthritis of the fingers, the therapy should be adjusted accordingly or switched to laser/surgery
- The doctor should inquire at every visit if the patient has side effects of the medication and switch if necessary. A patient who complains about side effects is usually not adherent to therapy.

The patient's cooperation, described as adherence and persistence, with the prescribed glaucoma management is mandatory to obtain effective IOP lowering and to prevent glaucoma progression. No drug can work unless it is taken.

3.5 - LASER SURGERY

3.5.1 Laser Iridotomy¹³⁶⁻¹³⁹

Indications: [I,C]

Clinically relevant or suspected pupillary block.

Potential prevention of acute and chronic angle closure (See FC X and XI).

Preoperative preparation:

To reduce iris thickness and facilitate perforation instil 1 drop of Pilocarpine 2%-4% [I,D]. If the cornea is edematous, like acute angle closure, use topical glycerin 10% if available, systemic acetazolamide, intravenous mannitol or oral hyperosmotic agents (See FC XI). For prevention of IOP spikes use topical alpha 2 agonist 1 hour prior to the procedure and immediately afterwards [I,B].

Procedure:

After instillation of topical anesthetic a contact lens with contact lens fluid is placed onto the cornea. The lens keeps the eyelids open, stabilizes the eye, provides additional magnification, focuses the laser beam and acts as a heat sink.

Lenses used are: Abraham (+66 diopters), Wise (+103 diopters) or CGI©LASAG CH lens. Iridotomy site [II,D] is usually chosen in the superior quadrants of the iris well covered by the upper eyelid (to reduce visual symptoms), in a thin looking area or an iris crypt. Whole thickness perforation of the iris is assumed when pigment, mixed with aqueous, flows from the posterior into the anterior chamber. Once a full thickness hole has been made, it should be enlarged horizontally to achieve an adequate size. Iridotomy size [II,D] should be sufficient for patency inspite of iris oedema, pigment epithelial proliferation and pupil dilation. Transillumination through the iridotomy is not a reliable indicator of success [II,D].

Lasers parameters for Nd:YAG laser iridotomy

Power	1-6 mJ
Spot size	50-70 µm (constant for each laser model)
Pulses per burst	1-3
Recommendations	<p>Set defocus to zero</p> <p>Focus the beam within the iris stroma rather than on the surface of the iris*</p> <p>Avoid any apparent iris vessels</p> <p>Use the least amount of energy that is effective¹³⁹</p> <p>Lens capsule damage is possible above 2 mJ energy</p> <p>With most Lasers less than 5 mJ per pulse is required</p>

* Pretreatment with argon laser to minimize bleeding by coagulating iris vessels is optional (spot size 400 µm, duration 0.2 sec, energy approximately 200-300 mW).

In case of thick dark irides, to reduce total Nd:YAG energy, pretreatment with argon laser in 2 stages may be considered¹⁴¹ [II,B]. In the first stage a low power argon of 90-250 mW, duration 0.05 sec, spot size 50mm is applied, followed by the high power argon of 700 mW, duration 0.1 sec, spot size 50 mm to create a punched-out crater appearance. Laser iridotomy is completed with Nd:YAG laser.

Laser parameters for continuous-wave Argon laser iridotomy

When no Nd:YAG laser is available, Argon laser may be used [II,D].

Laser parameters should be individualized to each patient and adjusted appropriately during the procedure.

The following parameters are suggested [II,D]:

Medium brown irides	
<i>Preparatory stretch burns</i>	
Spot size	200-500 μ m
Exposure time	0.2-0.6 sec
Power	200-600 mW
<i>Penetration burns [II,D]</i>	
Spot size	50 μ m
Exposure time	0.1-0.2 sec
Power	700-1500 mW (average 1000 mW)
Pale blue or hazel irides	
<i>1st step: to obtain a gas bubble</i>	
Spot size	50 μ m
Exposure time	0.5 sec
Power	Up to 1500 mW
<i>2nd step: penetration through the gas bubble</i>	
Spot size	50 μ m
Exposure	0.05 sec
Power	1000 mW
Thick, dark brown irides (chipping technique)	
Spot size	50 μ m
Exposure time	0.02 sec
Power	1500 mW

Complications:

- Intraoperative complications
Bleeding from the iridotomy site; this can usually be stopped by gentle pressure applied to the eye with the contact lens. With the argon laser corneal epithelial and/or endothelial burns may develop.
- Postoperative
Visual disturbances occur in 6-12% (glare, blurring, ghost images, halo, crescent) are less likely to occur when the iridotomy is completely covered by the eyelid^{142, 143}.

Transient elevation of the IOP is the most common complication in the early period. Elevation of IOP at 1 hour after iridotomy occurs in approximately 10% of primary angle closure suspect eyes¹⁴⁴. Acute and (chronic) rise in IOP is more likely to occur in eyes with peripheral anterior synechiae in whom the small amount of trabecular meshwork not closed is likely to have compromised outflow function (and is secondarily closed by the iris pigment and tissue generated by the iridotomy).

Postoperative inflammation is transient and mild, rarely resulting in posterior synechiae. Closure of the iridotomy may occur during the first few weeks after the procedure, due to accumulation of debris and pigment granules.

Rare complications include sterile hypopyon, cystoid macular oedema, retinal haemorrhages and malignant glaucoma^{145,146}.

Postoperative management:

Check the IOP after 1-3 hours [II,D].

Topical corticosteroids for 4-7 days instilled 3-4 times a day.

Check the angle regularly with gonioscopy, and the patency of peripheral iridotomy.

If the patency is uncertain check with gonioscopy, reconsider the mechanism, perform ultrasound biomicroscopy (UBM) / anterior segment-optical coherence tomography (AS-OCT) if available and/or repeat the iridotomy.

Retroillumination alone for judging the patency is insufficient.

3.5.2 Laser Trabeculoplasty (LT)¹⁴⁷⁻¹⁵⁴

Indications: [I,D]

Lowering of IOP in primary open-angle, exfoliative and pigmentary glaucoma, high risk ocular hypertension (OH):

- 1) When IOP is not satisfactorily controlled with medications (i.e. efficacy, tolerability and adherence)
- 2) As initial treatment (See FC VII)

Preoperative preparation: [I,B]

For prevention of IOP spikes instillation of topical alpha 2 agonist (apraclonidine 1% or brimonidine) 1 hour prior to the procedure and immediately afterwards is optional. Use topical anesthesia.

Procedure:

Most frequently used lasers are:

- Argon continuous-wave laser (green or blue/green) - argon laser trabeculoplasty (ALT)
- Q-switched, short pulsed, frequency-doubled Nd:YAG (532 nm) laser - selective laser trabeculoplasty (SLT)

Lenses: Goldmann type gonioscopy lens, Ritch trabeculoplasty lens©, CGA©, Meridian, Latina (SLT), Magnaview.

Identify angle landmarks after inspection of all quadrants and place the laser burns between the anterior pigmented trabecular meshwork (TM) and the non-pigmented trabecular meshwork over 180° or 360°.

Laser parameters for laser trabeculoplasty

Laser parameters [I, D]	ALT	SLT
Spot size	50 µm	400 µm
Exposure	0.1 sec	3 nsec (fixed)
Power	500-1200 mW according to the reaction on the TM; with heavily pigmented TM low power is sufficient	0.4 to 1.2 mJ according to the desired reaction; in heavily pigmented TM start with low levels e.g. 0.4 mJ
Optimal reaction	Transient bleaching or small gas bubble formation	The power is titrated until the appearance of tiny air bubbles, »champagne bubbles«, at the site of the laser burn, then the power is reduced by increments of 0.1 mJ until there are no visible bubbles*
Number of spots	50-100 evenly spaced spots over 180-360°	50-100 non-overlapping spots spaced over 180 -360°

* some continue with the power that causes champagne bubble formation

Complications:

Transient elevation of IOP^{155,156}

Inflammation (mild)

Peripheral anterior synechiae (after ALT)

Corneal endothelial damage in corneas with pigment on endothelium (after SLT)¹⁵⁷.

Post-operative management: [I,D]

Check IOP in selected patients (e.g. with advanced glaucomatous damage, one-eyed patients, high pre-laser IOP, exfoliation syndrome, heavily pigmented trabecular meshwork). Use of topical corticosteroids or non-steroidal anti-inflammatory medication 3-4 times daily for 4-7 days.

Effectiveness of laser trabeculoplasty:

ALT and SLT have the same efficacy^{153,158}.

Laser trabeculoplasty is initially effective in 80 to 85% of treated eyes with a mean IOP reduction of 20 to 25% (of 6 to 9 mmHg). The effect wears off over time, for both ALT and SLT¹⁵⁹.

LT versus medication: In the Glaucoma Laser Trial, after 7 years of follow-up, patients with ALT had lower IOP (1.2 mmHg) than patients on medical treatment, and no difference in progression of glaucoma¹⁶⁰. SLT has shown to decrease IOP to a degree similar to that of prostaglandin analogues after 9 to 12 months follow-up¹⁶¹ and appears to be repeatable (30,31).

Predictors of efficacy:

Higher baseline IOP is associated with greater IOP reduction after SLT and ALT^{162,163}.

The effectiveness of ALT is influenced by the treating surgeon, and success is better when surgeons have more experience in ALT^{163,164}.

Pigmentation of the trabecular meshwork (TM) is important. ALT is less successful in eyes with no pigmentation of TM. SLT seems to be independent of the pigmentation of TM. Younger subjects (less than 40 years old) usually respond less to ALT¹⁶⁵.

3.5.3 Laser Iridoplasty^{166,167}

Main Indication: [II,D]

Plateau iris syndrome confirmed by a patent iridotomy; the purpose is to enlarge the peripheral angle approach after iridotomy, to decrease the chance of progressive synechial closure.

Lasers:

Different types of continuous wave lasers can be used for photocoagulation, most frequently: argon laser, diode laser (810 nm), and the frequency-doubled Nd:YAG laser (532 nm).

Preoperative preparation: [II,D]

Instillation of Pilocarpine followed by the same preoperative preparation as for laser trabeculoplasty.

Lens: Abraham (+66 diopters), Wise (+103 diopters), CGI©LASAG CH lens or the central non-mirrored part of the Goldmann lens.

Contraindications: [I,D]

Flat anterior chamber
Extensive peripheral anterior synechiae.

Laser parameters [II,D]

Laser parameters [II,D]	Contraction burns (long duration-low power-large spot size)
Spot size	200-500 µm
Exposure	0.3-0.6 sec
Power	200-400 mW
Location	Aiming beam should be directed at the most peripheral part of the iris
Optimal reaction	Visible contraction of the peripheral iris with flattening of the iris curvature (without bubble formation or pigment release)
Number of spots	20-24 spots over 360° leaving 2 beam diameters between each spot and avoiding visible radial vessels

Complications:

Mild iritis
Corneal endothelial burns
Transient elevation of IOP
Post-operative synechiae of the pupil
Permanent pupil dilation
Iris atrophy
Non-dilatable pupil

Post-operative management:

Topical corticosteroids or non-steroidal anti-inflammatory medication instilled for 4-7 days
Prevention of IOP spikes

3.5.4 Cyclophotocoagulation¹⁶⁸⁻¹⁷⁰

Indications: [II,D]

When filtration surgery or tubes are likely to fail, have failed, or are not feasible
As an alternative to drainage devices

Lasers used:

Diode laser (810 nm); Argon laser

Modes of laser delivery are: trans-scleral, endoscopic and transpupillary

Trans-scleral cyclophotocoagulation:

Laser diode cyclophotocoagulation with the G probe is the cyclodestructive procedure of choice because of the reduced incidence of complications compared with other cyclodestructive procedures [I,D].

Ultrasonic cyclodestruction:

Ultrasonic circular cyclocoagulation using high-intensity focused ultrasound delivered by a circular miniaturized device was reported as a safe and effective technique to reduce intraocular pressure in patients with refractory glaucoma^{171,172}.

Technique: [II,D]

Transcleral cyclophotocoagulation with diode laser and G probe	
Anesthesia	Retrobulbar or peribulbar injection of a 50:50 mixture of 2% lidocaine and 0.75% bupivacaine with hyaluronidase
G probe positioning	The G probe footplate is placed on the conjunctiva with the short side adjacent to the limbus, which positions the fiberoptic tip 1.2 mm behind the limbus. The ciliary body should be identified with transillumination as its position may vary and the placement of the G probe is adjusted accordingly ¹⁷³
Scleral transillumination	The fibre optic light source is directed approx. 4 mm posterior to corneoscleral limbus to identify ciliary body by transillumination. The dark demarcation line indicates the anterior margin of the ciliary body
Settings	Recommended setting: duration of 2 sec., from 1500 mW for dark to 2000 mW for light-coloured irides and increase the energy until an audible »pop« is heard indicating tissue disruption. If a »pop« sound occurs during two sequential subsequent laser applications, the power is reduced by 150 mW and treatment completed at this power ¹⁷⁴
Applications	10-20 over 180°, energy 5-6 J per pulse, total treatment per session up to 270° of circumference avoiding 3 and 9 o'clock positions (to avoid long posterior ciliary nerves). Some surgeons prefer to use low energy and more applications. Retreatments are often needed, but the incidence of severe complications is low [II,D].

Endoscopic cyclophotocoagulation:

Endoscopic techniques combined with laser technology allow the photocoagulation of ciliary processes not visible via the transpupillary route. The approach can be limbal or through pars plana. Recently, endoscopic cyclophotocoagulation is most commonly performed in conjunction with cataract surgery in cases with early glaucoma¹⁷⁵.

Transpupillary cyclophotocoagulation:

This procedure is limited to eyes in which a sufficient number of ciliary processes can be visualized gonioscopically, as in cases of aniridia, through a large surgical iridectomy or when broad anterior synechiae cause anterior displacement of the iris. New technology using ultra-sound cyclodestruction is currently under investigation.

Complications:^{169,176}

- Rates of complications are higher in neovascular glaucoma and with treatment protocols using more than 80 J per session.
- Persistent inflammation
- Hyphaema
- Corneal decompensation
- Vision loss
- Hypotony and phthisis

Post-operative management: [II,D]

Consider analgesia. Topical corticosteroids and atropine instillation for 2-3 weeks. In the immediate postoperative period IOP should be monitored and the anti-glaucoma medication tapered accordingly. The effectiveness of treatment is assessed after 4 weeks.

3.6 - INCISIONAL SURGERY

3.6.1 General Principles

The different techniques of incisional surgery have different indications depending on the type of glaucoma. Their adoption depends on: [I,D]

1. the target IOP chosen for the individual situation
2. the previous history (surgery, medications, degree of visual field loss)
3. the risk profile (i.e. single eye, occupation, refractive status)
4. the preferences and experience of the surgeon
5. the patient opinion, expectation and postoperative compliance

The decision to recommend glaucoma surgery should be made in the light of published clinical trials^{54,177}. In the individual patient, a multitude of factors must be taken into account when deciding treatment including compliance, stage of glaucoma etc. Nevertheless, surgery should be considered whenever medical or laser treatment would appear unlikely to maintain sight in the glaucomatous eye [I,D]. It should not be left as a last resort (See Ch. 3.1). Angle-closure glaucoma is usually initially approached by laser iridotomy or peripheral iridectomy. Primary congenital glaucoma is usually treated with surgery, likely trabeculotomy or goniotomy, or combinations of filtration surgery with antifibrotic agents.

For repeated surgery, cyclodestructive procedures and tube implants are more commonly used (See FC VI).

3.6.2 Techniques

Since glaucoma surgery is successfully practiced in different ways by different ophthalmologists, a detailed description of surgical techniques is not within the scope of this text.

The primary goal of surgery is to achieve a Target IOP without additional medication. Additional medications can be used if a Target IOP is not reached by surgery alone. Success rates of a surgical method in terms of IOP lowering can be best evaluated in the absence of adjunctive medical treatment. The number of preoperative versus postoperative medications may also depend on the variable compliance of the individual patient before and after surgery. Also, it is useful to count the percentage of “successes” below a defined IOP level as in Fig. 3.3. It is also important to consider not just the IOP but complications rates and, most importantly, functional outcomes.

3.6.2.1 Penetrating Glaucoma Surgery

3.6.2.1.1 Trabeculectomy

The most widely used surgical procedure in OAG is the trabeculectomy, which produces a 'guarded' fistula between the anterior chamber and the subconjunctival space^{178,179}. The introduction of improved operating microscopes, instruments and suture materials, has led to numerous modifications and refinements of the original operation¹⁸⁰. Modifications include the size, shape and thickness of the scleral flap, limbal or fornix based conjunctival flaps, fixed, releasable or adjustable sutures and the use of antimetabolites and other antiscarring agents delivered in different ways to reduce wound healing^{181,182}. In the hands of experts the long-term success rate of filtering surgery alone, or with adjunctive medical therapy in a previously unoperated eye has been reported at up to 90%¹⁷⁸; there are large differences however in the criteria used for the definition of success and in the final success rates observed¹⁸³⁻¹⁹².

The use of stainless steel implants as facilitators for performing filtration surgery should be weighted against the cost of the devices¹⁹³⁻¹⁹⁶.

Long-term IOP control is achieved in many cases, although some patients do require further therapy or repeat surgery^{178,197,198}.

The alternatives to trabeculectomy in OAG include non-penetrating surgeries and drainage devices^{196,199-205}.

Indications: [II,D]

1. In cases where other forms of therapy, like medicines or laser, have failed.
2. In cases where other forms of therapy are not suitable (e.g. where compliance or side-effects are a problem) or appropriate medical treatment is not available.
3. In cases where a Target Pressure is required to prevent clinically significant disease progression that cannot be reached with topical medications and/or laser.
4. In cases which have such advanced glaucoma and high IOP at presentation that other forms of treatment are unlikely to be successful.

Some studies have indicated that in terms of field survival, primary trabeculectomy was superior to medical treatment, but these studies may not be relevant to current medical practice as the evaluation of visual field was not done using today's analyses, and the medical treatment options were very limited²⁰⁶. More recent studies suggest that visual field progression is not significantly different whether initial treatment is medication or trabeculectomy^{207, 208}.

The ophthalmologist must assess the risks and benefits of early surgery in each individual case.

Long-term risks of trabeculectomy:

Accelerated progression of senile cataracts is frequently seen after filtration surgery^{209,210}. Patients undergoing trabeculectomy should be advised on the symptoms of a developing blebitis/endophthalmitis including red eye, tearing, discharge or decreased vision, and should be warned to immediately seek the help of an ophthalmologist if any of these

symptoms develop in the operated eye²¹¹ [I,D]. Endophthalmitis is more common if the bleb is thin and cystic - a situation more commonly found with the use of a small treatment area of antimetabolites or full thickness filtration procedures. A long-tube drainage device should be used if the bleb cannot be sited beneath the upper lid [I,D].

3.6.2.1.2 Trabeculotomy

Trabeculotomy, alone or combined with trabeculectomy, is generally used for congenital and paediatric glaucoma and is less effective in adults²¹²⁻²¹⁴ [I,B]. It also may decrease the need for further filtering and shunting procedures²¹⁵.

A novel glaucoma procedure of trabeculotomy by internal approach was recently introduced^{183,216,217}.

3.6.2.2 Non-Penetrating Glaucoma Surgery

3.6.2.2.1 Deep Sclerectomy

In this technique, a deep lamella of corneosclera underneath the scleral flap is excised thus removing the outer wall of Schlemm's canal. The outer layer of the inner wall of Schlemm's canal is frequently also removed. Percolation of aqueous occurs through the porosity of the remaining trabecular meshwork, possibly through micro-perforations. When the scleral flap is repositioned, a "scleral lake" is created. A collagen implant or a hyaluronic acid device is often used to keep this scleral lake open. In a number of cases, a filtration bleb forms; long-term IOP levels appear higher than with trabeculectomy²¹⁸⁻²²⁸.

3.6.2.2.2 Visco canalostomy

In this technique, hyaluronic acid is injected into Schlemm's canal in addition to the dissection and excision of a deep lamella. The mechanism claimed to increase the outflow is the widening of Schlemm's canal and of the collector channels as well as diffusion of aqueous from the "scleral lake"^{186,229,230}.

The majority of randomised controlled trials suggests that the pressure lowering of non-penetrating glaucoma surgery is not as marked as with trabeculectomy²³¹⁻²³⁴.

3.6.2.2.3 Canaloplasty

Canaloplasty is a non-penetrating, bleb-independent, glaucoma surgery that combines a 2-flap dissection to the trabeculo-Descemet's membrane, like in visco canalostomy methods, with a circumferential catheterization and viscodilation of Schlemm's canal. In addition, a 10-0 polypropylene suture is placed within the canal to tension the inner wall and the associated trabecular meshwork with the intention of preventing the Schlemm's canal collapse thus in theory restoring natural trabeculocanalicular aqueous outflow^{229,235-238}.

This technique is indicated in POAG, pigmentary glaucoma and pseudoexfoliative glaucoma and permits combined procedures with cataract surgery [II,D].

Contraindications to canaloplasty are primary or secondary ACG, neovascular glaucoma or cases needing a low target IOP.

Intraoperative or postoperative complications (hyphema, hypotony secondary to a break in the trabeculo-descemetoc window, hypertension, cataract, endophthalmitis) have a lower incidence than trabeculectomy²³⁹⁻²⁴².

Arguments in favour of non-penetrating glaucoma surgery:

- minimal postoperative care (no bleb management)
- reduced incidence of hypotony-related complications and cataract
- reduced incidence of intraoperative complications (iris prolapse, expulsive haemorrhage)

Arguments against non-penetrating glaucoma surgery:

- less efficient in IOP reduction (mean IOP 2-4 mmHg higher) than after trabeculectomy
- difficult technique (learning curve)
- Nd:YAG laser goniopuncture often needed for IOP control
- Anatomical unpredictability

Arguments in favour of trabeculectomy:

- lower long-term postoperative IOP
- fewer IOP-lowering medications needed postoperatively

Arguments against trabeculectomy:

- possible higher rate of cataract formation
- postoperative bleb complications
- higher risk of postoperative hypotony and related complications (choroidal detachment)

3.6.3 Methods of Preventing Filtering Bleb Scarring

3.6.3.1 Antimetabolites

Wound healing is one of the main determinants of the long-term intraocular pressure control after filtering surgery^{243,244}. Excessive wound healing or repair leads to scar formation in the conjunctiva. Risk factors for conjunctival scarring are young age, afro-caribbean/hispanic race, inflammatory eye disease (e.g. uveitis, ocular pemphigoid, Stevens-Johnson syndrome), long-term multiple topical medical therapy, aphakia by intracapsular surgery, recent intraocular surgery (<3 months), previous conjunctival incisional surgery, previous failed glaucoma filtration surgery, neovascular glaucoma^{188,245}. Antimetabolites such as 5-fluorouracil (5-FU) and mitomycin-C (MMC) are frequently used in patients undergoing glaucoma filtration surgery in order to reduce postoperative conjunctival scarring and improve drainage [I,A].

The use of these substances continues to be refined. Indications and techniques need to be carefully considered, particularly the use of larger antimetabolite treatment areas to minimise thin cystic blebs^{246,247} [I,D].

The risk of corneal epithelial erosions, epitheliopathy, late hypotony, bleb leaks, and blebitis/endophthalmitis must be considered [I,D]. The use of antimetabolites, especially MMC, is potentially hazardous, and requires careful surgical technique to prevent over drainage and hypotony, or a thin focal drainage bleb with a higher risk of infection [I,D]. New antifibrotic agents and techniques are under investigation to more specifically target and modulate the biological processes of wound healing after filtration surgery, aiming for a lower risk of complications^{243,248-250}.

3.6.3.1.1 General Precautions

The use of antimetabolites will enhance the unfavourable effect of any imprecision during surgery. It is important to assess each individual case for risk factors, and/or for the need of low target IOP and titrate the substance and dosage used accordingly based on local experience.

If aqueous flow is not well controlled persistent hypotony will occur. Strategies to increase control of flow include smaller sclerostomies, larger and/or thicker scleral flaps, tighter suturing of the scleral flap, and releasable or adjustable sutures [II,D].

Research studies suggest that a large surface area of cytotoxic treatment together with large scleral flaps and accurately sutured fornix-based conjunctival flaps lead to more diffuse, posteriorly extended non-cystic blebs giving a considerable reduction in bleb-related complications such as blebitis and endophthalmitis^{197,247,251,252} [I,B].

It is advisable for a surgeon not familiar with these drugs to start with weaker agents (e.g. 5-FU rather than MMC) or lower concentrations of MMC [II,D].

Antimetabolites should not enter the eye [I,D]. 5-FU has a pH of 9.0 and one drop (0.05 ml) of MMC is enough to cause irreversible endothelial damage: precautions for use and disposal of cytotoxic substances should be observed [I,D].

5-FU and MMC are not officially approved for ocular applications. Their use in many cases as adjunctive in filtration surgery, however, has become standard clinical practice.

3.6.3.1.2 Administration

5-Fluorouracil:

- Intraoperative use [II,D]

Concentration: 25 or 50 mg/ml undiluted solution.

Administration: intraoperatively on a filter paper or a sponge.

Time of exposure: usually 5 minutes (shorter time has minimal effect).

Rinse: with at least 20 ml of balanced salt solution.

- Postoperative use [II,D]

Relative contraindication if epithelial problems present.

Concentration: 0.1 ml injection of 50 mg/ml undiluted solution.

Administration: adjacent to but not into bleb (pH 9), with a small calibre needle (e.g. 30 G needle on insulin syringe). Reflux from the injection site over the ocular surface should be prevented²⁵³. Repeated injections are often necessary.

Mitomycin C:

- Intraoperative use [II,D]

Concentration: 0.1-0.5 mg/ml (care must be taken in diluting it to the desired concentration).

Administration: intraoperatively on a filter paper or a sponge. Avoid contact with cut edge of conjunctive flap.

Time of exposure: 1-5 minutes.

Rinse: with at least 20 ml of balanced salt solution.

- Postoperative use [II,D]

Concentration: 0.1 ml injection of 0.02 mg/ml solution.

Administration: adjacent to but not into bleb, with a small calibre needle (e.g. 30 G needle on insulin syringe). Reflux from the injection site over the ocular surface should be prevented²⁵³. A very small amount of MMC entering the eye will irreversibly damage the endothelium. It is useful for some needling procedures but recommended only in experienced hands.

3.6.3.2 Alternative Methods of Preventing Filtering Bleb Scarring

Irradiation, PDT and inhibition of growth factors have been used, but no long-term clinical studies to support their use are yet available^{243,249}.

Alternative Glaucoma Surgery

New alternative surgical techniques with the aim obtaining a higher safety profile than filtration surgery were proposed during the last several years. Under the acronym of M.I.G.S. "Minimally Invasive Glaucoma Surgery" are now collectively grouped both ab-interno and ab-externo procedures, not necessarily involving the use of an implantable device, not always bleb-independent for efficacy. The general aim would be to entail significantly less tissue manipulation than filtration surgery, with less side effects and sizeable IOP-lowering efficacy. There are no well controlled comparative

trials available to support the superiority among any of these procedures nor versus trabeculectomy, for both safety and efficacy^{254,255}. These techniques are currently performed in selected glaucoma patients with early to moderate disease and preferably in combination with cataract surgery [II,D].

ALTERNATIVE GLAUCOMA SURGERY (*)

Based on subconjunctival filtration

- trans-scleral filtration, ab-interno device (AqueSys Xen)
- trans-scleral filtration, ab-externo device (InnFocus Microshunt)

Based on suprachoroidal drainage

- suprachoroidal stents, ab-interno (Glaukos iStent Supra, Transcend CyPass)

Based on Schlemm's canal drainage/bypass/expansion

- trabecular bypass stents/canal expanders (Glaukos iStent, Ivantis Hydrus)
- ab-Interno trabeculectomy (Trabectome)
- ab-externo canaloplasty/trabeculotomy (iScience catheter)

(*) THIS LIST IS NOT ALL INCLUSIVE. The EGS does not endorse any product or procedures.

3.6.4 Complex Cases

Complicated glaucoma cases such as those that have failed previous surgery, secondary glaucomas, congenital glaucomas, et cetera require specialist treatment. In addition to trabeculectomy, other forms of therapy may be necessary such as drainage devices and ciliary body ablation.

3.6.5 Long-Tube Drainage Devices

The use of long-tube drainage devices such as those described by Molteno²⁵⁶⁻²⁶³, Krupin²⁶⁴⁻²⁶⁶, Baerveldt²⁶⁷⁻²⁷², Ahmed^{268,273-280} or Schocket²⁸¹⁻²⁸⁴ are generally reserved for patients with risk factors for a poor result with trabeculectomy with antimetabolite [II,D], although recent trials established their efficacy and safety as a primary surgical procedure^{258,285} [II,B].

Factors that decrease the chances of successful trabeculectomies and, therefore, make tube surgery attractive, include previous failed filtering surgery with antimetabolites, excessive conjunctival scarring due to previous ocular surgery with severe conjunctival or surface disease, active neovascular disease, paediatric aphakia, or where filtration surgery is going to be technically difficult^{286,287} [II,D].

3.7 - CATARACT AND GLAUCOMA SURGERY

When glaucoma surgery is indicated and there is a visually significant cataract the two procedures can be performed combined or sequentially. The decision is to be made according to the clinical findings, after discussing with the patients advantages and disadvantages of each approach [I,D].

In case of angle closure or narrow angle approach, it is important to evaluate the lens as a component of the raised IOP [I,D] (See also Ch 2.4)

Small-incision phacoemulsification cataract extraction is one of the most relevant surgical advances for our glaucoma patients. It allows faster and better visual recovery, and with appropriate techniques it is safely applicable in cases with small pupil, shallow AC or pre-existing filtering blebs. Furthermore it can be combined effectively and safely with filtering procedures, including trabeculectomy, miniature drainage implants and deep sclerectomy^{205,288-290}.

Different new glaucoma surgical techniques which can be combined with phacoemulsification (i.e endoscopic cyclophotocoagulation, trabecular bypass stents, ab interno trabeculectomy and canaloplasty) have been proposed in the last years²⁹¹.

Randomized clinical trials are presently needed to clarify this topic.

Despite the improved results of small incision phacoemulsification and of filtration surgery with anti-metabolites there is no evidence to support a generalized switch from sequential to combined surgery and viceversa [I,D].

In summary:

- Modern phacoemulsification with clear cornea incisions does not interfere with subsequent glaucoma surgical procedures²⁹²
- The development or worsening of a visually significant cataract is common after glaucoma surgery²⁰⁹
- Cataract surgery performed after trabeculectomy can affect the IOP control^{209,293}
- Cataract surgery alone may be of limited benefit in lowering the IOP in open angle glaucoma and the effect appears to be proportional to the preoperative IOP values; such effect may be greater in angle closure glaucoma / narrow angles and appears to be proportional to the degree of anterior chamber opening²⁹⁴⁻²⁹⁶
- Combined procedures allow for greater IOP reduction and fewer IOP spikes in the immediate postoperative period than phacoemulsification alone²⁹⁷⁻²⁹⁹
- The success rate of combined phacoemulsification and filtration surgery is usually not as favourable as filtration surgery alone and the use of antimetabolites is recommended in all cases.

References:

1. Katz J, Gilbert D, Quigley HA, Sommer A. Estimating progression of visual field loss in glaucoma. *Ophthalmology* 1997;104(6):1017-25.
2. Rasker MT, van den Enden A, Bakker D, Hoyng PF. Rate of visual field loss in progressive glaucoma. *Archives of ophthalmology* 2000;118(4):481-8.
3. Pereira ML, Kim CS, Zimmerman MB, et al. Rate and pattern of visual field decline in primary open-angle glaucoma. *Ophthalmology* 2002;109(12):2232-40.
4. Bengtsson B, Patella VM, Heijl A. Prediction of glaucomatous visual field loss by extrapolation of linear trends. *Archives of ophthalmology* 2009;127(12):1610-5.
5. Cedrone C, Nucci C, Scuderi G, et al. Prevalence of blindness and low vision in an Italian population: a comparison with other European studies. *Eye (Lond)* 2006;20(6):661-7.
6. Forsman E, Kivela T, Vesti E. Lifetime visual disability in open-angle glaucoma and ocular hypertension. *Journal of glaucoma* 2007;16(3):313-9.
7. Peters D, Bengtsson B, Heijl A. Factors associated with lifetime risk of open-angle glaucoma blindness. *Acta Ophthalmol* 2013.
8. Martus P, Stroux A, Budde WM, et al. Predictive factors for progressive optic nerve damage in various types of chronic open-angle glaucoma. *Am J Ophthalmol* 2005;139(6):999-1009.
9. Peters D, Bengtsson B, Heijl A. Factors associated with lifetime risk of open-angle glaucoma blindness. *Acta ophthalmologica* 2013.
10. The Advanced Glaucoma Intervention Study (AGIS): 7. The relationship between control of intraocular pressure and visual field deterioration. The AGIS Investigators. *Am J Ophthalmol* 2000;130(4):429-40.
11. The Advanced Glaucoma Intervention Study (AGIS): 12. Baseline risk factors for sustained loss of visual field and visual acuity in patients with advanced glaucoma. *Am J Ophthalmol* 2002;134(4):499-512.
12. Heijl A, Buchholz P, Norrgren G, Bengtsson B. Rates of visual field progression in clinical glaucoma care. *Acta ophthalmologica* 2013;91(5):406-12.
13. Heijl A, Bengtsson B, Hyman L, Leske MC. Natural history of open-angle glaucoma. *Ophthalmology* 2009;116(12):2271-6.
14. Chauhan BC, Garway-Heath DF, Goni FJ, et al. Practical recommendations for measuring rates of visual field change in glaucoma. *The British journal of ophthalmology* 2008;92(4):569-73.
15. Chauhan BC, Mikelberg FS, Artes PH, et al. Canadian Glaucoma Study: 3. Impact of risk factors and intraocular pressure reduction on the rates of visual field change. *Archives of ophthalmology* 2010;128(10):1249-55.
16. Ahrlich KG, De Moraes CG, Teng CC, et al. Visual field progression differences between normal-tension and exfoliative high-tension glaucoma. *Investigative ophthalmology & visual science* 2010;51(3):1458-63.
17. Comparison of glaucomatous progression between untreated patients with normal-tension glaucoma and patients with therapeutically reduced intraocular pressures. Collaborative Normal-Tension Glaucoma Study Group. *Am J Ophthalmol* 1998;126(4):487-97.
18. The effectiveness of intraocular pressure reduction in the treatment of normal-tension glaucoma. Collaborative Normal-Tension Glaucoma Study Group. *Am J Ophthalmol* 1998;126(4):498-505.
19. Leske MC, Heijl A, Hyman L, et al. Predictors of long-term progression in the early manifest glaucoma trial. *Ophthalmology* 2007;114(11):1965-72.

20. Broman AT, Quigley HA, West SK, et al. Estimating the rate of progressive visual field damage in those with open-angle glaucoma, from cross-sectional data. *Invest Ophthalmol Vis Sci* 2008;49(1):66-76.
21. Chauhan BC, Garway-Heath DF, Goni FJ, et al. Practical recommendations for measuring rates of visual field change in glaucoma. *Br J Ophthalmol* 2008;92(4):569-73.
22. Bengtsson B, Heijl A. A visual field index for calculation of glaucoma rate of progression. *Am J Ophthalmol* 2008;145(2):343-53.
23. Heijl A, Bengtsson B, Chauhan BC, et al. A comparison of visual field progression criteria of 3 major glaucoma trials in early manifest glaucoma trial patients. *Ophthalmology* 2008;115(9):1557-65.
24. Tielsch JM, Sommer A, Katz J, et al. Racial variations in the prevalence of primary open-angle glaucoma. The Baltimore Eye Survey. *JAMA* 1991;266(3):369-74.
25. Mitchell P, Smith W, Attebo K, Healey PR. Prevalence of open-angle glaucoma in Australia. The Blue Mountains Eye Study. *Ophthalmology* 1996;103(10):1661-9.
26. Quigley HA, Jampel HD. How are glaucoma patients identified? *J Glaucoma* 2003;12(6):451-5.
27. Grodum K, Heijl A, Bengtsson B. A comparison of glaucoma patients identified through mass screening and in routine clinical practice. *Acta Ophthalmol Scand* 2002;80(6):627-31.
28. Heijl A, Leske MC, Bengtsson B, et al. Reduction of intraocular pressure and glaucoma progression: results from the Early Manifest Glaucoma Trial. *Arch Ophthalmol* 2002;120(10):1268-79.
29. Lichter PR, Musch DC, Gillespie BW, et al. Interim clinical outcomes in the Collaborative Initial Glaucoma Treatment Study comparing initial treatment randomized to medications or surgery. *Ophthalmology* 2001;108(11):1943-53.
30. The Glaucoma Laser Trial (GLT): 6. Treatment group differences in visual field changes. Glaucoma Laser Trial Research Group. *Am J Ophthalmol* 1995;120(1):10-22.
31. Gherghel D, Orgul S, Gugleta K, et al. Relationship between ocular perfusion pressure and retrobulbar blood flow in patients with glaucoma with progressive damage. *Am J Ophthalmol* 2000;130(5):597-605.
32. Flammer J, Orgul S, Costa VP, et al. The impact of ocular blood flow in glaucoma. *Prog Retin Eye Res* 2002;21(4):359-93.
33. Grieshaber MC, Mozaffarieh M, Flammer J. What is the link between vascular dysregulation and glaucoma? *Surv Ophthalmol* 2007;52 Suppl 2:S144-54.
34. Tielsch JM, Katz J, Sommer A, et al. Hypertension, perfusion pressure, and primary open-angle glaucoma. A population-based assessment. *Arch Ophthalmol* 1995;113(2):216-21.
35. Sommer A. Glaucoma risk factors observed in the Baltimore Eye Survey. *Curr Opin Ophthalmol* 1996;7(2):93-8.
36. Leske MC, Wu SY, Nemesure B, Hennis A. Incident open-angle glaucoma and blood pressure. *Arch Ophthalmol* 2002;120(7):954-9.
37. Leske MC, Wu SY, Hennis A, et al. Risk factors for incident open-angle glaucoma: the Barbados Eye Studies. *Ophthalmology* 2008;115(1):85-93.
38. Khawaja AP, Crabb DP, Jansonius NM. The role of ocular perfusion pressure in glaucoma cannot be studied with multivariable regression analysis applied to surrogates. *Invest Ophthalmol Vis Sci* 2013;54(7):4619-20.
39. Osborne NN, Chidlow G, Layton CJ, et al. Optic nerve and neuroprotection strategies. *Eye (Lond)* 2004;18(11):1075-84.
40. Hare W, WoldeMussie E, Lai R, et al. Efficacy and safety of memantine, an NMDA-type open-channel blocker, for reduction of retinal injury associated with experimental glaucoma

- in rat and monkey. *Surv Ophthalmol* 2001;45 Suppl 3:S284-9; discussion S95-6.
41. Hare WA, WoldeMussie E, Lai RK, et al. Efficacy and safety of memantine treatment for reduction of changes associated with experimental glaucoma in monkey, I: Functional measures. *Invest Ophthalmol Vis Sci* 2004;45(8):2625-39.
 42. Hare WA, WoldeMussie E, Weinreb RN, et al. Efficacy and safety of memantine treatment for reduction of changes associated with experimental glaucoma in monkey, II: Structural measures. *Invest Ophthalmol Vis Sci* 2004;45(8):2640-51.
 43. Yucel YH, Gupta N, Zhang Q, et al. Memantine protects neurons from shrinkage in the lateral geniculate nucleus in experimental glaucoma. *Arch Ophthalmol* 2006;124(2):217-25.
 44. Krupin T, Liebmann JM, Greenfield DS, et al. A randomized trial of brimonidine versus timolol in preserving visual function: results from the Low-Pressure Glaucoma Treatment Study. *Am J Ophthalmol* 2011;151(4):671-81.
 45. Sena DF, Lindsley K. Neuroprotection for treatment of glaucoma in adults. The Cochrane database of systematic reviews 2013;2:CD006539.
 46. Jampel HD. Target pressure in glaucoma therapy. *J Glaucoma* 1997;6(2):133-8.
 47. Oliver JE, Hattenhauer MG, Herman D, et al. Blindness and glaucoma: a comparison of patients progressing to blindness from glaucoma with patients maintaining vision. *Am J Ophthalmol* 2002;133(6):764-72.
 48. Johnson DH. Progress in glaucoma: early detection, new treatments, less blindness. *Ophthalmology* 2003;110(4):634-5.
 49. Forsman E, Kivela T, Vesti E. Lifetime visual disability in open-angle glaucoma and ocular hypertension. *J Glaucoma* 2007;16(3):313-9.
 50. Damji KF, Behki R, Wang L. Canadian perspectives in glaucoma management: setting target intraocular pressure range. *Can J Ophthalmol* 2003;38(3):189-97.
 51. Chauhan BC, Mikelberg FS, Artes PH, et al. Canadian Glaucoma Study: 3. Impact of risk factors and intraocular pressure reduction on the rates of visual field change. *Arch Ophthalmol* 2010;128(10):1249-55.
 52. Kass MA, Heuer DK, Higginbotham EJ, et al. The Ocular Hypertension Treatment Study: a randomized trial determines that topical ocular hypotensive medication delays or prevents the onset of primary open-angle glaucoma. *Arch Ophthalmol* 2002;120(6):701-13; discussion 829-30.
 53. Miglior S, Zeyen T, Pfeiffer N, et al. Results of the European Glaucoma Prevention Study. *Ophthalmology* 2005;112(3):366-75.
 54. Boland MV, Ervin AM, Friedman DS, et al. Comparative effectiveness of treatments for open-angle glaucoma: a systematic review for the U.S. Preventive Services Task Force. *Ann Intern Med* 2013;158(4):271-9.
 55. Leske MC, Heijl A, Hussein M, et al. Factors for glaucoma progression and the effect of treatment: the early manifest glaucoma trial. *Arch Ophthalmol* 2003;121(1):48-56.
 56. Chauhan BC, Mikelberg FS, Balaszi AG, et al. Canadian Glaucoma Study: 2. risk factors for the progression of open-angle glaucoma. *Arch Ophthalmol* 2008;126(8):1030-6.
 57. Van der Valk R, Webers CA, Schouten JS, et al. Intraocular pressure-lowering effects of all commonly used glaucoma drugs: a meta-analysis of randomized clinical trials. *Ophthalmology* 2005;112(7):1177-85.
 58. Heijl A, Leske MC, Hyman L, et al. Intraocular pressure reduction with a fixed treatment protocol in the Early Manifest Glaucoma Trial. *Acta Ophthalmol* 2011;89(8):749-54.
 59. Olthoff CM, Schouten JS, van de Borne BW, Webers CA. Noncompliance with ocular hypotensive treatment in patients with glaucoma or ocular hypertension an evidence-

- based review. *Ophthalmology* 2005;112(6):953-61.
60. Patel SC, Spaeth GL. Compliance in patients prescribed eyedrops for glaucoma. *Ophthalmic Surg* 1995;26(3):233-6.
 61. Chrai SS, Makoid MC, Eriksen SP, Robinson JR. Drop size and initial dosing frequency problems of topically applied ophthalmic drugs. *J Pharm Sci* 1974;63(3):333-8.
 62. Serle JB, Toor A, Fahim MM, et al. The Effect of Varying Dosing Interval on the Efficacy of Intraocular Pressure Lowering Drugs. *Invest Ophthalmol Vis Sci* 2004;45(5):971-.
 63. Pisella PJ, Pouliquen P, Baudouin C. Prevalence of ocular symptoms and signs with preserved and preservative free glaucoma medication. *Br J Ophthalmol* 2002;86(4):418-23.
 64. Jaenen N, Baudouin C, Pouliquen P, et al. Ocular symptoms and signs with preserved and preservative-free glaucoma medications. *Eur J Ophthalmol* 2007;17(3):341-9.
 65. Aptel F, Cucherat M, Denis P. Efficacy and tolerability of prostaglandin-timolol fixed combinations: a meta-analysis of randomized clinical trials. *Eur J Ophthalmol* 2012;22(1):5-18.
 66. Cox JA, Mollan SP, Bankart J, Robinson R. Efficacy of antiglaucoma fixed combination therapy versus unfix components in reducing intraocular pressure: a systematic review. *Br J Ophthalmol* 2008;92(6):729-34.
 67. Shoji T, Sato H, Mizukawa A, et al. Hypotensive effect of latanoprost/timolol versus travoprost/timolol fixed combinations in NTG patients: a randomized, multicenter, crossover clinical trial. *Invest Ophthalmol Vis Sci* 2013;54(9):6242-7.
 68. Alm A, Stjernschantz J. Effects on intraocular pressure and side effects of 0.005% latanoprost applied once daily, evening or morning. A comparison with timolol. Scandinavian Latanoprost Study Group. *Ophthalmology* 1995;102(12):1743-52.
 69. Konstas AG, Nakos E, Tersis I, et al. A comparison of once-daily morning vs evening dosing of concomitant latanoprost/timolol. *Am J Ophthalmol* 2002;133(6):753-7.
 70. Konstas AG, Maltezos AC, Gandi S, et al. Comparison of 24-hour intraocular pressure reduction with two dosing regimens of latanoprost and timolol maleate in patients with primary open-angle glaucoma. *Am J Ophthalmol* 1999;128(1):15-20.
 71. Stewart WC, Konstas AG, Kruff B, et al. Meta-analysis of 24-h intraocular pressure fluctuation studies and the efficacy of glaucoma medicines. *J Ocul Pharmacol Ther* 2010;26(2):175-80.
 72. Aptel F, Cucherat M, Denis P. Efficacy and tolerability of prostaglandin analogs: a meta-analysis of randomized controlled clinical trials. *J Glaucoma* 2008;17(8):667-73.
 73. Ikeda Y, Mori K, Ishibashi T, et al. Latanoprost nonresponders with open-angle glaucoma in the Japanese population. *Jpn J Ophthalmol* 2006;50(2):153-7.
 74. Rossetti L, Gandolfi S, Traverso C, et al. An evaluation of the rate of nonresponders to latanoprost therapy. *J Glaucoma* 2006;15(3):238-43.
 75. Gandolfi SA, Cimino L. Effect of bimatoprost on patients with primary open-angle glaucoma or ocular hypertension who are nonresponders to latanoprost. *Ophthalmology* 2003;110(3):609-14.
 76. Williams RD. Efficacy of bimatoprost in glaucoma and ocular hypertension unresponsive to latanoprost. *Adv Ther* 2002;19(6):275-81.
 77. Baudouin C, Labbe A, Liang H, et al. Preservatives in eyedrops: the good, the bad and the ugly. *Prog Retin Eye Res* 2010;29(4):312-34.
 78. Erb C, Gast U, Schremmer D. German register for glaucoma patients with dry eye. I. Basic outcome with respect to dry eye. *Graefes Arch Clin Exp Ophthalmol* 2008;246(11):1593-601.
 79. Fechtner RD, Godfrey DG, Budenz D, et al. Prevalence of ocular surface complaints in patients with glaucoma using topical intraocular pressure-lowering medications. *Cornea* 2010;29(6):618-21.

80. Ishibashi T, Yokoi N, Kinoshita S. Comparison of the short-term effects on the human corneal surface of topical timolol maleate with and without benzalkonium chloride. *J Glaucoma* 2003;12(6):486-90.
81. Kahook MY, Noecker R. Quantitative analysis of conjunctival goblet cells after chronic application of topical drops. *Adv Ther* 2008;25(8):743-51.
82. Martone G, Frezzotti P, Tosi GM, et al. An in vivo confocal microscopy analysis of effects of topical antiglaucoma therapy with preservative on corneal innervation and morphology. *Am J Ophthalmol* 2009;147(4):725-35 e1.
83. Thieme H, van der Velden KK. [Preservatives from the perspective of glaucoma surgery]. *Ophthalmologe* 2012;109(11):1073-6.
84. Batra R, Tailor R, Mohamed S. Ocular Surface Disease Exacerbated Glaucoma: Optimizing the Ocular Surface Improves Intraocular Pressure Control. *J Glaucoma* 2012.
85. Boimer C, Birt CM. Preservative Exposure and Surgical Outcomes in Glaucoma Patients: The PESO Study. *J Glaucoma* 2013.
86. Ammar DA, Kahook MY. Effects of glaucoma medications and preservatives on cultured human trabecular meshwork and non-pigmented ciliary epithelial cell lines. *Br J Ophthalmol* 2011;95(10):1466-9.
87. Ammar DA, Noecker RJ, Kahook MY. Effects of benzalkonium chloride-preserved, polyquad-preserved, and sofZia-preserved topical glaucoma medications on human ocular epithelial cells. *Adv Ther* 2010;27(11):837-45.
88. Ammar DA, Noecker RJ, Kahook MY. Effects of benzalkonium chloride- and polyquad-preserved combination glaucoma medications on cultured human ocular surface cells. *Adv Ther* 2011;28(6):501-10.
89. Brignole-Baudouin F, Riancho L, Liang H, et al. In vitro comparative toxicology of polyquad-preserved and benzalkonium chloride-preserved travoprost/timolol fixed combination and latanoprost/timolol fixed combination. *J Ocul Pharmacol Ther* 2011;27(3):273-80.
90. Xu M, Sivak JG, McCanna DJ. Comparison of the effects of ophthalmic solutions on human corneal epithelial cells using fluorescent dyes. *J Ocul Pharmacol Ther* 2013;29(9):794-802.
91. Noecker R. Effects of common ophthalmic preservatives on ocular health. *Adv Ther* 2001;18(5):205-15.
92. EMEA public statement on antimicrobial preservatives in ophthalmic preparations for human use. In: EMEA, ed. EMEA/622721/2009. London 2009.
93. Allaire C, Dietrich A, Allmeier H, et al. Latanoprost 0.005% test formulation is as effective as Xalatan(R) in patients with ocular hypertension and primary open-angle glaucoma. *Eur J Ophthalmol* 2012;22(1):19-27.
94. Narayanaswamy A, Neog A, Baskaran M, et al. A randomized, crossover, open label pilot study to evaluate the efficacy and safety of Xalatan in comparison with generic Latanoprost (Latanoprost) in subjects with primary open angle glaucoma or ocular hypertension. *Indian J Ophthalmol* 2007;55(2):127-31.
95. Lu D, Hong L, Xu X, et al. Chemical Analysis of Branded Latanoprost 0.005% Compared With Commercially Available Latanoprost Formulations. *ARVO Meeting Abstracts* 2010;51(5):3162.
96. Brian S, Jayat C, Desmis A, Garrigue J-S. Pharmaceutical Evaluation Of The Quality And Delivered Dose Of US Latanoprost Generics. *ARVO Meeting Abstracts* 2012;53(6):5103.
97. Joag M, Thirumurthy V, Jha B, et al. Comparative Evaluation of Physical Properties of 3 Commercially available Generic Brands of Latanoprost with Xalatan. *ARVO Meeting Abstracts* 2012;53(6):5096.

98. Mammo ZN, Flanagan JG, James DF, Trope GE. Generic versus brand-name North American topical glaucoma drops. *Can J Ophthalmol* 2012;47(1):55-61.
99. Takada Y, Okada Y, Fujita N, Saika S. A patient with corneal epithelial disorder that developed after administration of a latanoprost generic, but not a brand-name drug, eye drop. *Case Rep Ophthalmol Med* 2012;2012:536746.
100. Wan MJ, Daniel S, Kassam F, et al. Survey of complementary and alternative medicine use in glaucoma patients. *J Glaucoma* 2012;21(2):79-82.
101. Pasquale LR, Kang JH. Lifestyle, nutrition, and glaucoma. *J Glaucoma* 2009;18(6):423-8.
102. Nguyen CT, Bui BV, Sinclair AJ, Vingrys AJ. Dietary omega 3 fatty acids decrease intraocular pressure with age by increasing aqueous outflow. *Invest Ophthalmol Vis Sci* 2007;48(2):756-62.
103. Giaconci JA, Yu F, Stone KL, et al. The association of consumption of fruits/vegetables with decreased risk of glaucoma among older African-American women in the study of osteoporotic fractures. *Am J Ophthalmol* 2012;154(4):635-44.
104. Renard JP, Rouland JF, Bron A, et al. Nutritional, lifestyle and environmental factors in ocular hypertension and primary open-angle glaucoma: an exploratory case-control study. *Acta Ophthalmol* 2013;91(6):505-13.
105. Ramdas WD, Wolfs RC, Kiefte-de Jong JC, et al. Nutrient intake and risk of open-angle glaucoma: the Rotterdam Study. *Eur J Epidemiol* 2012;27(5):385-93.
106. Phillips CI, Gore SM. Ocular hypotensive effect of late pregnancy with and without high blood pressure. *Br J Ophthalmol* 1985;69(2):117-9.
107. Sunness JS. The pregnant woman's eye. *Surv Ophthalmol* 1988;32(4):219-38.
108. Qureshi IA, Xi XR, Wu XD. Intraocular pressure trends in pregnancy and in the third trimester hypertensive patients. *Acta Obstet Gynecol Scand* 1996;75(9):816-9.
109. Urtti A, Salminen L. Minimizing systemic absorption of topically administered ophthalmic drugs. *Surv Ophthalmol* 1993;37(6):435-56.
110. FDA classification of drugs for teratogenic risk. Teratology Society Public Affairs Committee. *Teratology* 1994;49(6):446-7.
111. Al-Shahwan S, Al-Torbak AA, Turkmani S, et al. Side-effect profile of brimonidine tartrate in children. *Ophthalmology* 2005;112(12):2143.
112. Razeghinejad MR, Tania Tai TY, Fudenberg SJ, Katz LJ. Pregnancy and glaucoma. *Surv Ophthalmol* 2011;56(4):324-35.
113. Park MH, Moon J-I. Selective Laser Trabeculoplasty in Fertile Women with Open Angle Glaucoma or Ocular Hypertension. *J Korean Ophthalmol Soc* 2007;48(11):1494-9.
114. Safran MJ, Robin AL, Pollack IP. Argon laser trabeculoplasty in younger patients with primary open-angle glaucoma. *Am J Ophthalmol* 1984;97(3):292-5.
115. Wertheim M, Broadway DC. Cyclodiode laser therapy to control intraocular pressure during pregnancy. *Br J Ophthalmol* 2002;86(11):1318-9.
116. Rosen MA. Management of anesthesia for the pregnant surgical patient. *Anesthesiology* 1999;91(4):1159-63.
117. Johnson SM, Martinez M, Freedman S. Management of glaucoma in pregnancy and lactation. *Surv Ophthalmol* 2001;45(5):449-54.
118. Schaefer C PP, Miller RK. *Drugs During Pregnancy and Lactation*. The Netherlands: Elsevier Science, 2001.
119. Transfer of drugs and other chemicals into human milk. *Pediatrics* 2001;108(3):776-89.
120. Baltmr A, Duggan J, Nizari S, et al. Neuroprotection in glaucoma - Is there a future role? *Exp Eye Res* 2010;91(5):554-66.

121. Cordeiro MF, Levin LA. Clinical evidence for neuroprotection in glaucoma. *Am J Ophthalmol* 2011;152(5):715-6.
122. Sena DF, Lindsley K. Neuroprotection for treatment of glaucoma in adults. *Cochrane Database Syst Rev* 2013;2:CD006539.
123. Maurice DM, Mishima, S. Ocular pharmacokinetics. In: Sears ML, ed. *Pharmacology of the eye*. Berlin: Springer-Verlag, 1984.
124. Linden C, Alm A. The effect of reduced tear drainage on corneal and aqueous concentrations of topically applied fluorescein. *Acta Ophthalmol (Copenh)* 1990;68(6):633-8.
125. Korte JM, Kaila T, Saari KM. Systemic bioavailability and cardiopulmonary effects of 0.5% timolol eyedrops. *Graefes Arch Clin Exp Ophthalmol* 2002;240(6):430-5.
126. Maul EA, Friedman DS, Quigley HA, Jampel HD. Impact of eyelid closure on the intraocular pressure lowering effect of prostaglandins: a randomised controlled trial. *Br J Ophthalmol* 2012;96(2):250-3.
127. Zimmerman TJ, Baumann JD, Hetherington J, Jr. Side effects of timolol. *Surv Ophthalmol* 1983;28 Suppl:243-51.
128. Zimmerman TJ, Kooner KS, Kandarakis AS, Ziegler LP. Improving the therapeutic index of topically applied ocular drugs. *Arch Ophthalmol* 1984;102(4):551-3.
129. Cramer JA. Effect of partial compliance on cardiovascular medication effectiveness. *Heart* 2002;88(2):203-6.
130. Schwartz GF, Quigley HA. Adherence and persistence with glaucoma therapy. *Surv Ophthalmol* 2008;53 Suppl1:S57-68.
131. Blackwell B. From compliance to alliance. A quarter century of research. *Neth J Med* 1996;48(4):140-9.
132. Quigley HA, Friedman DS, Hahn SR. Evaluation of practice patterns for the care of open-angle glaucoma compared with claims data: the Glaucoma Adherence and Persistence Study. *Ophthalmology* 2007;114(9):1599-606.
133. Tsai JC, McClure CA, Ramos SE, et al. Compliance barriers in glaucoma: a systematic classification. *J Glaucoma* 2003;12(5):393-8.
134. Ashburn FS, Jr., Goldberg I, Kass MA. Compliance with ocular therapy. *Surv Ophthalmol* 1980;24(4):237-48.
135. Zimmerman TJ, Zalta AH. Facilitating patient compliance in glaucoma therapy. *Surv Ophthalmol* 1983;28 Suppl:252-8.
136. Ritch RLL, J.M.. Laser iridotomy and peripheral iridoplasty. In: (eds.) K, ed. In: Ritch R, Shields MB, *The Glaucomas*. St. Louis: Mosby, 1996.
137. He M, Friedman DS, Ge J, et al. Laser peripheral iridotomy in primary angle-closure suspects: biometric and gonioscopic outcomes: the Liwan Eye Study. *Ophthalmology* 2007;114(3):494-500.
138. He M, Friedman DS, Ge J, et al. Laser peripheral iridotomy in eyes with narrow drainage angles: ultrasound biomicroscopy outcomes. The Liwan Eye Study. *Ophthalmology* 2007;114(8):1513-9.
139. Fleck BW. How large must an iridotomy be? *Br J Ophthalmol* 1990;74(10):583-8.
140. Wise JB. Low-energy linear-incision neodymium: YAG laser iridotomy versus linear-incision argon laser iridotomy. A prospective clinical investigation. *Ophthalmology* 1987;94(12):1531-7.
141. de Silva DJ, Gazzard G, Foster P. Laser iridotomy in dark irides. *Br J Ophthalmol* 2007;91(2):222-5.

142. Spaeth GL, Idowu O, Seligsohn A, et al. The effects of iridotomy size and position on symptoms following laser peripheral iridotomy. *J Glaucoma* 2005;14(5):364-7.
143. Congdon N, Yan X, Friedman DS, et al. Visual symptoms and retinal straylight after laser peripheral iridotomy: the Zhongshan Angle-Closure Prevention Trial. *Ophthalmology* 2012;119(7):1375-82.
144. Jiang Y, Chang DS, Foster PJ, et al. Immediate changes in intraocular pressure after laser peripheral iridotomy in primary angle-closure suspects. *Ophthalmology* 2012;119(2):283-8.
145. Landers J, Craig J. Decompression retinopathy and corneal oedema following Nd:YAG laser peripheral iridotomy. *Clin Experiment Ophthalmol* 2006;34(2):182-4.
146. Aminlari A, Sassani JW. Simultaneous bilateral malignant glaucoma following laser iridotomy. *Graefes Arch Clin Exp Ophthalmol* 1993;231(1):12-4.
147. Weinreb RNT, C.S.. Laser trabeculoplasty. In: (eds.) KT, ed. In: Ritch R, Shields MB: *The Glaucomas*. St. Louis: Mosby 1996.
148. Migdal C, Gregory W, Hitchings R. Long-term functional outcome after early surgery compared with laser and medicine in open-angle glaucoma. *Ophthalmology* 1994;101(10):1651-6; discussion 7.
149. The Glaucoma Laser Trial (GLT). 2. Results of argon laser trabeculoplasty versus topical medicines. The Glaucoma Laser Trial Research Group. *Ophthalmology* 1990;97(11):1403-13.
150. The Advanced Glaucoma Intervention Study (AGIS): 4. Comparison of treatment outcomes within race. Seven-year results. *Ophthalmology* 1998;105(7):1146-64.
151. The Advanced Glaucoma Intervention Study (AGIS): 9. Comparison of glaucoma outcomes in black and white patients within treatment groups. *Am J Ophthalmol* 2001;132(3):311-20.
152. Rolim de Moura C, Paranhos A, Jr., Wormald R. Laser trabeculoplasty for open angle glaucoma. *Cochrane Database Syst Rev* 2007(4):CD003919.
153. Samples JR, Singh K, Lin SC, et al. Laser trabeculoplasty for open-angle glaucoma: a report by the american academy of ophthalmology. *Ophthalmology* 2011;118(11):2296-302.
154. Latina MA, Sibayan SA, Shin DH, et al. Q-switched 532-nm Nd:YAG laser trabeculoplasty (selective laser trabeculoplasty): a multicenter, pilot, clinical study. *Ophthalmology* 1998;105(11):2082-8; discussion 9-90.
155. The Glaucoma Laser Trial. I. Acute effects of argon laser trabeculoplasty on intraocular pressure. Glaucoma Laser Trial Research Group. *Arch Ophthalmol* 1989;107(8):1135-42.
156. Realini T. Selective laser trabeculoplasty for the management of open-angle glaucoma in St. Lucia. *JAMA Ophthalmol* 2013;131(3):321-7.
157. Ong K, Ong L. Selective laser trabeculoplasty may compromise corneas with pigment on endothelium. *Clin Experiment Ophthalmol* 2013;41(1):109-10; question and answer 11-2.
158. Damji KF, Bovell AM, Hodge WG, et al. Selective laser trabeculoplasty versus argon laser trabeculoplasty: results from a 1-year randomised clinical trial. *Br J Ophthalmol* 2006;90(12):1490-4.
159. Bovell AM, Damji KF, Hodge WG, et al. Long term effects on the lowering of intraocular pressure: selective laser or argon laser trabeculoplasty? *Can J Ophthalmol* 2011;46(5):408-13.
160. The Glaucoma Laser Trial (GLT) and glaucoma laser trial follow-up study: 7. Results. Glaucoma Laser Trial Research Group. *Am J Ophthalmol* 1995;120(6):718-31.
161. Katz LJ, Steinmann WC, Kabir A, et al. Selective laser trabeculoplasty versus medical therapy as initial treatment of glaucoma: a prospective, randomized trial. *J Glaucoma* 2012;21(7):460-8.
162. Tzimis V, Tze L, Ganesh J, et al. Laser trabeculoplasty: an investigation into factors that might influence outcomes. *Can J Ophthalmol* 2011;46(4):305-9.

163. Heijl A, Peters D, Leske MC, Bengtsson B. Effects of argon laser trabeculoplasty in the Early Manifest Glaucoma Trial. *Am J Ophthalmol* 2011;152(5):842-8.
164. Elsas T, Johnsen H. Long-term efficacy of primary laser trabeculoplasty. *Br J Ophthalmol* 1991;75(1):34-7.
165. The Advanced Glaucoma Intervention Study (AGIS): 11. Risk factors for failure of trabeculectomy and argon laser trabeculoplasty. *Am J Ophthalmol* 2002;134(4):481-98.
166. Ritch R, Tham CC, Lam DS. Argon laser peripheral iridoplasty (ALPI): an update. *Surv Ophthalmol* 2007;52(3):279-88.
167. Ng WS, Ang GS, Azuara-Blanco A. Laser peripheral iridoplasty for angle-closure. *Cochrane Database Syst Rev* 2012;2:CD006746.
168. Bloom PA, Tsai JC, Sharma K, et al. "Cyclodiode". Trans-scleral diode laser cyclophotocoagulation in the treatment of advanced refractory glaucoma. *Ophthalmology* 1997;104(9):1508-19; discussion 19-20.
169. Ishida K. Update on results and complications of cyclophotocoagulation. *Curr Opin Ophthalmol* 2013;24(2):102-10.
170. Lin SC. Endoscopic and transscleral cyclophotocoagulation for the treatment of refractory glaucoma. *J Glaucoma* 2008;17(3):238-47.
171. Aptel F, Charrel T, Lafon C, et al. Miniaturized high-intensity focused ultrasound device in patients with glaucoma: a clinical pilot study. *Invest Ophthalmol Vis Sci* 2011;52(12):8747-53.
172. Aptel F, Charrel T, Palazzi X, et al. Histologic effects of a new device for high-intensity focused ultrasound cyclocoagulation. *Invest Ophthalmol Vis Sci* 2010;51(10):5092-8.
173. Agrawal P, Martin KR. Ciliary body position variability in glaucoma patients assessed by scleral transillumination. *Eye (Lond)* 2008;22(12):1499-503.
174. Kosoko O, Gaasterland DE, Pollack IP, Enger CL. Long-term outcome of initial ciliary ablation with contact diode laser transscleral cyclophotocoagulation for severe glaucoma. The Diode Laser Ciliary Ablation Study Group. *Ophthalmology* 1996;103(8):1294-302.
175. Clement CI, Kampougeris G, Ahmed F, et al. Combining phacoemulsification with endoscopic cyclophotocoagulation to manage cataract and glaucoma. *Clin Experiment Ophthalmol* 2013;41(6):546-51.
176. Ramli N, Htoon HM, Ho CL, et al. Risk factors for hypotony after transscleral diode cyclophotocoagulation. *J Glaucoma* 2012;21(3):169-73.
177. Mattox C, Tsai JC. American Glaucoma Society position statement: glaucoma surgery by surgeons. *J Glaucoma* 2013;22(6):515.
178. Landers J, Martin K, Sarkies N, et al. A twenty-year follow-up study of trabeculectomy: risk factors and outcomes. *Ophthalmology* 2012;119(4):694-702.
179. Cairns JE. Trabeculectomy. Preliminary report of a new method. *Am J Ophthalmol* 1968;66(4):673-9.
180. Khaw PT, Chiang M, Shah P, et al. Enhanced trabeculectomy: the Moorfields Safer Surgery System. *Dev Ophthalmol* 2012;50:1-28.
181. Solus JF, Jampel HD, Tracey PA, et al. Comparison of limbus-based and fornix-based trabeculectomy: success, bleb-related complications, and bleb morphology. *Ophthalmology* 2012;119(4):703-11.
182. Salim S. Current variations of glaucoma filtration surgery. *Curr Opin Ophthalmol* 2012;23(2):89-95.
183. Francis BA, Singh K, Lin SC, et al. Novel glaucoma procedures: a report by the American Academy of Ophthalmology. *Ophthalmology* 2011;118(7):1466-80.

184. Rotchford AP, King AJ. Moving the goal posts definitions of success after glaucoma surgery and their effect on reported outcome. *Ophthalmology* 2010;117(1):18-23 e3.
185. Mosaed S, Dustin L, Minckler DS. Comparative outcomes between newer and older surgeries for glaucoma. *Trans Am Ophthalmol Soc* 2009;107:127-33.
186. Kobayashi H, Kobayashi K. Randomized comparison of the intraocular pressure-lowering effect of phacoviscocanalostomy and phacotrabeculectomy. *Ophthalmology* 2007;114(5):909-14.
187. Chang L, Thiagarajan M, Moseley M, et al. Intraocular pressure outcome in primary 5FU phacotrabeculectomies compared with 5FU trabeculectomies. *J Glaucoma* 2006;15(6):475-81.
188. Fontana H, Nouri-Mahdavi K, Lumba J, et al. Trabeculectomy with mitomycin C: outcomes and risk factors for failure in phakic open-angle glaucoma. *Ophthalmology* 2006;113(6):930-6.
189. Stalmans I, Gillis A, Lafaut AS, Zeyen T. Safe trabeculectomy technique: long term outcome. *Br J Ophthalmol* 2006;90(1):44-7.
190. Joshi AB, Parrish RK, 2nd, Feuer WF. 2002 survey of the American Glaucoma Society: practice preferences for glaucoma surgery and antifibrotic use. *J Glaucoma* 2005;14(2):172-4.
191. Broadway DC, Bloom PA, Bunce C, et al. Needle revision of failing and failed trabeculectomy blebs with adjunctive 5-fluorouracil: survival analysis. *Ophthalmology* 2004;111(4):665-73.
192. Marquardt D, Lieb WE, Grehn F. Intensified postoperative care versus conventional follow-up: a retrospective long-term analysis of 177 trabeculectomies. *Graefes Arch Clin Exp Ophthalmol* 2004;242(2):106-13.
193. de Jong L, Lafuma A, Aguade AS, Berdeaux G. Five-year extension of a clinical trial comparing the EX-PRESS glaucoma filtration device and trabeculectomy in primary open-angle glaucoma. *Clin Ophthalmol* 2011;5:527-33.
194. de Jong LA. The Ex-PRESS glaucoma shunt versus trabeculectomy in open-angle glaucoma: a prospective randomized study. *Adv Ther* 2009;26(3):336-45.
195. Maris PJ, Jr., Ishida K, Netland PA. Comparison of trabeculectomy with Ex-PRESS miniature glaucoma device implanted under scleral flap. *J Glaucoma* 2007;16(1):14-9.
196. De Feo F, Bagnis A, Bricola G, et al. Efficacy and safety of a steel drainage device implanted under a scleral flap. *Can J Ophthalmol* 2009;44(4):457-62.
197. Palanca-Capistrano AM, Hall J, Cantor LB, et al. Long-term outcomes of intraoperative 5-fluorouracil versus intraoperative mitomycin C in primary trabeculectomy surgery. *Ophthalmology* 2009;116(2):185-90.
198. Reibaldi A, Uva MG, Longo A. Nine-year follow-up of trabeculectomy with or without low-dosage mitomycin-c in primary open-angle glaucoma. *Br J Ophthalmol* 2008;92(12):1666-70.
199. Salim S. The role of the Ex-PRESS glaucoma filtration device in glaucoma surgery. *Semin Ophthalmol* 2013;28(3):180-4.
200. Buys YM. Trabeculectomy with ExPRESS: weighing the benefits and cost. *Curr Opin Ophthalmol* 2013;24(2):111-8.
201. Saheb H, Ahmed, II. Micro-invasive glaucoma surgery: current perspectives and future directions. *Curr Opin Ophthalmol* 2012;23(2):96-104.
202. Razeghinejad MR, Fudemberg SJ, Spaeth GL. The changing conceptual basis of trabeculectomy: a review of past and current surgical techniques. *Surv Ophthalmol* 2012;57(1):1-25.
203. Carassa RG. Surgical alternative to trabeculectomy. *Prog Brain Res* 2008;173:255-61.
204. Zhou J, Smedley GT. Trabecular bypass: effect of schlemm canal and collector channel

- dilation. *J Glaucoma* 2006;15(5):446-55.
205. Traverso CE, De Feo F, Messas-Kaplan A, et al. Long term effect on IOP of a stainless steel glaucoma drainage implant (Ex-PRESS) in combined surgery with phacoemulsification. *Br J Ophthalmol* 2005;89(4):425-9.
 206. Boland MV, Ervin AM, Friedman D, et al. Treatment for Glaucoma: Comparative Effectiveness. Rockville (MD)2012.
 207. Burr J, Azuara-Blanco A, Avenell A, Tuulonen A. Medical versus surgical interventions for open angle glaucoma. *Cochrane Database Syst Rev* 2012;9:CD004399.
 208. Musch DC, Gillespie BW, Lichter PR, et al. Visual field progression in the Collaborative Initial Glaucoma Treatment Study the impact of treatment and other baseline factors. *Ophthalmology* 2009;116(2):200-7.
 209. Patel HY, Danesh-Meyer HV. Incidence and management of cataract after glaucoma surgery. *Curr Opin Ophthalmol* 2013;24(1):15-20.
 210. Mathew RG, Murdoch IE. The silent enemy: a review of cataract in relation to glaucoma and trabeculectomy surgery. *Br J Ophthalmol* 2011;95(10):1350-4.
 211. Ang GS, Varga Z, Shaarawy T. Postoperative infection in penetrating versus non-penetrating glaucoma surgery. *Br J Ophthalmol* 2010;94(12):1571-6.
 212. Jalil A, Au L, Khan I, et al. Combined trabeculotomy-trabeculectomy augmented with 5-fluorouracil in paediatric glaucoma. *Clin Experiment Ophthalmol* 2011;39(3):207-14.
 213. Yalvac IS, Satana B, Suveren A, et al. Success of trabeculotomy in patients with congenital glaucoma operated on within 3 months of birth. *Eye (Lond)* 2007;21(4):459-64.
 214. Khan AO. Trabeculotomy versus trabeculotomy-trabeculectomy for congenital glaucoma. *Br J Ophthalmol* 2006;90(1):125.
 215. Bothun ED, Guo Y, Christiansen SP, et al. Outcome of angle surgery in children with aphakic glaucoma. *J AAPOS* 2010;14(3):235-9.
 216. Maeda M, Watanabe M, Ichikawa K. Evaluation of trabectome in open-angle glaucoma. *J Glaucoma* 2013;22(3):205-8.
 217. Vold SD. Ab interno trabeculotomy with the trabectome system: what does the data tell us? *Int Ophthalmol Clin* 2011;51(3):65-81.
 218. Roy S, Mermoud A. Deep sclerectomy. *Dev Ophthalmol* 2012;50:29-36.
 219. Cheng JW, Cheng SW, Cai JP, et al. Systematic overview of the efficacy of nonpenetrating glaucoma surgery in the treatment of open angle glaucoma. *Med Sci Monit* 2011;17(7):RA155-63.
 220. Rekas M, Lewczuk K, Fuksinska B, et al. Combined surgery for cataract and glaucoma: PDS with absorbable SK-gel implant compared with PDS with non-absorbable T-flux implant - medium-term results. *Curr Med Res Opin* 2010;26(5):1131-7.
 221. Guedes RA, Guedes VM, Chaoubah A. Does phacoemulsification affect the long-term success of non-penetrating deep sclerectomy? *Ophthalmic Surg Lasers Imaging* 2010;41(2):228-35.
 222. Hondur A, Onol M, Hasanreisoglu B. Nonpenetrating glaucoma surgery: meta-analysis of recent results. *J Glaucoma* 2008;17(2):139-46.
 223. Wiermann A, Zeitz O, Jochim E, et al. [A comparison between absorbable and non-resorbable scleral implants in deep sclerectomy (T-Flux and SK-Gel)]. *Ophthalmologie* 2007;104(5):409-14.
 224. Khairy HA, Green FD, Nassar MK, Azuara-Blanco A. Control of intraocular pressure after deep sclerectomy. *Eye (Lond)* 2006;20(3):336-40.
 225. Chiselita D. Non-penetrating deep sclerectomy versus trabeculectomy in primary open-angle glaucoma surgery. *Eye (Lond)* 2001;15(Pt 2):197-201.
 226. Tan JC, Hitchings RA. Non-penetrating glaucoma surgery: the state of play. *Br J Ophthalmol* 2001;85(2):234-7.

227. Netland PA. Nonpenetrating glaucoma surgery. *Ophthalmology* 2001;108(2):416-21.
228. Johnson DH, Johnson M. How does nonpenetrating glaucoma surgery work? Aqueous outflow resistance and glaucoma surgery. *J Glaucoma* 2001;10(1):55-67.
229. Grieshaber MC. Ab externo Schlemm's canal surgery: viscocanalostomy and canaloplasty. *Dev Ophthalmol* 2012;50:109-24.
230. Jonescu-Cuypers C, Jacobi P, Konen W, Kriegelstein G. Primary viscocanalostomy versus trabeculectomy in white patients with open-angle glaucoma: A randomized clinical trial. *Ophthalmology* 2001;108(2):254-8.
231. Gilmour DF, Manners TD, Devonport H, et al. Viscocanalostomy versus trabeculectomy for primary open angle glaucoma: 4-year prospective randomized clinical trial. *Eye (Lond)* 2009;23(9):1802-7.
232. Yalvac IS, Sahin M, Eksioglu U, et al. Primary viscocanalostomy versus trabeculectomy for primary open-angle glaucoma: three-year prospective randomized clinical trial. *J Cataract Refract Surg* 2004;30(10):2050-7.
233. O'Brart DP, Shiew M, Edmunds B. A randomised, prospective study comparing trabeculectomy with viscocanalostomy with adjunctive antimetabolite usage for the management of open angle glaucoma uncontrolled by medical therapy. *Br J Ophthalmol* 2004;88(8):1012-7.
234. Carassa RG, Bettin P, Fiori M, Brancato R. Viscocanalostomy versus trabeculectomy in white adults affected by open-angle glaucoma: a 2-year randomized, controlled trial. *Ophthalmology* 2003;110(5):882-7.
235. Mastropasqua L, Agnifili L, Salvetat ML, et al. In vivo analysis of conjunctiva in canaloplasty for glaucoma. *Br J Ophthalmol* 2012;96(5):634-9.
236. Lewis RA, von Wolff K, Tetz M, et al. Canaloplasty: Three-year results of circumferential viscodilation and tensioning of Schlemm canal using a microcatheter to treat open-angle glaucoma. *J Cataract Refract Surg* 2011;37(4):682-90.
237. Grieshaber MC, Pienaar A, Olivier J, Stegmann R. Comparing two tensioning suture sizes for 360 degrees viscocanalostomy (canaloplasty): a randomised controlled trial. *Eye (Lond)* 2010;24(7):1220-6.
238. Grieshaber MC, Pienaar A, Olivier J, Stegmann R. Clinical evaluation of the aqueous outflow system in primary open-angle glaucoma for canaloplasty. *Invest Ophthalmol Vis Sci* 2010;51(3):1498-504.
239. Bull H, von Wolff K, Korber N, Tetz M. Three-year canaloplasty outcomes for the treatment of open-angle glaucoma: European study results. *Graefes Arch Clin Exp Ophthalmol* 2011;249(10):1537-45.
240. Matthaei M, Steinberg J, Wiermann A, et al. [Canaloplasty : a new alternative in non-penetrating glaucoma surgery]. *Ophthalmologe* 2011;108(7):637-43.
241. Grieshaber MC, Fraenkl S, Schoetzau A, et al. Circumferential viscocanalostomy and suture canal distension (canaloplasty) for whites with open-angle glaucoma. *J Glaucoma* 2011;20(5):298-302.
242. Grieshaber MC, Pienaar A, Olivier J, Stegmann R. Canaloplasty for primary open-angle glaucoma: long-term outcome. *Br J Ophthalmol* 2010;94(11):1478-82.
243. Seibold LK, Sherwood MB, Kahook MY. Wound modulation after filtration surgery. *Surv Ophthalmol* 2012;57(6):530-50.
244. Skuta GL. Antifibrotic agents in glaucoma filtering surgery. *Int Ophthalmol Clin* 1993;33(4):165-82.
245. Fontana H, Nouri-Mahdavi K, Caprioli J. Trabeculectomy with mitomycin C in pseudophakic

- patients with open-angle glaucoma: outcomes and risk factors for failure. *Am J Ophthalmol* 2006;141(4):652-9.
246. Chan KC, Ang GS, Birchall W, et al. Prospective study of surgical outcomes and bleb morphology using indocyanine green as a surgical dye in trabeculectomy with mitomycin C. *Clin Experiment Ophthalmol* 2012;40(4):e143-8.
 247. Melo AB, Spaeth GL. A new, safer method of applying antimetabolites during glaucoma filtering surgery. *Ophthalmic Surg Lasers Imaging* 2010;41(3):383-5.
 248. Lockwood A, Brocchini S, Khaw PT. New developments in the pharmacological modulation of wound healing after glaucoma filtration surgery. *Curr Opin Pharmacol* 2013;13(1):65-71.
 249. Hollo G. Wound healing and glaucoma surgery: modulating the scarring process with conventional antimetabolites and new molecules. *Dev Ophthalmol* 2012;50:79-89.
 250. He M, Wang W, Zhang X, Huang W. Ologen implant versus mitomycin C for trabeculectomy: a systematic review and meta-analysis. *PLoS One* 2014;9(1):e85782.
 251. Khaw PTC, J. Antifibrotic agents in glaucoma surgery. In: Yanof M DJ, ed. *Ophthalmology* London: Mosby 2008.
 252. Wells AP, Cordeiro MF, Bunce C, Khaw PT. Cystic bleb formation and related complications in limbus- versus fornix-based conjunctival flaps in pediatric and young adult trabeculectomy with mitomycin C. *Ophthalmology* 2003;110(11):2192-7.
 253. Traverso CE, Facino M, Murialdo U, et al. Decreased corneal complications after no-reflux, low-dose 5 fluorouracil subconjunctival injection following trabeculectomy. *Int Ophthalmol* 1994;18(4):247-50.
 254. Brandao LM, Grieshaber MC. Update on Minimally Invasive Glaucoma Surgery (MIGS) and New Implants. *J Ophthalmol* 2013;2013:705915.
 255. FDA. FDA/AGS Workshop on Supporting Innovation for Safe and Effective Minimally Invasive Glaucoma Surgery. U.S. Food and Drug Administration - Medical Devices, 2014.
 256. Thompson AM, Moltano AC, Bevin TH, Herbison P. Otago glaucoma surgery outcome study: comparative results for the 175-mm² Moltano3 and double-plate moltano implants. *JAMA Ophthalmol* 2013;131(2):155-9.
 257. Valimaki J. Surgical management of glaucoma with Moltano3 implant. *J Glaucoma* 2012;21(1):7-11.
 258. Moltano AC, Bevin TH, Herbison P, Husni MA. Long-term results of primary trabeculectomies and Moltano implants for primary open-angle glaucoma. *Arch Ophthalmol* 2011;129(11):1444-50.
 259. Nassiri N, Kamali G, Rahnvardi M, et al. Ahmed glaucoma valve and single-plate Moltano implants in treatment of refractory glaucoma: a comparative study. *Am J Ophthalmol* 2010;149(6):893-902.
 260. Rossiter-Thornton L, Azar D, Leong J, et al. Graft-free Moltano tube insertion: 10-year outcomes. *Br J Ophthalmol* 2010;94(5):665-6.
 261. Vuori ML. Moltano aqueous shunt as a primary surgical intervention for uveitic glaucoma: long-term results. *Acta Ophthalmol* 2010;88(1):33-6.
 262. Woodcock MG, Richards JC, Murray AD. The last 11 years of Moltano implantation at the University of Cape Town. Refining our indications and surgical technique. *Eye (Lond)* 2008;22(1):18-25.
 263. Deokule SP, Moltano AC, Bevin TH, Herbison P. Long-term results of Moltano implant insertion in cases of chronic angle closure glaucoma. *Clin Experiment Ophthalmol* 2007;35(6):514-9.
 264. Taglia DP, Perkins TW, Gangnon R, et al. Comparison of the Ahmed Glaucoma Valve,

- the Krupin Eye Valve with Disk, and the double-plate Molteno implant. *J Glaucoma* 2002;11(4):347-53.
265. Mastropasqua L, Carpineto P, Ciancaglini M, Zuppari E. Long-term results of Krupin-Denver valve implants in filtering surgery for neovascular glaucoma. *Ophthalmologica* 1996;210(4):203-6.
 266. Fellenbaum PS, Almeida AR, Minckler DS, et al. Krupin disk implantation for complicated glaucomas. *Ophthalmology* 1994;101(7):1178-82.
 267. Poels MM, Niessen AG, de Waard PW, Lemij HG. Surgical outcomes of the Baerveldt Glaucoma Implant: differences between surgical techniques in the Rotterdam Eye Hospital. *J Glaucoma* 2013;22(5):363-8.
 268. Christakis PG, Tsai JC, Kalenak JW, et al. The ahmed versus baerveldt study: three-year treatment outcomes. *Ophthalmology* 2013;120(11):2232-40.
 269. Suhr AW, Lim MC, Brandt JD, et al. Outcomes of fornix-based versus limbus-based conjunctival incisions for glaucoma drainage device implant. *J Glaucoma* 2012;21(8):523-9.
 270. Gedde SJ, Schiffman JC, Feuer WJ, et al. Treatment outcomes in the Tube Versus Trabeculectomy (TVT) study after five years of follow-up. *Am J Ophthalmol* 2012;153(5):789-803 e2.
 271. Gedde SJ, Herndon LW, Brandt JD, et al. Postoperative complications in the Tube Versus Trabeculectomy (TVT) study during five years of follow-up. *Am J Ophthalmol* 2012;153(5):804-14 e1.
 272. Tello C, Espana EM, Mora R, et al. Baerveldt glaucoma implant insertion in the posterior chamber sulcus. *Br J Ophthalmol* 2007;91(6):739-42.
 273. Gedde SJ, Panarelli JF, Banitt MR, Lee RK. Evidenced-based comparison of aqueous shunts. *Curr Opin Ophthalmol* 2013;24(2):87-95.
 274. Maris PJ, Jr., Tsai JC, Khatib N, et al. Clinical outcomes of Ahmed Glaucoma valve in posterior segment versus anterior chamber. *J Glaucoma* 2013;22(3):183-9.
 275. Geffen N, Buys YM, Smith M, et al. Conjunctival Complications Related to Ahmed Glaucoma Valve Insertion. *J Glaucoma* 2012.
 276. Kaya M, Ozbek Z, Yaman A, Durak I. Long-term success of ahmed glaucoma valve in refractory glaucoma. *Int J Ophthalmol* 2012;5(1):108-12.
 277. Shen CC, Salim S, Du H, Netland PA. Trabeculectomy versus Ahmed Glaucoma Valve implantation in neovascular glaucoma. *Clin Ophthalmol* 2011;5:281-6.
 278. Netland PA, Ishida K, Boyle JW. The Ahmed Glaucoma Valve in patients with and without neovascular glaucoma. *J Glaucoma* 2010;19(9):581-6.
 279. Wishart PK, Choudhary A, Wong D. Ahmed glaucoma valves in refractory glaucoma: a 7-year audit. *Br J Ophthalmol* 2010;94(9):1174-9.
 280. Law SK, Coleman AL, Caprioli J. Dynamic tube movement of Ahmed glaucoma valve. *J Glaucoma* 2009;18(8):628-31.
 281. Reinthal EK, Rohrbach JM, Grisanti S. [Glaucoma drainage implants]. *Klin Monbl Augenheilkd* 2010;227(1):49-55.
 282. Lee KS, Sung KR, Na JH, et al. Clinical results of modified anterior chamber tube shunt to an encircling band surgery for uncontrolled intraocular pressure. *J Glaucoma* 2013;22(2):140-4.
 283. Suh MH, Park KH, Kim TW, Kim DM. The efficacy of a modified ACTSEB (anterior chamber tube shunt to an encircling band) procedure. *J Glaucoma* 2007;16(7):622-6.
 284. Spiegel D, Shrader RR, Wilson RP. Anterior chamber tube shunt to an encircling band (Schocket procedure) in the treatment of refractory glaucoma. *Ophthalmic Surg* 1992;23(12):804-7.

285. Gedde SJ, Singh K, Schiffman JC, Feuer WJ. The Tube Versus Trabeculectomy Study: interpretation of results and application to clinical practice. *Curr Opin Ophthalmol* 2012;23(2):118-26.
286. Schmidt W, Kastner C, Sternberg K, et al. New concepts for glaucoma implants--controlled aqueous humor drainage, encapsulation prevention and local drug delivery. *Curr Pharm Biotechnol* 2013;14(1):98-111.
287. Patel S, Pasquale LR. Glaucoma drainage devices: a review of the past, present, and future. *Semin Ophthalmol* 2010;25(5-6):265-70.
288. Kanner EM, Netland PA, Sarkisian SR, Jr., Du H. Ex-PRESS miniature glaucoma device implanted under a scleral flap alone or combined with phacoemulsification cataract surgery. *J Glaucoma* 2009;18(6):488-91.
289. Tzu JH, Shah CT, Galor A, et al. Refractive Outcomes of Combined Cataract and Glaucoma Surgery. *J Glaucoma* 2013.
290. Bilgin G, Karakurt A, Saricaoglu MS. Combined non-penetrating deep sclerectomy with phacoemulsification versus non-penetrating deep sclerectomy alone. *Semin Ophthalmol* 2014;29(3):146-50.
291. Budenz DL, Gedde SJ. New options for combined cataract and glaucoma surgery. *Curr Opin Ophthalmol* 2014;25(2):141-7.
292. Netland PA. Cataract surgery in glaucoma patients: how much benefit? *Am J Ophthalmol* 2014;157(1):1-3.
293. Nguyen DQ, Niyadurupola N, Tapp RJ, et al. Effect of phacoemulsification on trabeculectomy function. *Clin Experiment Ophthalmol* 2013.
294. Vizzeri G, Weinreb RN. Cataract surgery and glaucoma. *Curr Opin Ophthalmol* 2010;21(1):20-4.
295. Slabaugh MA, Chen PP. The effect of cataract extraction on intraocular pressure. *Curr Opin Ophthalmol* 2014;25(2):122-6.
296. Slabaugh MA, Bojikian KD, Moore DB, Chen PP. The effect of phacoemulsification on intraocular pressure in medically controlled open-angle glaucoma patients. *Am J Ophthalmol* 2014;157(1):26-31.
297. Shingleton BJ, Wooler KB, Bourne CI, O'Donoghue MW. Combined cataract and trabeculectomy surgery in eyes with pseudoexfoliation glaucoma. *J Cataract Refract Surg* 2011;37(11):1961-70.
298. Marchini G, Ceruti P, Vizzari G. Management of concomitant cataract and glaucoma. *Dev Ophthalmol* 2012;50:146-56.
299. Liaska A, Papaconstantinou D, Georgalas I, et al. Phaco-Trabeculectomy in Controlled, Advanced, Open-Angle Glaucoma and Cataract: Parallel, Randomized Clinical Study of Efficacy and Safety. *Semin Ophthalmol* 2014.

F

False negative answers · 27, 60
False positive answers · 27, 60, 62
Family history · 13, 14, 80, 82-83, 97, 104
FDT · 27, 59
First Line Drugs · 146, 151
Fixation losses · 27, 60
Fixed Combination therapy · 141, 158
FL · 27, 60
Flicker perimetry · 59
FN · 27, 60
FP · 27, 59-61
Frequency Doubling Technology · 27, 59

G

Gaze tracker · 60
GHT · 27, 61
Glaucoma Hemifield Test · 27, 61
Goal of glaucoma treatment · 12, 132
Goldmann applanation tonometry · 27, 33, 35-36, 38
Goldmann perimetry · 58
Gonioscopy · 14, 39-45, 47, 76, 85-86, 88, 92, 96, 100-101, 106, 112-113, 163-164
Goniotomy · 76, 78, 88, 169
Grey scale · 60
GSS · 27, 61, 64

H

Heidelberg Edge Perimetry · 27, 59
Heidelberg Retina Tomography · 27, 56
HEP · 27, 59
High Pressure Glaucoma · 27, 84
High-pass resolution perimetry · 27, 59
Hodapp Classification · 64
HRP · 27, 59
HRT · 27, 56
Humphrey Field Analyzer · 59
Humphrey Perimeter · 58, 61

I

Icare · 33, 35, 38
Imaging · 47, 55-56, 57
Incisional surgery · 84, 139, 142, 169, 173
Indirect Gonioscopy · 41, 44
Individualized glaucoma treatment · 133

Intermittent Angle-Closure · 28, 85, 88, 105, 110
Intraocular pressure · 11, 17, 19-20, 28, 33-35, 38, 80, 83-84, 101, 103, 110, 134, 145, 158, 167, 173
Intraocular tumour · 95
IOP · 11-19, 28, 33-35, 37, 38, 44, 75-76, 78, 80-96, 98-109, 112-116, 118-119, 132-138, 140-153, 156, 158, 160-161, 163-166, 169-174, 176
Iridocorneal endothelial syndrome · 115
Iridotomy · 28, 44, 92, 100, 102-108, 110-114, 117, 119, 150, 161-163, 166, 169
Iris processes · 40
Iris root · 40, 45, 98
ISNT rule · 48, 52

J

Juvenile Glaucoma · 86, 88

L

Laser Iridoplasty · 103, 108, 110
Laser Iridotomy · 44, 106-107, 110-111, 114, 119, 161-162, 169
Laser Trabeculoplasty · 15, 18, 85-88, 91-92, 97-98, 112, 116, 137, 155, 164-166
Latanoprost · 142, 145-146, 151, 153
Learning effect · 62
Lens-induced open-angle glaucoma · 93
Levobunolol · 147
LV · 61, 63

M

Malignant glaucoma · 100, 109, 117
Manual kinetic perimetry · 58
MD · 16, 18-19, 61, 63-64, 132
Mean defect · 61
Methazolamide · 148
Metipranolol · 142, 147
Migraine · 81
Mission statement · 12
Mitomycin C · 173-174
MMC · 173-174
Monotherapy · 140-141, 145, 158
Myopia · 40, 80-81, 97, 148, 150

N

NCT · 34, 38

Neovascular Glaucoma · 95, 115, 119, 150, 168, 173
Neuroprotection · 12, 84, 133, 156
Neuroretinal Rim · 48, 51-52
Non-contact tonometry · 34
Non-Penetrating Glaucoma Surgery · 171-172
Normal-Pressure Glaucoma · 85
Numerical pattern deviation map · 60
Numerical threshold map · 60
Numerical total deviation map · 60

O

Octopus perimeter · 67
Ocular Hypertension · 16, 18-21, 79, 81-83, 88-89, 92-93, 98, 133, 164
Ocular perfusion pressure · 81
Ocular Response Analyser · 34
Ocular trauma · 13, 96
Ocuton · 34, 38
OHTS · 16, 14, 19, 81-82
Optic disc · 15-18, 48-56, 83, 85-88, 110, 140
Optic disc haemorrhage · 50, 83
Optic disc size · 53, 54
ORA · 34, 38
Osmotics · 106-108, 117, 145, 151

P

Parapapillary atrophy · 51
Parasympathomimetics · 104, 107, 150
Pascal · 34
Pediatric glaucoma · 76
Penetrating Glaucoma Surgery · 170-172
Perfusion pressure · 81, 133
Perimetry · 16, 58-59, 62-63
Persistence · 12, 159-160
Phacolytic glaucoma · 91-92, 111
Pigmentary glaucoma · 164, 172
Pilocarpine · 87, 92, 95, 103, 107, 110-111, 113, 142, 145, 150, 161, 166
Plateau iris · 103, 105, 108-110, 113, 166
Pneumatometry · 34
Posterior polymorphous dystrophy · 77, 116
Pregnancy · 153-156, 158
Preservatives · 141, 152
Primary angle-closure glaucoma · 100
Primary Angle-Closure Suspect · 101, 105
Primary Angle-Closure · 83, 100-105, 110, 115

Primary Angle-closure Glaucoma · 100-101
Primary Angle-closure Suspect · 101, 105
Primary congenital glaucoma · 75-76, 169
Primary Juvenile Glaucoma · 86
Primary Open-Angle Glaucoma · 16, 79, 83-85, 87-88, 100
Primary Open-Angle Glaucoma Suspect · 87
Primary Open-Angle Glaucomas · 79
Probability maps · 60-61, 63
Progression rate · 14-16, 132-133
Prostaglandin Analogues · 95, 141, 146, 151, 155, 165
Provocative Tests · 100
PSD · 17, 61, 64, 81
Pseudoexfoliation · 15, 17, 19, 39-40, 79-80, 82, 90
Pseudoexfoliation glaucoma · 15
Pupillary block · 42-43, 91-94, 102-103, 105-111, 113-115, 117, 161

Q

Quality of life · 12-13, 18, 75, 78, 119, 131-132, 134, 138, 140

R

Race · 80, 104
Randomized glaucoma trials · 15
Rate of Progression · 12, 14, 17, 19, 55, 63, 86, 131-136, 138
Raynaud syndrome · 81
Rebound tonometry · 35
Reliability indices · 60
Retinal detachment · 96, 150
Retinal nerve Fibre layer · 48, 50, 55-56, 79, 84, 88
Retinopathy of prematurity · 77, 118
Rim Width · 54
Ring perimetry · 59
Risk factors · 13, 79-81, 83-84, 87-89, 97-98, 104, 115-116, 132-136, 146, 173, 175
RNFL · 48, 50, 86-87, 89
RoP · 14, 131-132

S

SAP · 58-59, 63
Scanning laser polarimetry · 56
Schlemm's canal · 40, 76, 171, 175
Schwalbe's line · 40, 45, 91, 92, 106

Scleral spur · 40, 45, 150
Secondary Angle-Closure · 94, 104-105, 108, 114-115, 117
Secondary Angle-Closure With Pupillary Block · 114
Secondary Childhood Glaucoma · 76-78
Secondary Glaucomas · 90, 100, 175
Secondary Open-Angle Glaucoma · 90, 97, 99
Selective Adrenergic Agonists · 149-151
Short Wavelength Automated Perimetry · 59
Silicon oil · 96, 98, 118
SITA Fas · 58
SITA Standard · 58
Sleep apnoea · 81
SLT · 95, 164-165
Spaeth Grading System · 45
Staging · 62, 64, 101, 110
Standard Automated Perimetry · 58
Static computerised perimetry · 58
Strength of recommendation · 11
Sturge-Weber syndrome · 77, 99, 119
SWAP · 59

T

Tafluprost · 141-142, 145, 151
Target IOP · 11-12, 14, 18, 83, 86, 91, 134-138, 140, 169, 172-173
Test point patterns · 58-59
Timolol · 141-142, 145, 147, 155-157
Tonometers · 33-34, 38, 75
Tonometry · 34-36, 38, 44, 132
Tono-Pen · 35
TOP algorithm · 58
Topical Medications · 137, 142, 152, 170
Trabecular Meshwork · 40, 75, 84, 90-96, 98, 101-103, 105, 109, 115-116, 150, 163-165, 171
Trabeculectomy · 18-19, 102, 104, 106, 109, 170-172, 175-176
Trabeculotomy · 76, 78, 87-88, 116, 169, 171, 175
Transpalpebral tonometry · 35
Travoprost · 142, 146, 151
Trend analyses · 63
Triggerfish · 35
Tube Drainage Devices · 175

U

UGH syndrome · 98

Uveal effusion · 100, 118, 127
Uveitic glaucoma · 94-95

V

Van Herick grading · 47
VFI · 61, 63, 132
Viscocanalostomy · 171
Visual field indices · 60-61, 79
Visual field testing · 55-56, 58

Y

YAG laser iridotomy · 107, 114, 161
